

Original Article

Limb Gait Score of Femur Fracture Fixated by Intramedullary Pinning in Dogs

Abed, R. A¹, Nazht, H. H^{2*}, Omar, R. A³

1. Master student, Surgery and Obstetric Department, College of Veterinary Medicine, University of Baghdad, Baghdad, Iraq

2. Surgery and Obstetric Department, College of Veterinary Medicine, University of Baghdad, Baghdad, Iraq

3. Physiology, Biochemistry, and Pharmacology Department, College of Veterinary Medicine, University of Baghdad, Baghdad, Iraq

Received 1 January 2022; Accepted 16 January 2022

Corresponding Author: humam_nazhat@yahoo.com

Abstract

Animal posture, limb gait, and body weight-bearing in dogs can be evaluated by limb gait score. In this study, nine adult male dogs of local breed were used to induce a complete transverse femoral mid-shaft fracture fixed internally by intramedullary pinning under general anesthesia with the aseptic technique and followed for 60 days postoperative. The data were analyzed, including five degrees that indicate the correlation among animals' posture, limbs, and body weight tolerance per day. The results demonstrated that in grade 5, the animals completely hold the affected limb during standing position 1st-3rd day postoperative. From the 4th-10th day postoperative, in grade 4, the animals supported the body weight on the affected limb in the standing position and hold it during waking. In grade 3, from 11th-21th day postoperative, the operated animals supported body weight on the affected limb in slow waking and hold it in speed waking and running. From the 22nd-28th day postoperative, in grade 2, the animals used the limb in speed walking, from the 29th-35th day postoperative. In grade 1, the animals could use the limb in running from the 36th-2nd day postoperative. In grade 0, the animals used the limb normally in walking, running, and jumping until the end of experimental periods (60th day postoperative). The results indicated that limb gait scores in dogs can be used for the evaluation of the relationships among animals' posture, limb gait, and body-weight bearing per day during bone regeneration processing of femur fracture fixed by intramedullary pinning.

Keywords: Body weight-bearing, Femoral fracture, Intramedullary pinning, Internal fixation, Limb gait score

1. Introduction

In recent decades, numerous efforts have been made to develop and improve some methods for the promotion of fracture healing processing and bone regeneration (1-10). The intramedullary pinning is widely used for internal fracture fixation of the long bones since it is an available, easy to use, inexpensive, safe, and effective treatment approach (4, 6, 11-13). Many scales and parameters were used for post-operative surgical evaluation of limb lameness, as reported by Cook, Tomlinson (14) who indicated

different limb gait scores from grades 0-3, 0-4, and 0-5 depending on radiographic findings, histopathological changes, and clinical assessments, respectively.

Other researchers have assessed such parameters as limb gait, limb weight, and body weight bearing, as well as their association with age for lameness scores (15). The majority of studies have described different levels of lameness (0-5) during walking in dogs (16, 17). Other researchers clearly described mild weight bearing in the operated animals, secondary callus formation during the 2nd-3rd week postoperative, and

functional limb outcome at the 7th week postoperative (11, 16). The present study aimed to evaluate body posture, limb gait, and body weight bearing per day in fracture healing processing of femur in dogs during 60 days postoperative according to the newly designed limb gait scale that contains five grades of different levels.

2. Materials and Methods

2.1. Experimental Animals

A number of nine adult male local breed dogs (aged 1.5-3 years old and weighing 15-20 kg) were used in this study. They were kept in special dog cages in the Surgery Department/College of Veterinary Medicine/University of Baghdad/Iraq, for two weeks prior to operation for more adaptation as approved by the Ethics Committee of the College of Veterinary Medicine /Animal Care (4437 /P-G 30/11/2021). All animals were employed to induce complete transverse mid-shaft femur fracture, were fixed internally by intramedullary pinning, and were followed up to the end of the 60th day postoperative. The parameters which were used for evaluation were body posture, limb gait, and body weight supports postoperative according to the newly designed limb gait scale that contain five grades of different levels.

2.2. Surgical Operation

2.2.1. Anesthetic Protocol

The induction of the general anesthesia was accomplished by the injection of xylazine hydrochloride 2% (5mg/Kg. bw) via the intramuscular route, followed by intramuscular ketamine hydrochloride 10% (15mg/Kg. bw) which was administered intramuscularly after 10 min (18, 19).

2.2.2. Preparation of Animals Before the Operation

The aseptic technique was followed in the present study as mentioned by H.Nazht, Dhyaa (20). The lateral aspect of the thigh region was shaved, the area was cleaned by soap and tap water; subsequently, it was disinfected with 70% ethyl alcohol. After the induction of general anesthesia, the animals were

positioned on the lateral recumbence and the entire body, except the site of skin incision, was covered with sterile drapes (20).

2.2.3. Surgical Technique

A 10-cm skin incision was performed on the lateral aspect of the thigh at the imaginary line from the great trochanter of the femoral head to the lateral side of the patella. The subcutaneous tissue and the fascia-lata were sharply dissected, while the underlying muscles of vastus lateralis and biceps femoris were dissected bluntly. The midshaft of the femur was exposed and the periosteum was separated smoothly. A transverse complete mid-shaft fracture was performed by Gigli wire saw which protects the adjacent soft tissues by two stainless steel flat props with dropping sterile isotonic solution to prevent thermal necrosis.

The two femoral fragments were fixed internally by a suitable length and 4-5 mm diameter of the medical stainless steel rods (Figure 1A, 1B, and 1C). The muscles and fascia-lata were re-positioned using No.0 absorbable suture materials by simple continuous suture patterns and the skin was closed by No.0 non-absorbable suture materials by simple interrupted suture patterns. A dressing bandage was applied to protect the skin incision, animals were kept in special dog cages for post-operative care until the end of the experimental periods. Analgesic drug (Noralgin 50%) was intramuscularly administered immediately after the end of the surgical operation.

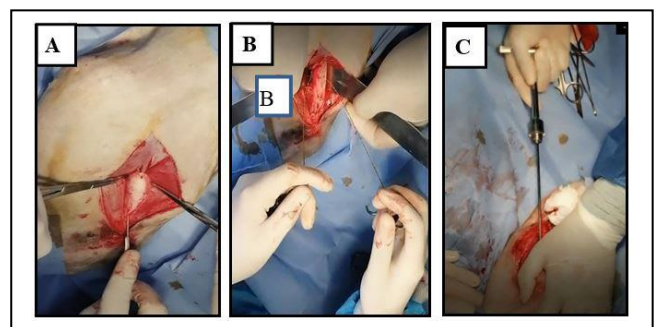


Figure 1. Steps of surgical operation illustrated: (A) Expose femur, (B) induce transverse complete mid shift femoral fracture by Gigli wire saw, (C) internal fixation by intramedullary pin

2.3. Post-Operative Examination

To prevent any abnormalities or complications, the following systemic antibiotics were administered: Penstrep-400 LA., Procaine penicillin G 100000 IU, Benzathine penicillin G 100000 IU, and Dihydrostreptomycin 200 mg (1ml /10kg bw) by the intramuscular route every 72 h for six days postoperative. Daily clinical observations were made for animals' posture, limb gait, and normal body weight bearing. Follow-up examinations were performed every day.

2.4. Statistical Analysis

The mean and standard error were calculated on the basis of data and analysis of variance (ANOVA) was using Complete Randomized Design (CRD) Snedecor and Cochran (1994).

3. Results

The results of limb walking and animal weight tolerance were evaluated on a daily basis until the end of the 60th day postoperative. The data were analyzed by a newly designed limb gait scale that contains five different grades which demonstrate the correlation of animals' posture, limb gait, and body-weight bearing per day. The first 24 hours postoperative, the animals refused to move and lay or remained in a standing position, from the 1st-3rd day postoperative, in grade 5, animals could stand all the time but hold the affected limb from the ground and cannot bear the body weight. The 4th-10th day postoperative, in grade 4, the operated animals could bear the weight on the affected limb in standing position but hold the limb when walking. The 11th-21th day postoperative, in grade 3, the animals could bear the weight when walking and hold it in speed waking and running, from the 22nd-28th day postoperative, in grade 2, the animals used the limb in speed waking and start running gradually, from the 29th-35th day postoperative, in grade 1m the animals used the affected limb in running normally, from 36th-42nd day. Finally, in grade 0, the animals used the limb in jumping and persist normally in gait without signs of

lameness and could hold the body weight on the affected limb until the end of the 60th day postoperative (Table 1 and Figure 2).

Table 1. Limb gait score of operated dogs, signifying different score grades per day of the body posture, limb gait, and body weight-bearing in femur fracture fixed by intramedullary pinning

Degree	Description
0	Using the limb normally in jumping, walking and completely supporting the body weight until the end of experimental periods
1	Body weight-bearing in running and holding it in jumping
2	Supporting body weight in speed walking and holding it in running
3	Supporting body weight in slow walking and holding the limb in speed walking
4	Supporting body weight in standing position and holding the limb in walking
5	No limb use, holding the limb completely without body weight-bearing

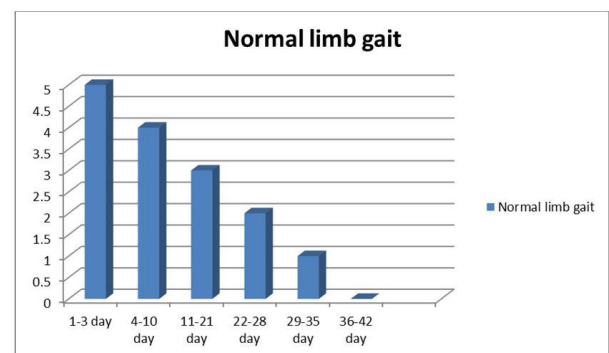


Figure 2. Limb gait score during the study period, signifying the correlation of time/day with animals' posture, limb gait, and body weight bearing in dogs of femur fracture fixed by intramedullary pinning

4. Discussion

The limb gait score which was designed in the present study consists of five grades of different degrees (0-5) which depend on the correlation of animals' posture, limb gait, and body weight support during the experimental periods until the end of the 60th day postoperative. It was revealed to be similar to the lameness scores based on different lameness degrees as mentioned by Arias, Blanco (21).

Based on the results of the present study, from the end of the 11th-21th day postoperative, the animals could bear body weight in a standing position and slow walking in grade 3. Moreover, the operated animals used the affected limb normally in speed walking and jumping in grade 0 from 36th-42nd day postoperative. The aforementioned results are consistent with those obtained by other researchers who reported that mild weight-bearing and secondary callus formation were noticed during the 2nd-3rd week postoperative, and the functional limb outcome was observed at the 7th week postoperative (16, 21).

In the current study, animals refused to walk and lay all time within 24 h postoperative, and from the 1st-3rd day postoperative, the animals could stand but hold the affected limb from the ground and could not bear body weight. From the 4th- 10th day postoperative, the operated animals gradually could bear weight in a standing position and hold limbs in walking. From the 11th- 21th day postoperative, the animals could bear bodyweight at walking and hold the limb in speed walking or running. From the 22nd -28th day, the animals could use the limb in speed walking, and from the 29th- 35th day postoperative, the dogs could use the affected limb in running. From the 36th-42nd day postoperative, the animals normally used the limb in jumping until the end of the 60th day postoperative. All the operated dogs used the affected limb normally with no signs of lameness. These findings were in accordance with those reported by Nečas and Dvořák (22), (23). Moreover, they were in partial agreement with the results of a study by Cook, Tomlinson (14) who revealed that dogs started to bear weight on the operated limb from the 7th-10th day postoperative and walked normally without any signs of pain 15-20 days after the operation. On the other hand, the results of some studies were not consistent with the aforementioned findings and indicated that the experimental dogs started weight-bearing from the 2nd day and continued until the 60th day postoperative (24).

In the same context, was pointed out Kranthi (25) that after the application of platelet-rich plasma (PRP).

Complete weight bearing improves gradual improvement of normal weight-bearing postoperative. These observations confirmed the results of the present study which demonstrated a gradual improvement in animals' posture, limb gait, and body weight-bearing during 60 days postoperative.

The results of the current study were in accordance with those indicated by Impellizeri, Tetrick (15) who pointed to the relationship of the hind limb lameness with body weight-bearing and obesity in dogs with hip joint osteoarthritis. They reported that the lameness score of 5 and 4 showed complete lameness, scores of 3 and 2 signified moderate and mild lameness, a score of 1 referred to difficult detected lameness, and a score of 0 illustrated that animals were clinically sound. The results of this study illustrated that during bone remodeling in femur fracture of dogs by intra-medullary pinning fixation, body weight-bearing gait points and lameness score per day can be used.

Authors' Contribution

Study concept and design: R. A. A.

Acquisition of data: R. A. A.

Analysis and interpretation of data: H. H. N.

Drafting of the manuscript: H. H. N.

Critical revision of the manuscript for important intellectual content: H. H. N.

Statistical analysis: R. A. O.

Administrative, technical, and material support: H. H. N.

Ethics

All the procedures were approved by the Ethics Committee of the College of Veterinary Medicine /Animal Care (4437 /P-G 30/11/2021).

Conflict of Interest

The authors declare that they have no conflict of interest.

References

1. Sinan A, Eesa MJ, Omar RA. Histopathological study of the influence of platelet rich-plasma and low level

- laser therapy on healing of experimentally fractured proximal sesamoid bone in equine. *Iraq J Vet Med.* 2017;41(1):160-8.
2. Thanoon MG, Eesa MJ, Alkenanny ER. Histopathological evaluation of the platelets rich fibrin and bone marrow on healing of experimental induced distal radial fracture in local dogs. *Iraq J Vet Med.* 2022;43(1):11-20.
 3. Nazhat HH, Jawad NMA, College TVM. Effects of prostaglandin E2 on bone resorption in the remodeling phase of the femoral bone fractures in rabbits: Baghdad University; 2000.
 4. Nazht H, KR M. Radiological Evaluation of Fractures Healing Processing Fixed by Food Grade Stainless Steel Rods in Rabbits. *Open Access J Vet Sci Res.* 2019;4.
 5. Nazht H, Omar R, Aldahhan M, Ahmed H. Effect of Low Level Laser Therapy on the Sheep Ribs Xeno Graft in the Treatment of Rabbits Long Bone Fractures. 2018. 100-6 p.
 6. Nazht HH, Al Mahmoud A, MH, Omar R, A, ManuaZyad M, DyabZied H, Khaleefa R, Khedr, et al. Advantages and Disadvantages of using Food Grade Stainless Steel Rods for Internal Fixation of Femoral Transverse Fractures in Rabbits .*Open Access J Vet Sci Res.* 2020;5(2):1-7.
 7. Nazht HH, Al-khazrajii SA, Omar RA. Effect of low level laser therapy on the chronic defect of tibial bones in rabbits. *Basrah J Vet Res.* 2018;17(3).
 8. Nazht HH, Almahmoud AM, Abood DA. Using Xeno- Bovine Bony Implantation as Space Filler in Femoral Defect in Rabbits. *Global Proceedings Repository American Research Foundation.* 2020.
 9. Nazht HH, Faleh IB, Hamed NA. Histopathological study of the distal third fractures of radius in dogs, treated with LLLT. *Basrah J Vet Res.* 2016;15(1).
 10. Omar RA, Saleh SI. Study of low power Laser effect on the healing of tibial fracture treated by intramedullary pin in rabbits. *Iraq J Vet Med.* 2003;27(1):99-108.
 11. Abd El Raouf M, Mekkawy NHM, AbdEl-Aal AM. Femur fractures and treatment options in 20 dogs admitted to our clinic from January 2013 to December 2015. *Iraq J Vet Sci.* 2017;31(2):117-22.
 12. Nazht HH. Using Food Grade Stainless Steel Rods for Internal Fixation of Transverse Fractures in Rabbits. *Open Access J Vet Sci Res.* 2019;4(3).
 13. Tercanlioglu H, Sarierler M. Femur fractures and treatment options in dogs which brought our clinics. *Lucrăristiinlificemedicinăveterinară.* 2009;13(2):98-101.
 14. Cook JL, Tomlinson JL, Reed AL. Fluoroscopically guided closed reduction and internal fixation of fractures of the lateral portion of the humeral condyle: prospective clinical study of the technique and results in ten dogs. *Vet Surg.* 1999;28(5):315-21.
 15. Impellizeri JA, Tetrick MA, Muir P. Effect of weight reduction on clinical signs of lameness in dogs with hip osteoarthritis. *J Am Vet Med Assoc.* 2000;216(7):1089-91.
 16. Das BC, Roy CK, Biswas S, Dey T, Biswas PK, Sutradhar BC. Retrograde intramedullary pinning for femur fracture management in a Labrador dog-a case report. *Bangladesh J Vet Med.* 2020;8(1).
 17. Monk ML, Preston CA, McGowan CM. Effects of early intensive postoperative physiotherapy on limb function after tibial plateau leveling osteotomy in dogs with deficiency of the cranial cruciate ligament. *Am J Vet Res.* 2006;67(3):529-36.
 18. Eesa M, Omar RA, Nazht H, Al-Badrawi T. Evaluation of general anaesthesia by using Propionylpromazine, Xylazine and Ketamine in rabbits. *Iraq J Vet Med.* 2012;34(1):208-17.
 19. Yamamoto K, Honda M, Yamamoto T, Nakamura T. Healing process after total cricoideotomy and laryngotracheal reconstruction: endoscopic and histologic evaluation in a canine model. *J Thorac Cardiovasc Surg.* 2013;145(3):847-53.
 20. Nazht H, Abood D, Sabeel O. Evaluation of Pyloroplasty repair by Single layer Simple Interrupted Extra Mucosal technique in Dogs. *Iraq J Vet Med.* 2017;41(1):38-42.
 21. Arias SA, Blanco JRT, Doretto JV, Vieira GLT, Oliveira HP, Rezende CMF, 65, . Modified cementless total coxofemoral prosthesis: development, implantation and clinical evaluation. *Arquivo Brasileiro de Medicina Veterinária e Zootecnia.* 2013;65:1660-72.
 22. Nečas A, Dvořák M. Surgical treatment of a saggital intraarticular femoral head fracture with coxofemoral dislocation in two mature dogs. *ActaVeterinaria Brno.* 2003;72(2): 261-5.
 23. Yuvaraj H, Dilipkumar D, Shivaprakash B, Usturge S. Comparative evaluation of DCP with PMMA plate for femur and radius fracture in dogs. *Indian Vet J.* 2007;28(1):1-5.

24. Das BC. Surgical management of unstable diaphysealtibial fracture with conventional dynamic compression plating (dcp) in dogs. *J Appl Life Sci Int.* 2012;1(2).
25. Kranthi B. Use of locking compression plate system and platelet rich plasma in the treatment of long bone fractures in dogs: Narsimha Rao Telangana Veterinary University; 2018.