

**Original Article**

## **A comparison of virulence of intraperitoneal infection of *Burkholderia mallei* strains in guinea-pigs**

**Eslampanah<sup>\*1</sup>, M., Mosavari<sup>2</sup>, N., Hablolvarid<sup>1</sup>, M.H.**

1. Department of Pathology, Razi Vaccine and Serum Research Institute, Karaj, Iran  
2. Department of PPD Production, Razi Vaccine and Serum Research Institute, Karaj, Iran

Received 31 August 2014; accepted 14 December 2014  
Author for correspondence. Email: m.islampanah@rvsri.ac.ir

---

### **ABSTRACT**

Male guinea pigs show high susceptibility to *Burkholderia mallei* and have been used as animal models in glanders studies. The purpose of our study was to elucidate glanders comparative pathogenesis in guinea pigs. We present here the histological changes and bacterial isolation that develop over time in guinea pigs inoculated intraperitoneally (IP) with two strain of *B. mallei*. Ten male guinea pigs were inoculated intraperitoneally with either the standard strain of *Burkholderia mallei* or *B. mallei* strain from Siberian tiger at the Tehran zoo individually, then euthanized at multiple time points post inoculation. Histopathologic changes were similar in both groups and consisted of pyogranulomatous inflammation. In the standard strain study guinea pigs, changes were first seen at 48 hours in liver and heart then in spleen, lung, and kidney at day 3. These changes generally reached maximal incidence and severity by day 3 but decreased by comparison in all tissues except the liver, lung and kidney. Changes were first seen in Siberian tiger strain study guinea pigs also at 48 hours in lung, liver and spleen. At day 3, changes were present in liver, spleen and mediastinal lymph nodes. These changes were maximal at day 4 and 5. In contrast there are differences in incidence and severity between the two strain study guinea pigs. Our findings based on histopathological study indicate that Siberian tiger strain has more severity in gross and necropsy examination but in pathologic lesion was qualitatively similar generally. Additionally, by bacterial isolation, we confirmed the presence of *B. mallei*.

**Keywords:** *Burkholderia mallei*, Siberian tiger strain, standard strain, pathologic lesion

---

### **INTRODUCTION**

Glanders is a zoonotic disease caused by a gram-negative, aerobic, non-spore-forming bacillus; *Burkholderia mallei* (Wittig *et al* 2006, Popov *et al* 1995). This organism is an obligate mammalian pathogen (Sanford 1990) with one-hoofed helping as the reservoir for infection (Nicoletti, 2007, Acha & Szyfres 1989, Dungworth 1993). Although glanders is

yet endemic in areas of Asia, the Middle East, Northern Africa, and various Mediterranean regions (Wernery *et al* 2005, Benenson 1995, Kovalev 1971) the Western Hemisphere is currently free of the disease (Darling & Woods 2004, Rotz *et al* 2002, Benenson 1995). Natural infections occur principally in horses, donkeys, and mules (Miller *et al* 1948) but most mammals have some susceptible (Howe 1949). Natural disease is sometimes seen in goats, sheep, dogs, and cats

(Dungworth 1993, Parker 1990) and it has been seldom reported in carnivores that have eaten infected equine meat (Dungworth 1993, Parker 1990). Cattle, pigs (Dungworth 1993) and birds (Howe 1949) are very resistant to natural disease (OIE 2008). Experimentally, domesticated animals mostly can be infected, excepting cattle, pigs, and rats (Howe 1949). Guinea pigs and hamsters are the laboratory rodents most susceptible to glanders infection (Howe 1949). There appears to be a variance in susceptibility among individual guinea pigs to infection with *B. mallei* (Miller et al 1948). When a global outbreak of glanders in horses was high, the incidence of the disease was rare in humans (Parker 1990). There is no evidence in humans of epidemics glanders (Hornick 1982). However, human susceptibility to *B. mallei* has not been studied in detail; it is proved that this organism is highly infectious in laboratory settings (Popov et al 2000, Parker 1990, Sanford 1990). Today it is recognized that glanders bacillus is one of the few dangerous organisms in the field of laboratory work (Srinivasan et al 2001, Parker 1990, Redfean & Palleroni 1975). To study glanders pathogenesis in an animal model with resistance/susceptibility similar to human beings, we chose laboratory guinea pig. Glanders disease presents several interesting features. Virulence is the result of factors which include the properties of the infecting agent and the response of the host to infection by a given route. The outcome, whether it results in disease, death or survival, is due to a delicate balance between these factors. To explain glanders pathogenesis in guinea pigs, we performed a time-course study of histopathologic, bacteriological and molecular findings in Pirbright guinea pigs inoculated IP with either a standard strain (Razi Type Culture Collection RTCC: 2375) or Siberian tiger strain of the organism.

## MATERIALS AND METHODS

**Inoculum.** The standard (Razi Type Culture Collection RTCC: 2375) strain of *B. mallei* was used in producing mallein in tuberculosis department of Razi

Vaccine and Serum Research Institute and isolate *B. mallei* strain from Siberian tiger at the Tehran zoo. These strains were cultrate onto the 3% glycerol Tryptic soy agar (TSA) medium (Difco & BBL, NJ USA) and incubated at 37 °C in aerobic condition for 48h. These samples were serially passages through three guinea pigs. The confluent (48h) growth cultures of two *B. mallei* were suspended in PBS salt solution to achieve a challenge dose of  $10^7$  the colony-forming units per milliliter (CFU/ml) and the optical density were used to determine the CFU/ml.

**Bacterial isolation.** Bacterial loads per milliliter of blood and per gram of spleen, liver, lung, testis, kidney, heart, bone marrow and brain were inoculated directly onto the 3% glycerol Tryptic soy agar (TSA), Tryptic soy broth (TSB) and blood-agar (Difco & BBL, NJ USA) and incubated at 37 °C in aerobic condition for 48h. The colonies (small, round, convex, translucent, and yellowish) suspected to be *B. mallei* were identified by gram staining, oxidase test, motility tests, TSI, gelatin liquefaction, fermentation of carbohydrates, nitrate reduction and growth at 42 °C. Identification was confirmed by biochemical profiles on API BBL tests (Difco & BBL, NJ USA). The isolates were stored at -70 °C in tryptic soy broth (Difco & BBL, NJ USA) containing 20% glycerol.

**Animals.** Ten male guinea pigs, weighing 350 and 400 g, were administered 1 ml of the inoculum in the left lower abdominal quadrant intraperitoneally (IP) by using a 25-gauge needle. Five age- and sex-matched controls were injected with 1 ml Phosphate-buffered saline (PBS) alone. All animals were observed at least twice daily. Each guinea pig located at separate cage in one isolator.

**Necropsy.** Three guinea pigs (consist of two infected and one non infected control) were euthanized on 2 day post inoculation (PI). Beginning on day 3(72 hours PI), two infected and one non infected control animals were euthanized with chloroform. On day 4, one animal was dead. This procedure was repeated daily through day 5 and 6. Three animals at each time point encounter routine necropsy, and tissues from dissected animals

were immersed in 10% formalin saline. Gross findings from each animal were recorded. Skulls and hind legs were decalcified in formic acid.


**Histopathology.** For the histopathological analysis, tissue from each guinea pig were collected and fixed in 10% neutral-buffered formaldehyde. The tissues were routinely processed and embedded in paraffin wax. They were sectioned at 5–6  $\mu\text{m}$  and stained with Hematoxylin and Eosin (H&E) for light microscopy. Replicate sections from spleen, liver, and lung were Giemsa-stained to demonstrate bacteria.

## RESULTS

### Bacterial isolation & culture in animal's experiments.

Specimens from different organs of two infected guinea-pigs and a negative control guinea pig including: testis, spleen, liver and lung were inoculated onto the 3% glycerol TSA and TSB (Difco & BBL, NJ USA) tubes at 35–37°C for 48h. The morphology of cultural results such as: small, round, convex, translucent, and yellowish colonies indicated that the isolate was *B. mallei*. Subsequently, *Burkholderia mallei* was isolated and identified from different tissue of the experimentally infected.


**The standard strain study guinea pig.** For standard strain study guinea pig, on days 2, 3, 4, and 5 PI, *B. mallei* was cultured from the blood, but after day 5, blood cultures were negative. *B. mallei* was cultured from liver sample at day 2, 3, 5 but was not cultured from the liver of guinea pig at days 4 and 9. Glanders bacilli were cultured from spleen on days 3, 4 and also at day 5 except at 9 day. The lung was culture positive in guinea pig only at 5 day (Figure 1).



**Figure 1.** The standard strain study guinea pig, lung: small, round, convex, translucent, and yellowish colonies indicated that the isolate was *B. mallei*.

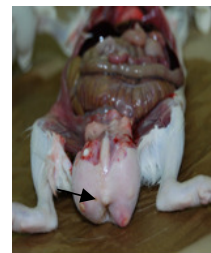At days 4, 5 PI, *B. mallei* was cultured from the kidney sample animal. Other tissues were culture negative in standard strain study guinea pig.

**The Siberian tiger study guinea pig.** For Siberian tiger strain study guinea pig, *B. mallei* was cultured from few sampled tissues. Negative culture in the lung of guinea pig includes 4, 5 and 9 days PI. Bacilli were cultured from kidney on days 2, 3 and 5 PI (Figure 2). Grossly bacterial colonies observed in cultures medium in the Siberian tiger strain less than standard strain studies.



**Figure 2.** The Siberian tiger study guinea pig, kidney: small, round, convex, translucent, and yellowish colonies indicated that the isolate was *B. mallei*.

**Clinical observations.** At day 2 PI in both strain study guinea pigs was appeared clinically normal and active. By day 3, Siberian tiger strain study guinea pig was dead. Clinical signs of infection were first observed at day 4 guinea pigs in both groups were severely lethargic, moved only with great difficulty and ataxic when stimulated to move which increased in severity through day 5 PI. By day 9, in both strain study groups the testicles were painful by the end of the ninth day, and scrotum became moderately swollen and edematous; orchitis (the Strauss reaction) were seen (Figure 3).



**Figure 3.** The Siberian tiger study guinea pig, testicles, orchitis (the Strauss reaction) consisted of pyogranulomatous inflammation.

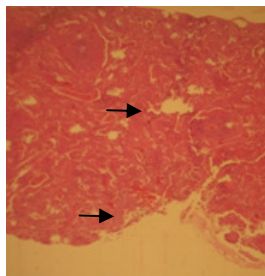
The Severities of Clinical observations in standard strain were less than Siberian tiger strain at which time all animals. All control guinea pigs were clinically normal throughout the study.

**Gross pathologic findings.** In standard strain study guinea pig, the first gross pathologic changes were inflammation of liver, seen at day 2. By day 9, lung was appearing pneumonic in guinea pig. In Siberian tiger study guinea pig at day 4, subscapular lymphadenitis was present in guinea pig. Also at day 4, lung was appearing pneumonic in guinea pig. At day 9 the left kidney of guinea pig was seen hyperemic and hypertrophic. No significant change occurred in control guinea pig during the time course of the study.

**Histopathologic findings.** The incidence of glanders-induced histopathologic changes in standard strain study and Siberian tiger study guinea pigs at the various time points is summarized in Tables 1 and 2, respectively. Generally, the most prevalent change in affected tissues in both groups consisted of infiltration of polymorphonuclear (PMN) leukocytes in multiple tissues in 48 hours PI of infection. This infiltrate was variably organized into discrete pyogranulomas.

#### The standard strain study guinea pig.

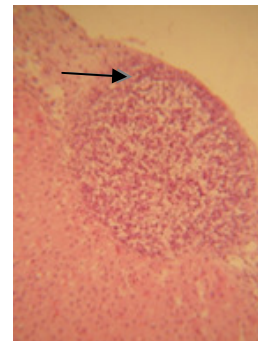
1. *Spleen:* Changes at first were seen at day 2 PI and included of mild depletion in the marginal zone of the red and white pulp and a moderate depletion in the white pulp. At day 3, hyperemia with hemorrhage in parenchyma and red pulp and foci of necrosis also moderate lymphoid depletion of the white pulp were seen (Figure 4).



**Figure 4.** Spleen; Pirbright guinea pig, day 3 after IP inoculation with *B. mallei*. Moderate lymphoid depletion of the white pulp and subcapsular hemorrhage (arrow) were seen. (H&E×400).

The severity of this lesion was most scattered hemorrhage and moderate edema in parenchyma and red pulp also mild depletion in the white pulp at day 4. Several and multifocal hemorrhage of the red pulp and edema with mild depletion in parenchyma and red pulp was present in the spleen of guinea pig at days 5. At the end of study (day 9) lesions limited to foci of hyperemia and hemorrhage in the red and white pulp. Intracellular bacilli were seen in splenic sections at 3, 4 and 5 days PI.

2. *Liver:* Liver changes at day 2 consisted of a wide hyperemia in hepatic parenchyma, periportal and centrilobular edema with fatty change also intracellular hemorrhage and marginal necrosis were seen. Miliary distribution of a pyogranulomatous inflammation with capsulitis and foci of coagulative necrosis, intracellular and centrilobular hemorrhage, hydropic degeneration at day 3 were observed (Figure 5). These lesions were seen at day 4 PI except foci of pyogranulomatous but miliary of pyogranulomatous were present at day 5 PI. Lesions including scattered hemorrhage and hyperemia with small foci of necrosis were present at 9 day PI.

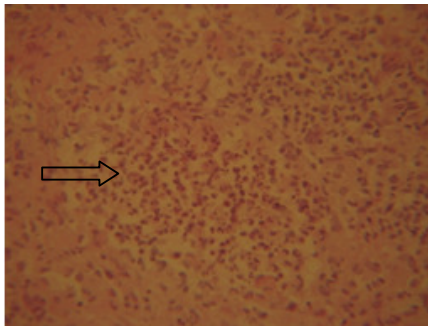


**Figure 5.** Liver; Pirbright guinea pig, day 3 after IP inoculation with *B. mallei*. Note focus of pyogranulomatous hepatitis (arrow) adjacent to a capsule (H&E×400).

3. *Mediastinal lymph node:* Changes in the mediastinal lymph nodes at 48 hours consisted of scattered hemorrhage in parenchyma. At day 3, the character of moderate lymphoid depletion was seen in the mediastinal lymph node of guinea pig. The severity of the lymphoid depletion reduced at the later time points.

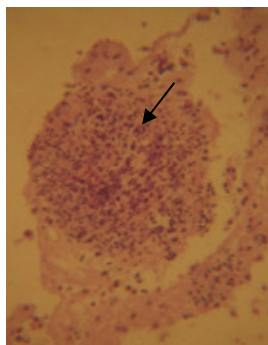
4. *Mesenteric/other lymph nodes*: There were no glanders-related lesions found in these lymph nodes.

5. *Lung*: Lung changes at day 2 consisted of hemorrhage in parenchyma, peribronchial edema with hyperemia were seen. On day 3 and 4, glanders-related changes in the lungs consisted of multifocal, interstitial bronchopneumonia (Figure 6) also were seen. Interstitial bronchopneumonia was continuing in day 9 guinea pig.



**Figure 6.** Lung; Pirbright guinea pig, day 3 after IP inoculation with *B. mallei*. Note the relatively demarcation between the pyogranuloma and more normal surrounding tissue. Although some leukocyte necrosis is evident here (H&E×400).

6. *Male reproductive*: Moderate involvement of the testis, epididymis generally consisted of a pyogranulomatous inflammatory infiltrate-epididymis were seen better at days 3 and 5 (Figure 7).



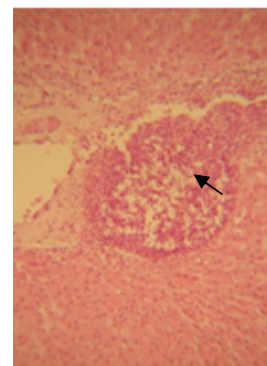
**Figure 7.** Male reproductive; Pirbright guinea pig, day 3 after IP inoculation with *B. mallei*. pyogranulomatous inflammatory infiltrate-epididymis (H&E×400).

### The Siberian tiger study guinea pig.

1. *Spleen*: Splenic lesions were first seen at 48 hours and consisted of hyperemia and hemorrhage in parenchyma with mild depletion in the red pulp also

edema and thrombosis. Moderate depletion of the red and white pulp and hemorrhage in white pulp also scattered edema in splenic parenchyma at day 3 PI were present. At day 4, Moderate depletion of the white pulp and a little more in red pulp also hemorrhage in parenchyma and red pulp likewise edema in the red pulp. Mild depletion in the white pulp also hyperemia with scattered hemorrhage in the red pulp at day 5 PI was observed. At day 9 lesions limited to foci of hyperemia and hemorrhage in the red and white pulp also hyperemia and scattered hemorrhage in parenchyma of spleen were seen.

2. *Liver*: Liver changes were first seen at day 2 and were similar to those seen in Siberian tiger study guinea pig, peaked in severity at day 4 and were not changed with time thereafter. Multifocal zones of hepatocellular coagulative necrosis were a very frequent finding at all time points. Fatty changes and intracellular hemorrhages, occasionally evident at the early time points, were observed in guinea pigs at days 2 and 3. At day 4, guinea pig had thrombus in hepatic veins. Military focal granulomatous portal hepatitis was seen in guinea pig at day 4 (Figure 8).



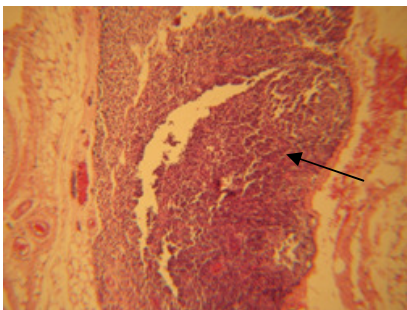
**Figure 8.** Liver: Pirbright guinea pig, day 4 after IP inoculation with *B. mallei*. Note Military focal granulomatous portal hepatitis was seen in guinea pig at day 4 (arrow). H&E×400.

4. *Mesenteric/other lymph nodes*: Mild lymphoid depletion was an infrequent finding in all guinea pigs from day 1 on.

5. *Lung*: On day 2, changes in the lungs consisted of wide hyperemia in parenchyma and multiple

lymphocytic foci. Mild pneumonia also hyperemia and edema on day 3 were seen. On day 4 lymphocytic foci and interstitial bronchopneumonia with hepatization appearance and on day 5 with fewer lesions were present. Bacterial interstitial bronchopneumonia but generally associated with hemorrhage and vasculitis was present in day 9 guinea pig.

6. *Male reproductive*: Involvement of the testis, epididymis, and accessory sexual organs generally consisted of a pyogranulomatous inflammatory infiltrate within the tunica vaginalis and only rarely involved the parenchyma of the tissue. The incidence was highest in accessory organ/epididymis at days 3 and 5.



**Figure 9.** Mediastinal lymph node: Pirbright guinea pig, day 2 after IP inoculation with *B. mallei*. Pyogranulomatous infiltrate in the paracortex-Necrotizing pyogranulomatous mediastinitis. H&E×400.

## DISCUSSION

The pathological changes aroused in guinea pig inoculated IP with both standard strain and Siberian tiger strain of *B. mallei*. The main gross lesion was seen in the both study groups orchitis. The main histopathological lesions including pyogranulomatous inflammatory cell infiltrates in some organs. In both standard strain and Siberian tiger strain group studies, bacterial cultures exposed glanders bacilli in the blood, lung, liver, and spleen at some times post inoculation in guinea pigs also in mice in other surveys by 6 hours PI (Gilad 2007, Marco 1992, Ferster 1982). The blood culture was positive in standard strain study guinea pig within day 2-3-4 and through day 5 in guinea pig. It is probably that glanders bacilli injected IP were passed to intrathoracic lymph nodes through of

transdiaphragmatic lymphatic (Harley et al 1998, Marco 1992). Bacilli entered from intrathoracic lymph nodes to the venous blood through the thoracic duct.

**Table 2.** Histopathic changes in guinea pigs periodically euthanized post intraperitoneal inoculation with  $10^7$  CFU of *B. mallei* strain from Siberian tiger.

Day post inoculation	Tissue			
	Spleen	Liver	Kidney	Lung
2	-	+	+	++
3	+	+	-	+
4	-	++	+	++
5	-	+	+	+
9	+	+	+	+

The positive blood cultures ended off in our guinea pig on day 9 may indicate the termination of devolution of bacteria from the peritoneal cavity to the blood. Besides likely those bacteria initially poured in the blood from the intrathoracic lymph nodes planted in the infection. Anyway, being a few amounts of glanders bacilli observed in histopathological sections of these lymph nodes indicates opposing this process. In Siberian tiger study guinea pig, we were surprised at the inconsistent isolation of bacteria from blood, lung, and liver. For example, no bacteria were detectable in blood, spleen and liver of any day PI guinea pig, but cultures were once again positive in kidney of guinea pig on days 2, 3 and 5. In this study, the kidney of guinea pig was the main tissue for glanders infection but in mice the spleen was goal organ and Spleens were equally infected during 6 hours PI. Chronic glanders infection has not yet studied, although *B. mallei* cultured from vaccine survivors (both mice and hamsters) at 60 days PI (DeShazer et al 2001). Therefore *B. mallei* may have tropism for latency, that's intimately related to *B.pseudomallei*, the agent of melioidosis (Harley 2004). The diversities in the manner and quantum of histopathologic lesion were seen in mice with sublethal infections were mostly same as our study in standard strain and Siberian tiger strain sequentially (Stundick 2013b). For example, in the spleen the feature, spread, and the extremity of

lesion were not similar in guinea pig from both study groups unlike in mice (Stundick 2013b). The liver lesion seen in all sublethal study mice as well as Siberian tiger strain guinea pig in our study and at the early time points in lethal study mice was pyogranulomatous inflammation but in standard strain guinea pig were seen at all times except on day 4 (DeShazer *et al* 2001). Noteworthy, the lesions of the liver in both groups did not reduce over time, as same as tendency in other tissues in mice studies (DeShazer *et al* 2001). Other studies in mice euthanized about 40 days PI showed liver lesions commensurable in incidence and severity of the ones reported (DeShazer *et al* 2001). Miliary pyogranulomas were attended in time with acutely limited, multifocal of hepatocellular degeneration and necrosis that supposed due to an ischemic change. The results of other studies indicated that RE rich tissues are particularly sensitive to focus on *B. mallei* and the onset of lesions. (DeShazer *et al* 2001, Popov 1995, Frester 1982). Based on our findings in this study, confirms the importance of RE tissues, especially in a species resistant to glands like the mouse. In the guinea pig, organs with inexpressive RE tissue were only sporadically affected mediastinal lymph node lesions in Siberian tiger strain study guinea pig were slightly more intense and wide than in standard strain study guinea pig. Nevertheless, the affect of mediastinal lymph nodes and the spleen was accordantly more in standard strain study guinea pig. This was probably through the higher infectious dose, which resulted in localization of glanders bacilli in the RE-rich tissues. The severity and occurrence of lesions in mediastinal lymph nodes and spleen reduced in standard strain study guinea pig euthanized at the end of the study. This study in guinea pig has emphasized some significant similarities and differences between glanders infection in other species such as: mice and hamsters. The pyogranulomatous inflammatory response generated by the glanders bacillus in other species and has a tendency for infection in RE-rich tissues (such as spleen, and liver) (Stundick 2013a, Stundick 2013b). In both groups of guinea pigs, livers

have vascular thrombosis often due to areas of hepatocellular degeneration and necrosis as well as mice in subacute study. In hamsters, evidence of impaired vascular perfusion, especially in the end stages of the glanders disease process has reported (Stundick 2013a). Between mice and hamsters included the general limitation of glanders in mice to the RE-rich tissues, whereas in guinea pig, it is widely disseminated as well as hamsters (Stundick 2013a, Stundick 2013b). The diagnostic histopathologic change in guinea pig and mice included pyogranulomatous inflammation, which usually lacked separate formation. In mice necrosis was never extensive and hemorrhage was rarely present. Even so, infrequently pyogranulomas with central necrosis and abundance of leukocytic karyorrhectic debris were typical, and the inflammation was often accompanied by hemorrhage in hamsters. In hamsters, septic thrombi observed frequently in many tissues and postulated that each served as the nidus of areas of inflammation in hamsters (Stundick 2013a, Stundick 2013b). However, in mice and guinea pig, septic thrombi were never observed (Stundick 2013b). There is low information about pathologic findings in human beings infected with the glanders bacillus. The organism tropism to focus at the site of entry and cause to formation of nodules that eventually ulcerate, resulting in lymphangitis and lymphadenopathies then the organisms are spread systemically, many tissues can be seeded. These tissues include skin (Acha 1989), skeletal muscle, bone, joints, less commonly brain/meanings and rarely nasal or ocular (Hornick 1982, Sanford 1991). The lungs, liver, and spleen are often affected (Acha 1989). Histologically the lesions are described as being granulomatous (Kovalev 1971) and occasionally as being abscesses, (Kazantseva 1970) (Sanford 1991) indicating a significant component of PMN leukocytes and necrosis within the lesion. The character of the inflammatory cell infiltrate is the same in guinea pig and mice as in human beings with the exception of intralesional necrosis. As in people, the lesions are often seen in liver and spleen as well as guinea pigs. But a major difference is that, in mice,

lung lesions were never present. Involvement of lung is common in many animal species in natural infections with *B. mallei*. (Sanford 1991, Acha 1989). Primary findings show there is a significant decrease in virulence after laboratory passage, indicating that capsule is an important factor for *B. mallei*, as it is for other pathogenic bacteria (Mims 1995). Many authors report finding L-forms (cell-wall deficient) of *B. mallei* within RE cells in infection of white mice and white rats. (Dyadishchev 1997). Hypothesize that persistence of bacteria in these cells resulted in the proliferation of RE cells and ultimately granuloma formation (Ferster & Kurilov 1982). Subacute portal inflammatory cell infiltrates were often present but never contained giant cells. Base on their study, glanders infection of both mice and hamsters which compared, Ferster and Kurilov suggested that major differences exist in glanders pathogenesis between the susceptible and non susceptible host (Ferster & Kurilov 1982). Comparing our findings in guinea pig study with other study in hamsters and mice, conclude that glanders pathogenesis is similar in these two hosts following IP inoculation. Although the severity and distribution of lesions differ between these animals, the overall character of the lesions is essentially the same. It has been suggested by others that many bacteria, when exposed to a hostile environment in their host, can change into a cell-wall-deficient form that can survive/persist in a latent state and cause chronic disease. Regardless, unable to identify any L-form glanders bacteria in the tissues of mice. We previously reviewed pathologic findings in glanders infection from a variety of laboratory animals as reported by other authors. Of these reports, only Ferster and Kurilov presented pathologic data in mice (Balb/c) that were injected subcutaneously with various doses of both virulent and avirulent (for mice) strains of glanders bacilli (Ferster & Kurilov 1982). In general, the histopathologic changes they noted in the spleens and extrathoracic lymph nodes are similar to those in sublethal and lethal study mice. They described pneumonic foci (presumably pyogranulomatous) in the lungs of their mice at day 5 PI and we saw these

changes particularly days 2, 3 and 4 PI in both groups of guinea pigs. They also described an abundance of giant cells in the peribronchiolar connective tissue of their mice. In contrast, we found no glanders-related changes in the lungs of any guinea pigs and no multinucleated giant cells in any tissues from our guinea pigs. Ferster and Kurilov also described liver lesions consisting of perivascular lymphohistiocytic infiltrates and multifocal Kupffer cell proliferations, which contained multinucleated giant cells. In contrast, the predominant lesions in the livers of mice were miliary pyogranulomas and multiple foci of hepatocellular ischemic change as well as our guinea pigs. The incidence of infection in human beings has been low, indicating they have a mild resistance to infection by *B. mallei*. Due to the high infectivity of human beings involved in laboratory work with the glanders bacillus, (Parker 1990, Sanford 1990) believed this organism has potential for emerging as a human pathogen. In light of the resistance of the organism to many antibiotics and past failures in the development of vaccines against *B. mallei*, continued study is needed on appropriate animal models. Hamsters and guinea pigs are believed to be the most uniformly infected and highly susceptible rodents for glanders infection (Miller *et al* 1948). At the time of earlier glanders pathogenesis studies, inbred mouse strains were not readily available. Mice have similar resistance to glanders infection as human beings, which prompted us to use the inbred mouse as a model for glanders infection in a non permissive host. Our findings base on histopathological study indicates that Siberian tiger strain has more severity in gross and necropsy examination but in pathologic lesion was qualitatively similar generally. Additionally, by bacterial isolation, we confirmed the presence of *B. mallei*.

### **Ethics**

I hereby declare all ethical standards have been respected in preparation of the submitted article.

### **Conflict of Interest**



The authors declare that they have no conflict of interest.

### Grant Support

This study was supported by a project of Razi Institute and Education and Research Deputy of Jihad-Agriculture Ministry with the grant No. 2-18-18-90035.

### Acknowledgments

We would like to thank Razi vaccine and Serum Research Institute, and Mr. Mohammad Mahdi Ghraghozloyan, Mr. Ebrahim Ghanbari and Mr. Hamed Kamali Dehghan for their technical assistance in Pathology department and also all staffs of the department of PPD Production, especially, Mr. Shojaat. Dashti pour and Mhdi Dehghan pour.

### References

- Acha, P.N., Szyfres, B. (1989). Glanders. In: Zoonoses and Communicable Diseases Common to Man and Animals, (2nd edn.). Pp: 86–89. Pan American Health Organization, Washington, DC.
- Benenson, A.S. (1995). Control of Communicable Diseases Manual, p. 301. American Public Health Association, Washington, DC.
- Darling, R. G., and Woods, J. B. (2004). USAMRIID's Medical Management of Biological Causalities Handbook. Operational Medicine Department, U.S. Army Medical Research Institute of Infectious Diseases, Fort Detrick, MD, USA.
- DeShazer, D., Waag, M., Fritz, D.L., Woods, D.E.(2001). Identification of a Burkholderia mallei polysaccharide gene cluster by subtractive hybridization and demonstration that the encoded capsule is an essential virulence determinant. Microbial Pathogenesis 30(5): 253–269.
- Dungworth, D.L. (1993). The respiratory system. In: K.V.F., Jubb, P.C., Kennedy, and N. Palmer.,(Ed), Pathology of Domestic Animals, (4nd edn.).Pp: 553–555. Academic Press, New York, NY.
- Dyadishchev, N.R., Vorobyev A.A., Zakharov, S.B. (1997). Pathomorphology and pathogenesis of glanders in laboratory animals. Zhurnal Mikrobiologii Epidemiologii i Immunobiologii 2:60–64.
- Ferster, L.N., Kurilov, V.Y. (1982). Characteristics of the infectious process in animals susceptible and resistant to glanders. Arkh Patol 44:24–30.
- Gilad, J. (2007). Burkholderia mallei and Burkholderia pseudomallei: the causative micro-organisms of glanders and melioidosis. Recent Pat Antiinfect Drug Discov 2(3):233–41.
- Harley, V.S., Dance, D.A.B., Tovey, G., McCrossan M.V., Drasar B.S. (1998). An ultrastructural study of the phagocytosis of Burkholderia pseudomallei. Microbios 94:35–45.
- Hornick, R.B. (1982) Diseases due to Pseudomonas mallei and Pseudomonas pseudomallei. In: R.J. Wedgewood (Ed.), Infections in Children Pp: 910–913. Harper & Row, Philadelphia, PA.
- Howe, C. (1949) Glanders. In: H.A. Christian (Ed.), The Oxford Medicine Pp: 185–201. Oxford University Press, New York, NY.
- Kazantseva, A.P., Matkovskii, V.S. (1970) Specific lung disorders in especially dangerous and some little-studied infections (review of the foreign literature). Voen Med Zh 7:82–6.
- Kovalev, G.K. (1971) Glanders (review). Zh Mikrobiol Epidemiol Immunobiol 48:63–70.
- Marco, A.J., Domingo, M., Ruberte, J., Carretero, A., Briones, V., Dominguez, L.(1992) Lymphatic drainage of Listeria monocytogenes and Indian ink inoculated in the peritoneal cavity of the mouse. Lab Anim 26:200–205.
- Miller, W.R., Pannell, L., Cravitz, L., Tanner, W.A., Rosebury, T. (1948) Studies on certain biological characteristics of Malleomyces mallei and Malleomyces pseudomallei. II. Virulence and infectivity for animals. J Bacteriol 55:127–135.
- Mims, C.A., Dimmock, N.J., Nash, A., Stephen, J. (1995) Mim's Pathogenesis of Infectious Disease Pp: 75–105. Academic Press, New York, NY.
- Nicoletti, P. L. (2007) Glanders. In: D. C., Sellon and M. T. Long (Ed.), Equine infectious diseases, (9th edn.). Pp: 345–348. Saunders, St Louis.
- OIE (World Organisation for Animal Health) (2008) Glanders. Available at [http://www.oie.int/fileadmin/Home/eng/Health\\_standards/tahm/2.05.11\\_GLANDERS.pdf](http://www.oie.int/fileadmin/Home/eng/Health_standards/tahm/2.05.11_GLANDERS.pdf) (accessed January 26, 2012).
- Parker, M.T., (1990) Glanders and melioidosis. In: M.T., Parker and L.H., Collier (Ed.), Topley & Wilson's Principles of Bacteriology, Virology and Immunity,( 8th edn.). Pp: 392–394. BC Decker, Philadelphia, PA.
- Popov, S.F., Kurilov, V., Iakovlev, A.T. (1995) Pseudomonas pseudomallei and Pseudomonas mallei are capsule-forming bacteria. Zh Mikrobiol Epidemiol Immunobiol 5:32–36.

- Popov, S. F., Tikhonov N. G., Piven, N. N., Kurilov, V., and Dement'ev I. P. (2000): The role of capsule formation in *Burkholderia mallei* for its persistence *In vivo*. *Zh. Mikrob. Epid. Immunol.* 3:73–75.
- Redfearn, M.S., Palleroni, N.J. (1975) Glanders and melioidosis. In: W.T. Hubbert, W.F. McCulloch, and P.R. Schnurrenberger (Ed.), *Diseases Transmitted from Animals to Man*, ( 6th edn.). Pp: 110–128. Charles C. Thomas, Springfield, IL.
- Rotz, L. D., Khan, A. S., Lillibridge, S. R., Astroff, S. M., and Hughes, J. M.(2002) Public health assessment of potential biological terrorism agents. *Emerg. Infect. Dis.* 2:225–230.
- Sanford, J.P. (1991) *Pseudomonas* infection: glanders and melioidosis. In: G.T .Strickland (Ed.), *Tropical Medicine*, (7th edn.). p: 450. WB Saunders, Philadelphia, PA.
- Sanford, J.P. (1990) *Pseudomonas* species (including melioidosis and glanders). In: ed. G.L .Mandell, J.R Douglas, and J.E. Bennett (Ed.), *Principles and Practice of Infectious Diseases*, (3rd edn.). Pp: 1692–1696. Churchill Livingstone, New York, NY.
- Srinivasan, A., Kraus, C. N. DeShazer, D., Becker, P. M., Dick, J. D., Spacek, L., Bartlett, J. G. Byrne., W. R. and Thomas., D. L. (2001) Glanders in a military research microbiologist. *New Engl. J. Med.* 345: 256–258.
- Stundick, M. V., Albrecht, M. T., Houchens, C. R., Pierce Smith, A. Dreier. T. M. Larsen J.C. (2013a) Animal Models for *Francisella tularensis* and *Burkholderia* Species: Scientific and Regulatory Gaps Toward Approval of Antibiotics Under the FDA Animal Rule. *Vet Pathol* 50: 877-892.
- Stundick, M. V., Albrecht, M. T., Houchens, C. R., Pierce Smith, A., Dreier, T. M., and Larsen, J. C.(2013b) Recommendations to Improve Collaboration and Expedite Acceptance of Animal Models *Vet Pathol* 50(5):893-894.
- Wernery, U., Zacharia, R., Wernery, R., and Joseph, S. (2005) Ten years of freedom from notifiable equine diseases in the United Arab Emirates, Pp:1–4. *Proceeding of 15th International Conference of Racing Analysts and Veterinarians*, Dubai, UAE.
- Wittig, M. B., Wohlsein, P. Hagen, R. M., AL Dahouk, S., Tomaso, H., Scholz, H. C., Nikolaou, K., Wernery, R., Wernery, U., Kinne, J., Elschner, M., and Neubauer, H. (2006) Glanders-a comprehensive review. *Dtsch. Tiera'rztl. Wochenschr.*3:323–330.