Strain Dependent Immunomodulation by Live Attenuated Infectious Laryngotracheitis Virus Vaccines: Differential Cytokine Responses and Tracheal Tissue Integrity in Chickens

Iman Pouladi [a], Zahra Ziafati Kafi [a], Hossein Hosseini [b], Arash Ghalyanchi Langeroudi [a], Amin Jaydari [c], Hamideh Najafi [*a]

a Department of Microbiology and Immunology, Faculty of Veterinary Medicine, University of Tehran, Iran.

b Department of Clinical Sciences, Faculty of Veterinary Medicine, Karaj Branch, Islamic Azad University, Alborz, Iran.

c Department of Microbiology and Food Hyginen, Faculty of Veterinary Medicine, Lorestan University, Khorramabad, Iran.

1. Name: Iman Pouladi

Address: Department of Microbiology and Immunology, Faculty of Veterinary Medicine, University of Tehran, Iran

E-mail: Imanpouladi96a@gmail.com

ORCID Codes: 0000-0002-0640-2727

2. Name: Zahra Ziafati Kafi

Address: Department of Microbiology and Immunology, Faculty of Veterinary Medicine, University of Tehran, Tehran, Iran

E-mail: Zahra.ziafati@ut.ac.ir

ORCID Codes: 0000-0002-8824-1276

3. Name: Hossein Hosseini

Address: Department of Clinical Sciences, Faculty of Veterinary Medicine, Karaj Branch, Islamic Azad University, Alborz, Iran.

E-mail: hosseini.ho@gmail.com

ORCID Codes: 0000-0002-8248-3979

4. Name: Arash Ghalyanchi Langeroudi

Address: Department of Microbiology and Immunology, Faculty of Veterinary Medicine, University of Tehran, Iran

Preprint

E-mail: ghalyana@ut.ac.ir

ORCID Codes: 0000-0002-3031-5084

5. Name: Amin Jaydari

Address: Department of Microbiology and Food Hyginen, Faculty of Veterinary Medicine, Lorestan University, Khorramabad, Iran.

E-mail: jaydari.a@lu.ac.ir

ORCID Codes: 0000-0002-5880-5229

6. Name: Hamideh Najafi

Address: Department of Microbiology and Immunology, Faculty of Veterinary Medicine, University of Tehran, Tehran, Iran

E-mail: h_najafi@ut.ac.ir

ORCID Codes: 0000-0001-5329-5808

Corresponding Author:

Name: Hamideh Najafi

Address: Department of Microbiology and Immunology, Faculty of Veterinary Medicine, University of Tehran, Tehran, Iran

E-mail: h_najafi@ut.ac.ir

ORCID Codes: 0000-0001-5329-5808

Tel: +98 911-275-3200

Preprint

Abstract

Introduction: Infectious laryngotracheitis virus (ILTV) remains an important respiratory pathogen of poultry, and strain variation can influence disease severity and host immune responses.

Methods: This study compared the inflammatory responses and tracheal pathological changes induced by a virulent field strain and two live attenuated ILTV vaccines Chicken Embryo Origin (CEO) and Tissue Culture Origin (TCO). Chickens were experimentally infected with a field strain, CEO vaccine strain, or TCO vaccine strain, and a control group did not receive the virus. We collected tracheal tissues at 2, 4, 6, and 8 days post-inoculation (dpi). We determined mRNA expression levels of IL-4, IL-6, and TNF-α by quantitative real-time PCR. We used histopathological examination to evaluate tracheal lesions.

Results: The field strain produced the strongest inflammatory response, significantly increasing IL-4, IL-6, and TNF-α levels compared with the vaccinated and control groups, with peak cytokine activation at 8 dpi and severe tracheal lesions. Conversely, responses and histopathological changes were markedly reduced in vaccine strains CEO and TCO, with TCO exhibiting a more regulated inflammatory profile and fewer changes in tracheal tissue than CEO.

Conclusion: These findings reveal that ILTV affects the balance between inflammatory activation and respiratory tissue damage in a strain-dependent manner. Attenuated vaccine strains provoke a controlled host response, in contrast to the virulent field strain, highlighting the importance of considering immune stimulation and tissue safety when selecting ILTV vaccines.

Preprint

Keywords: cytokine response; Infectious *laryngotracheitis virus*; inflammatory responses; tracheal histopathology; vaccine strains

1. Introduction

Due to their high contagion and quick transmission, respiratory avian viral infections pose a serious threat to the worldwide poultry industry, resulting in morbidity, death, and financial losses. Despite its significant worldwide impact, infectious laryngotracheitis (ILT), which is caused by the infectious laryngotracheitis virus (ILTV), has received little attention [1, 2]. ILT primarily affects poultry's upper respiratory tract and is characterized by a double-stranded DNA genome and an icosahedral nucleocapsid [3]. With mortality rates ranging from 5% to 70%, this disease can cause a lifelong latent infection and has serious economic repercussions, including decreased egg output, reduced bird weight, and increased susceptibility to other viruses [4, 5]. Clinical signs of ILT include nasal discharge, conjunctivitis, respiratory distress, coughing, and potential suffocation. The main strategy for preventing infectious laryngotracheitis (ILT) is vaccination; however, current live attenuated vaccines may contain pathogenic particles that can revert to virulence [6, 7]. Pre-existing antibody interference and insufficient control of viral shedding hinder alternatives such as vector-based and recombinant vaccines [8]. By focusing on vaccine-activated immune genes and their role in protecting chicks after infection, immunological research is expanding understanding of the processes underlying vaccine-induced immunity [9].

The human immune response to Infectious Laryngotracheitis Virus (ILTV) is characterized by a difficult balance: an efficient inflammatory response is essential to limit viral replication, but

Preprint

excessive inflammation can seriously harm the tracheal epithelium [3, 9]. Certain cytokines were chosen for this investigation due to their unique and complementary functions in maintaining this equilibrium. An early inflammatory response to ILTV is indicated by elevated interleukin-6 (IL-6), a pro-inflammatory cytokine that rapidly increases during respiratory virus infections, signaling mucosal inflammation and lymphocyte recruitment [9]. During viral infections, tissue necrosis and a decline in respiratory epithelial integrity are correlated with the upregulation of tumor necrosis factor-alpha (TNF-α), which mediates epithelial damage and death [3]. In contrast, the Th2/regulatory component of the immune response is represented by interleukin-4 (IL-4), which supports tissue repair and immunological regulation while reducing Th1-driven inflammation [9]. Together, the dynamics of IL-6, TNF-α, and IL-4 provide a more complete picture of the tracheal mucosa's inflammatory state than histological lesion scoring alone.

Compared to attenuated vaccination strains, virulent ILTV strains cause more severe tracheal lesions [4]. Nevertheless, little is known about how attenuated vaccination strains, particularly those of tissue culture origin (TCO) and chicken embryo origin (CEO), alter the host inflammatory response. Although cytokine production from ILTV infection or immunization has been observed in earlier research, a direct comparison of the inflammatory responses in chickens has not been carried out [9]. Evaluating vaccine safety and efficacy in protecting respiratory tissue while eliciting an immune response requires understanding these immunomodulatory characteristics.

A virulent field strain and two marketed attenuated ILTV vaccines (CEO and TCO) were compared in SPF chickens for the kinetics and amount of IL-4, IL-6, and TNF-α mRNA production, as well as related tracheal histological alterations. According to the hypothesis, tissue

Preprint

integrity and vaccination safety would be impacted by the different inflammatory profiles that the CEO and TCO strains would cause.

2. Materials and methods

2.1. Study Design

In a controlled trial conducted in 2025 at the Faculty of Veterinary Medicine, University of Tehran, researchers divided 100 one-day-old Leghorn chicks sourced from the Razi Institute into four groups of 25 birds each. They were certified as Specific Pathogen Free (SPF) and divided into four groups of 25 birds each: three experimental groups and one control group. Separate isolation units were allocated for each group. At 20 days of age, the first group was inoculated with a pathogenic field strain of the Infectious Laryngotracheitis Virus (ILTV); the second group received the CEO vaccine (produced by the Razi Institute, Iran), and the third group received the TCO vaccine (produced by FATRO). We administered all vaccinations via a combined intraocular (50 µL per eye) and intranasal (100 µL) route, totaling 200 µL per bird, while the control group received sterile PBS. The 20-day mark was selected because, at this stage, the respiratory tract mucosa is immunologically "naive" and free from maternal antibodies.

2.2. ILTV Virus

At the University of Tehran, frozen chorioallantoic membrane (CAM) samples were homogenised into 10% (w/v) suspensions in sterile PBS, clarified by centrifugation (3,000 × g, 15 min, 4°C), and the supernatant was inoculated onto CAM from 10-day-old SPF embryonated eggs. After 4–5 days at 37°C, CAMs with distinct pock lesions were collected to prepare the virus.

Preprint

Using primary chicken embryo liver (CEL) cells from 14-day-old SPF embryos, the virus stock was titrated. CEL monolayers in 96-well plates were inoculated with ten-fold dilutions in DMEM (100 µL) (four replicates/dilution). After one hour of adsorption, the inoculum was withdrawn, maintenance medium was added, and plates were incubated for five to seven days at 37°C with 5% CO2. Every day, cytopathic effects were observed, and the Reed-Muench method was used to compute TCID50. As previously mentioned, each bird was given 103.5 TCID50 in 200 µL (100 µL intratracheally + 50 µL per eye) for the challenge. As directed by the manufacturers, the CEO (RAZi) and TCO (FATRO) vaccines were reconstituted [10, 11].

2.3. Sample collection and preparation

In accordance with the University of Tehran's ethical guidelines (Ethics Code: IR.UT.VETMED.REC.1403.002), we euthanised five chickens from each group by CO_2 inhalation and cervical dislocation on days 2, 4, 6, and 8 post-inoculation. Tracheal tissues were harvested under sterile conditions and processed separately for three analyses: RNA extraction, cDNA synthesis, and quantitative real-time PCR (qRT-PCR) to quantify IL-4, IL-6, and TNF-α expression.

2.4. Histopathology

After processing the formalin-fixed upper tracheal segments, we produced several transverse slices from the proximal, middle, and distal regions (at least three sections per bird) at 5 µm thickness and embedded them in paraffin. Haematoxylin and eosin (H&E) was used to stain tissue sections for histological analysis. According to [12], a modified semi-quantitative grading system was created, with a score of 0 denoting intact epithelium, scores of 1-4 denoting

Preprint

185 increasing inflammatory and epithelial alterations, and a score of 4 denoting severe disruption
186 with syncytia and intranuclear inclusion bodies.

187 *2.5. Molecular test to confirm the presence of the virus*

188 A polymerase chain reaction (PCR) assay was performed to confirm the presence of ILTV in
189 tracheal samples. Viral DNA is extracted using a DNA extraction kit (DNA Singapore Sinaclon,
190 Iran) and amplified by primers amplifying the UL15 gene with the forward sequence UL15aF:
191 TTGCTGTGCTATTTCGCGTG and reverse sequence UL15aR:
192 GTAAATCGTTTAGTGCGGCAT to a length of 113bp. PCR conditions: primers for 10 min at
193 95°C, followed by 40 cycles of 95°C for 15 s, 60°C for 1 min, and 72°C for 20 s, then 5 min at
194 72°C [13]. A known ILTV-positive DNA sample obtained from a previous ILTV-positive flock
195 was used as the positive control, and sterile water was used as the negative control.

196 *2.6. Real-time test*

197 A commercial RNA extraction kit was used to extract total RNA in accordance with the
198 manufacturer's instructions. We used reverse transcriptase and random hexamer primers to
199 synthesize single-stranded cDNA from 2 µg of total RNA. Using previously reported primers
200 [14–16], we performed quantitative real-time PCR (qRT-PCR) to measure TNF-α, IL-4, and IL-6
201 mRNA expression (Table 1). The 2^−ΔΔCt technique was used to calculate relative expression
202 levels, which were then normalised to the control group.

203 Table 1: Sequences of primers and probes used for quantitative real-time PCR in this study

ILTV Target Genes	Primer or probe	Sequence (5′→3′) or description	Reference

Preprint

Chicken IL-6	F	CACGATCCGGCAGATGGT EU170468	[14]
	R	TGGGCGGCCGAGTCT	
	P	ATAAATCCCGATGAAGTGGTCATCC	
IL4	F	AACATGCGTCAGCTCCTGAAT	[15]
	R	TCTGCTAGGAACTTCTCCATTGAA	
	P	FAM-AGCAGCACCTCCCTCAAGGCACC-TAMRA	
TNF	F	CGCTCAGAACGACGTCAA	[16]
	R	GTCGTCCACACCAACGAG	
	P	Cybergreen	

2.7. Statistical analysis

For multiple comparisons between groups, cytokine expression data were analysed using the Kruskal-Wallis test followed by Dunn's post-hoc test; similarly, histopathological lesion scores were analysed using the Kruskal-Wallis test followed by Dunn's post-hoc test; all analyses were carried out using GraphPad Prism software; a P-value < 0.05 was deemed statistically significant.

3. Results

3.1. Clinical Observations and Viral Genome Detection

No experimental group, including those receiving the CEO and TCO vaccine strains, experienced any death or euthanasia throughout the eight-day monitoring period after inoculation. With no fatalities, clinical scoring showed that the Challenge group's symptoms were noticeably worse than those of the Vaccine 1 (CEO) and Vaccine 2 (TCO) groups. Clinical symptoms were similar among the Vaccine 1, Vaccine 2, and Control groups. ILTV was found in

Preprint

all challenged groups (Challenge, Vaccine 1, and Vaccine 2) at all sample time points (2, 4, 6, and 8 dpi) according to viral genome identification by PCR on tracheal tissues; however, no viral genome was found in the Control group at any time point (Figure 1). All challenged groups had detectable viral DNA through 8 dpi, suggesting active viral replication continued during the observation period.



Figure 1. PCR amplification of the UL15 gene (113 bp) in tracheal tissues collected at 2 days post-inoculation (dpi). Lane 1: 100 bp DNA ladder; Lane 2: positive control (known ILTV-positive DNA sample); Lane 3: negative control (sterile water); Lane 4: Challenge group; Lane 5: Vaccine 1 (CEO) group; Lane 6: Vaccine 2 (TCO) group; Lanes 7–9: Control group (negative results).

3.2. Differential Expression of Cytokine mRNA in Tracheal Tissues

We used the 2^{ΔΔCt} technique to quantify the relative mRNA expression levels of the immune-related genes IL-4, IL-6, and TNF-α in chicken tracheal tissues, normalized to the

Preprint

control group. Figures 2- 4 show temporal expression patterns, while Table 1 summarizes the full dataset.

3.3. IL-4 Expression

After inoculation with the field strain, IL-4 transcript levels rose dramatically, reaching 2,378-fold at 2 dpi (P = 0.001 vs. Control; Kruskal–Wallis with Dunn's post-hoc). Conversely, Vaccine 1 (CEO) showed a moderate increase (9.85-fold), while Vaccine 2 (TCO) remained close to baseline (3.63-fold). Although the difference between Vaccine 1 and Vaccine 2 was not significant (P > 0.05), Challenge differed significantly from both vaccine groups (P < 0.001) (Figure 2A and 2B).

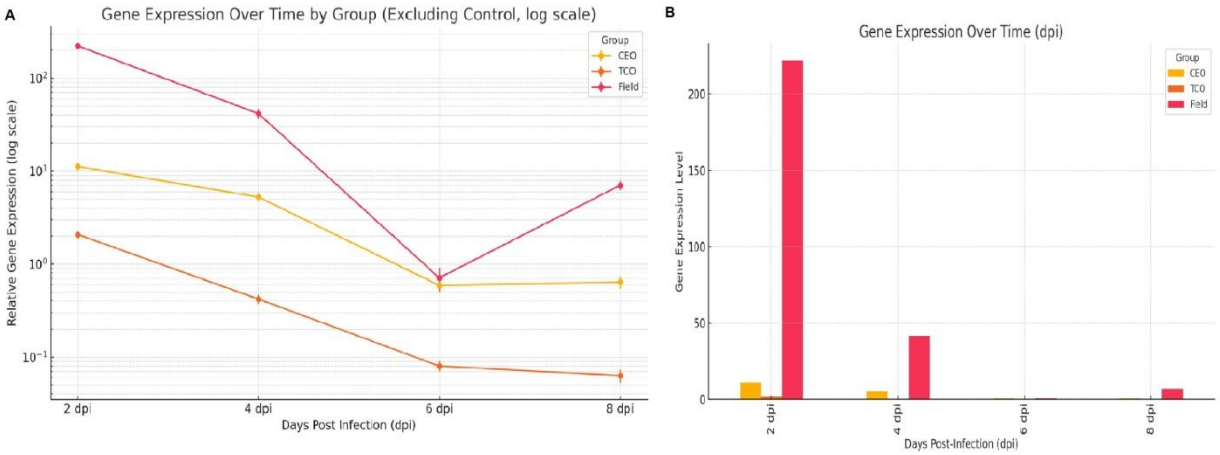

Figure 2: A) IL-4 mRNA expressions in relation to the experimental groups (Control, CEO, TCO, Field). Strong IL-4 induction was demonstrated by the Field group's much greater fold-change. B) IL-4 expression over time (2–8 dpi). While vaccinated groups stayed close to baseline, field-challenged birds peaked early and then dropped, indicating effective regulation of IL-4 activation.

3.4. IL-6 Expression

A study observed varying IL-6 expression levels across groups (Figure 3A). The field-exposed group exhibited a significant increase in IL-6 (~10.56-fold), peaking at 4 days post-infection (dpi) before dropping to baseline by 8 dpi (Figure 3B). The TCO group showed a considerable rise (~4.29-fold), while the CEO-vaccinated birds displayed only a minor increase (~0.78-fold). IL-6 levels remained low in both vaccinated groups throughout, indicating that vaccination effectively reduced pro-inflammatory signaling.

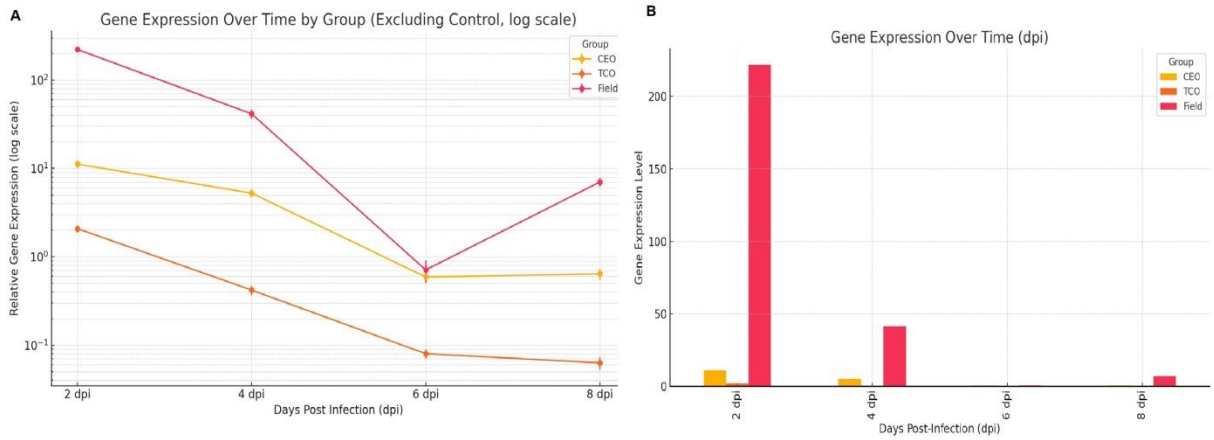

Figure 3: A) IL-6 expression is compared between treatment groups. While immunization (CEO and TCO) significantly decreased IL-6 overexpression, the Field group had the greatest transcription. B) Time-course expression of IL-6 between 2 and 8 dpi. While vaccinated birds maintained weaker and fleeting responses, the Field group surged rapidly at 4 dpi, which correlated with the acute period of infection.

3.5. TNF-α Expression

TNF-α showed group-dependent regulation, with a substantial increase (~3.45-fold) in the field-strain group, peaking between 2 and 4 days post-infection (dpi) before declining (Figure 4A). The CEO-vaccinated group showed a notable suppression (~0.038-fold), while the TCO-vaccinated group displayed a decrease (~0.26-fold). TNF-α expression remained consistently low over time in both vaccinated groups, indicating that immunization diminished excessive tissue inflammation (Figure 4B).

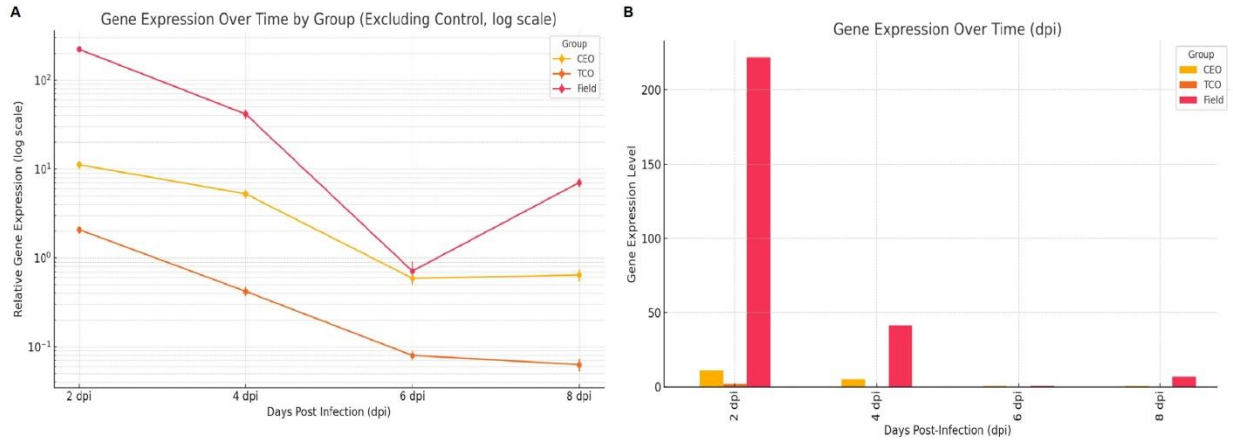

Figure 4: A) CEO and TCO vaccines effectively inhibited TNF-α levels, whereas field birds exhibited increased levels compared to controls. B) Field birds displayed an initial peak in TNF-α expression followed by normalization, in contrast to vaccinated birds, which maintained consistently low levels.

3.6. Overall Cytokine Modulation Pattern

The study highlighted distinct cytokine expression patterns across experimental groups. TCO-vaccinated birds had similar cytokine levels to unvaccinated controls, while field-challenged

birds showed the highest levels. The CEO-vaccinated group showed moderate cytokine increases, indicating an intermediate immune response. TCO vaccination notably reduced cytokine upregulation by lowering IL-4, IL-6, and TNF-α levels, suggesting effective immunomodulation. Overall, the findings indicate that vaccination offers protection and modulates cytokine-driven inflammation in the tracheal mucosa of laying hens.

3.7. Tracheal histopathological lesion evaluation

There were no significant differences between the groups at 2 dpi (P = 0.284, Kruskal–Wallis); at 4 dpi, the Challenge group's lesion scores were significantly higher than those of the Control group (P = 0.014, Dunn's post-hoc) and Vaccine 2 (P = 0.021); the difference between Challenge and Vaccine 1 was not significant (P = 0.317); at 6 and 8 dpi, the Challenge's lesion scores were significantly higher than all comparisons (P < 0.01), but there was no significant differences between Vaccine 1 and Vaccine 2 (P > 0.05) (Figure 5).

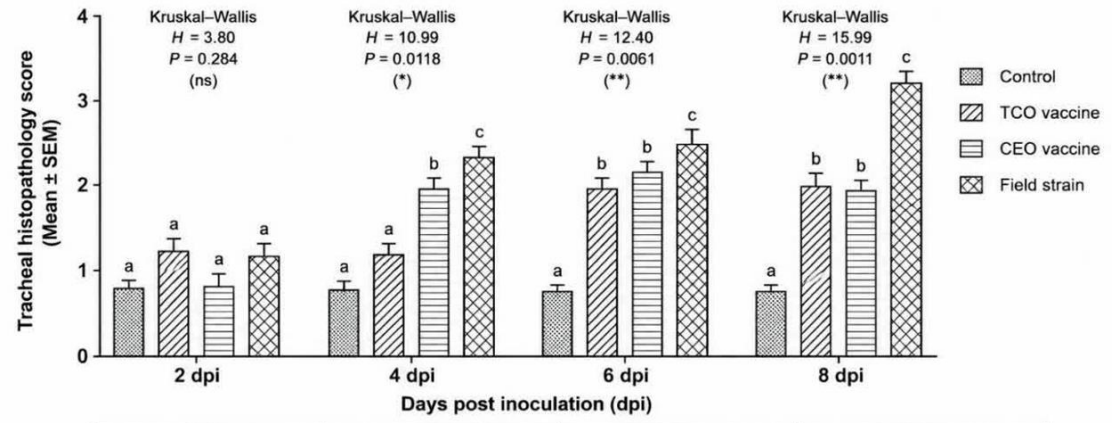

2 dpi	4 dpi	6 dpi	8 dpi
Dunn's post hoc	Dunn's post hoc	Dunn's post hoc	Dunn's post hoc
No significant differences	Field vs Control: *P* = 0.014*	Field vs Control: *P* = 0.008**	Field vs Control: *P* = 0.002**
	Field vs TCO: *P* = 0.021*	Field vs TCO: *P* = 0.039*	Field vs TCO: *P* = 0.039*
	Field vs CEO: *P* = 0.317 (ns)	Field vs CEO: *P* = 0.236 (ns)	Field vs CEO: *P* = 0.028*
	CEO vs Control: *P* = 0.046*	CEO vs Control: *P* = 0.045*	TCO vs Control: *P* = 0.034*
	CEO vs TCO: *P* = 0.048*	CEO vs TCO: *P* = 0.564 (ns)	CEO vs Control: *P* = 0.034*

Figure 5. Tracheal histopathology lesion scores were analyzed at 2, 4, 6, and 8 days post-inoculation across control, TCO vaccination, CEO vaccine, and field strain groups. The results indicated that the field strain group exhibited significantly more severe lesions compared to the vaccination groups and controls, particularly at 8 dpi (Kruskal–Wallis, $P < 0.05$) [12].

4. Discussion

After inoculation with a virulent field strain and two live-attenuated ILTV vaccines, the study found significant differences in pathogenicity and host response. The virulent strain caused the most severe tracheal damage, with increased inflammatory cytokine expression and histopathological lesion scores rising from 4 to 8 days post-inoculation. This suggests that acute ILTV infection drives heightened inflammatory activation and viral proliferation, leading to respiratory tissue damage. These findings align with previous research showing that virulent ILTV primarily affects respiratory epithelial cells, causing degeneration and inflammation [3, 17, 18]. Moreover, we observed a strong correlation between inflammatory intensity and tissue pathology, as the field-strain-infected group showed the strongest cytokine responses alongside extensive histological damage [2, 19].

Viral DNA was detected in the tracheal tissues of all groups at several time points (2, 4, 6, and 8 dpi), with no discernible differences in detection patterns. This is consistent with earlier research showing that ILTV can remain in the respiratory system for seven to fourteen days following injection [20]. Increased lesion severity in the Challenge group correlates with continued viral replication, as viral DNA persisted until 8 dpi. Interestingly, although the vaccine groups had viral DNA, their tracheal lesion severity remained much lower. This suggests that the attenuated strains either replicated less or triggered a more controlled inflammatory response, reducing tissue damage despite viral persistence.

Preprint

In this study, both CEO and TCO vaccination strains caused limited tracheal changes, and vaccine-associated lesions were significantly milder than those caused by the field strain. This underscores the vaccines' attenuated nature, which supports protective immunity while minimizing severe respiratory damage [21, 22]. Earlier research indicates that live ILTV vaccines can offer protection against virulent challenges, reflecting differences in replication, attenuation, and tissue reactivity [20, 21]. CEO vaccination prompted a stronger, earlier tissue response than TCO, likely due to differences in replication efficiency and attenuation properties. Histopathological findings showed milder tissue reactions with TCO compared with more pronounced lesions associated with CEO in the early post-vaccination phases [19, 23]. The TCO group's response showed a favorable balance between viral replication and immune control. Genetic analyses have revealed variations that could influence the pathogenic behaviors of CEO and TCO strains [24]. These findings suggest that TCO vaccination reduces tissue damage and optimizes the inflammatory response due to its unique genetic makeup. Notably, while vaccine-induced lesions remained restricted in later stages, the field strain exhibited increasing severity, peaking at eight days post-infection [22, 25]. This suggests that attenuation correlates with reduced viral activity, preventing prolonged, harmful inflammatory responses. Collectively, the study highlights the importance of balancing tissue safety and induced immunity in ILTV vaccination strategies.

5. Conclusion

This study highlights how ILTV strain characteristics affect inflammatory responses and respiratory tissue integrity. Attenuated vaccine strains produced better-controlled reactions and less tissue damage, whereas the virulent field strain caused heightened inflammatory activation

Preprint

and severe tracheal lesions. These findings underscore the importance of sufficient immune activation to mitigate excessive inflammation during ILTV immunization.

Acknowledgements

The authors of this article wish to express their gratitude to all the staff and colleagues in the Department of Virology at the Faculty of Veterinary Medicine, University of Tehran, for their cooperation.

Conflict of interest

The authors declare no known competing financial interests or personal relationships that could have influenced the work reported in this paper.

Ethics approval

All animal experiments were conducted in accordance with the ethical principles and laboratory regulations of the University of Tehran at the Faculty of Veterinary Medicine, University of Tehran, Tehran, Iran (Code: IR.UT.VETMED.REC.1403.002).

Funding

This work is based upon research funded by the Iran National Science Foundation (INSF) under project No 4042060.

Data availability

Preprint

The data used to support the findings of this study are available from the corresponding author upon reasonable request.

References

1. Ali MZ. Common respiratory diseases of poultry in Bangladesh: A review. SJA. 2020; 18(1):1-1. doi. 10.3329/sja.v18i1.48377
2. Liu H, Pan S, Wang C, Yang W, Wei X, He Y, Xu T, Shi K, Si H. Review of respiratory syndromes in poultry: pathogens, prevention, and control measures. Vet Res. 2025; 56(1):101. DOI: 10.1186/s13567-025-01506-y
3. Mo J, Mo J. Infectious *laryngotracheitis virus* and avian metapneumovirus: a comprehensive review. Pathogens. 2025; 14(1):55. DOI: 10.3390/pathogens14010055
4. Perez-Contreras A, Barboza-Solis C, Najimudeen SM, Checkley S, Meer FV, Joseph T, King R, Ravi M, Peters D, Fonseca K, Gagnon CA. Pathogenic and transmission potential of wildtype and chicken embryo origin (CEO) vaccine revertant infectious *laryngotracheitis virus*. Viruses. 2021; 13(4):541. DOI: 10.3390/v13040541
5. Priya RJ, Rao GV, Pazhanivel N, Vijayarani K, Reetha TL, Gowthaman V, Raja P. Pathological diagnosis and genomic characterization of ICP4 gene of lnfectious *laryngotracheitis virus* (ILTV) isolates in clinically infected chicken in Tamil Nadu, India. IJAR. 2023; 57(6):770-6. DOI: 10.18805/IJAR.B-4802
6. Shao G, Fu J, Pan Y, Gong S, Song C, Chen S, Feng K, Zhang X, Xie Q. Development of a recombinant infectious bronchitis virus vaccine expressing infectious *laryngotracheitis virus* multiple epitopes. Poult Sci. 2025; 104(1):104578. DOI: 10.1016/j.psj.2024.104578
7. Salhi O, Messaï CR, Ouchene N, Boussaadi I, Kentouche H, Kaidi R, Khelef D. Indicators and risk factors of infectious laryngotracheitis in layer hen flocks in Algeria. Vet World. 2021; 14(1):182. DOI: 10.14202/vetworld.2021.182-189
8. Manisaran R, Boomika P, Mythily V, Harshitha V, Balaji V. Review on Biosecurity Strategies in Poultry Farming: Controlling Infectious *Laryngotracheitis Virus* through Taxonomic Insights, Transmission Dynamics, and Replication Mechanisms. Sch Int J

Preprint

Tradit Complement Med. 2025;8(9):210-5. DOI: https://doi.org/10.36348/sijtcm.2025.v08i09.001

9. Elshafiee EA, Isham IM, Najimudeen SM, Perez-Contreras A, Barboza-Solis C, Ravi M, Abdul-Careem MF. Host responses following infection with Canadian-origin wildtype and vaccine revertant infectious *laryngotracheitis virus*. Vaccines. 2022; 10(5):782. DOI: 10.3390/vaccines10050782
10. Barboza-Solis C, Najimudeen SM, Perez-Contreras A, Ali A, Joseph T, King R, Ravi M, Peters D, Fonseca K, Gagnon CA, van der Meer F. Evaluation of recombinant herpesvirus of turkey laryngotracheitis (rHVT-LT) vaccine against genotype VI Canadian wild-type infectious *laryngotracheitis virus* (ILTV) infection. Vaccines. 2021; 9(12):1425. DOI: 10.3390/vaccines9121425
11. Magouz A, Medhat S, Abou Asa S, Desouky A. Detection of infectious laryngotracheitis virus (Gallid herpesvirus-1) from clinically infected chickens in Egypt by different diagnostic methods. Iran J Vet Res. 2018; 19(3):194. PMCID: PMC6184029
12. Maekawa D, Riblet SM, Whang P, Hurley DJ, Garcia M. Activation of cytotoxic lymphocytes and presence of regulatory T cells in the trachea of non-vaccinated and vaccinated chickens as a recall to an infectious *laryngotracheitis virus* (ILTV) challenge. Vaccines. 2021; 9(8):865. DOI: 10.3390/vaccines9080865
13. Mahmoudian A, Kirkpatrick NC, Coppo M, Lee SW, Devlin JM, Markham PF, Browning GF, Noormohammadi AH. Development of a SYBR Green quantitative polymerase chain reaction assay for rapid detection and quantification of infectious *laryngotracheitis virus*. Avian Pathol. 2011; 40(3):237-42. DOI: 10.1080/03079457.2011.553582
14. Baquero-Perez B, Kuchipudi SV, Ho J, Sebastian S, Puranik A, Howard W, Brookes SM, Brown IH, Chang KC. Chicken and duck myotubes are highly susceptible and permissive to influenza virus infection. J Virol. 2015; 89(5):2494-506. DOI: 10.1128/JVI.03421-14
15. Awad NF, Abd El-Hamid MI, Hashem YM, Erfan AM, Abdelrahman BA, Mahmoud HI. Impact of single and mixed infections with Escherichia coli and Mycoplasma gallisepticum on Newcastle disease virus vaccine performance in broiler chickens: an in vivo perspective. J Appl Microbiol. 2019; 127(2):396-405. DOI: 10.1111/jam.14303

Preprint

16. Rohde F, Schusser B, Hron T, Farkašová H, Plachý J, Härtle S, Hejnar J, Elleder D, Kaspers B. Characterization of chicken tumor necrosis factor-α, a long missed cytokine in birds. Front Immunol. 2018; 9:605. DOI: 10.3389/fimmu.2018.00605
17. Gopakumar G, Coppo MJ, Diaz-Méndez A, Hartley CA, Devlin JM. Host–virus interactions during infection with a wild-type ILTV strain or a glycoprotein G deletion mutant ILTV vaccine strain in an ex vivo system. Microbiol Spectr. 2025; 13(2):e01183-24. DOI: 10.1128/spectrum.01183-24
18. Alajaji AI. A Review of the Advanced Immunogens for the Protection of Poultry Flocks Against Infectious *Laryngotracheitis Virus*. Pakistan Vet J. 2024; 44(4):1006. DOI: 10.29261/pakvetj/2024.300
19. Coppo MJ, Devlin JM, Legione AR, Vaz PK, Lee SW, Quinteros JA, Gilkerson JR, Ficorilli N, Reading PC, Noormohammadi AH, Hartley CA. Infectious *laryngotracheitis virus* viral chemokine-binding protein glycoprotein G alters transcription of key inflammatory mediators in vitro and in vivo. J Virol. 2018; 92(1):10-128. https://doi.org/10.1128/jvi.01534-17
20. Vagnozzi AE, Beltrán G, Zavala G, Read L, Sharif S, García M. Cytokine gene transcription in the trachea, Harderian gland, and trigeminal ganglia of chickens inoculated with virulent infectious laryngotracheitis virus (ILTV) strain. Avian Pathol. 2018; 47(5):497-508. https://doi.org/10.1080/03079457.2018.1492090
21. Al-Zghoul MB, Saleh KM, Ababneh MM. Effects of pre-hatch thermal manipulation and post-hatch acute heat stress on the mRNA expression of interleukin-6 and genes involved in its induction pathways in 2 broiler chicken breeds. Poultry science. 2019; 98(4):1805-19. http://dx.doi.org/10.3382/ps/pey499
22. Lee SW, Devlin JM, Markham JF, Noormohammadi AH, Browning GF, Ficorilli NP, Hartley CA, Markham PF. Comparative analysis of the complete genome sequences of two Australian origin live attenuated vaccines of infectious *laryngotracheitis virus*. Vaccine. 2011; 29(52):9583-7. doi: 10.1016/j.vaccine.2011.10.055
23. Coppo MJ, Hartley CA, Devlin JM. Immune responses to infectious *laryngotracheitis virus*. Dev Comp Immunol. 2013; 41(3):454-62.doi: 10.1016/j.dci.2013.03.022
24. Tran TT, Andronicos NM, Ketheesan N, Nazir S, Walkden-Brown SW, Gerber PF. Determination of immune responses in mucosal lymphoid tissues following infectious

Preprint

laryngotracheitis virus (ILTV) eye drop and vent brush vaccination of chickens. Avian Pathol. 2026; 55(2):146-60. https://doi.org/10.1080/03079457.2025.2584351

25. Shah A, Rafique S, Peddireddi L, Wood B, Hemida MG. Genomic characterization of some infectious *laryngotracheitis virus* (ILTV) field isolates from vaccinated chicken farms reveals evidence of vaccine-related genetic drift. Virology. 2026:110900. https://doi.org/10.1016/j.virol.2026.110900

Preprint