Archives of Razi Institute Journal
"Arch. Razi Inst."

Journal Homepage: https://archrazi.areeo.ac.ir/

Research Paper

Pathological Study on the Prevalence and Morphopathological Patterns of Ovine Pulmonary Adenocarcinoma in Slaughtered Sheep in Semnan Province, Northeast Iran

Afshin Zahedi[1], Keivan Jamshidi[1*]

1. Department of Veterinary Pathology, Ga.C., Islamic Azad University, Garmsar, Iran.

Use your device to scan and read the article online

How to cite this article Zahedi A, Jamshidi K. Pathological Study on the Prevalence and Morphopathological Patterns of Ovine Pulmonary Adenocarcinoma in Slaughtered Sheep in Semnan Province, Northeast Iran. Archives of Razi Institute Journal. 2026; 81(4):857-864. https://doi.org/10.32598/ARI.81.4.3380

https://doi.org/10.32598/ARI.81.4.3380

Article info:
Received: 11 Feb 2026
Accepted: 13 Jun 2026
Published: 01 Jul 2026

Keywords:
Histopathology, Ovine pulmonary adenocarcinoma, Slaughterhouse

ABSTRACT

Introduction: Ovine pulmonary adenocarcinoma is a spontaneous lung tumor caused by a retrovirus in sheep, sharing notable similarities with certain types of human adenocarcinoma.

Materials & Methods: This study was carried out in Semnan Province, northeast Iran, for a period of six months from April to September 2016. A total number of 4079 local breed sheep, divided into three age groups as <1, 1–2, and >2 years old, were subjected to post-slaughter examination in the Semnan abattoir to detect any pathological lesions.

Results: Macroscopic pneumonic lesions were found and detected in the lungs of 259(6.35%) sheep. During the gross examination, 189 lungs (73%) were collected for more detailed histopathological analysis. These lungs were enlarged, did not collapse, and in some instances, contained a small amount of foamy fluid within the respiratory tract. Six (3.17%) of the 189 suspected lung samples showed histopathological lesions indicating ovine pulmonary adeneomatosis (OPA). These six lungs macroscopically were so heavy and waterlogged. The damaged lung areas were solid and light grey, particularly in the ventral region or diaphragmatic lobes. All six affected lungs had consistent histopathological characteristics and displayed typical lesions associated with atypical OPA. These features included papillary projections within the bronchioles and alveoli, sparse connective tissue stroma, infiltration of mononuclear cells and connective tissue, as well as swollen, foamy macrophages in the alveoli and bronchioles near the neoplastic lesions. In one instance, in addition to these changes, a prominent feature of the classic OPA form was noted, characterized by the presence of fibrin

*** Corresponding Author:**
Keivan Jamshidi, Professor.
Address: *Department of Veterinary Pathology, Ga.C., Islamic Azad University, Garmsar, Iran.*
E-mail: *k.jamshidi@iau-garmsra.ac.ir*

Copyright © 2026 The Author(s);
This work is licensed under a Creative Commons Attribution-NonCommercial 4.0 International license (https://creativecommons.org/licenses/by-nc/4.0/).
Noncommercial uses of the work are permitted, provided the original work is properly cited.

casts and neutrophils in the bronchial and alveolar lumens. The affected regions were largely similar and aligned with findings reported in other studies. All six affected lungs were from sheep older than two years.

Conclusion: There is often no clear distinction between atypical and classic OPA cases, and both forms can sometimes be found within the same lung.

1. Introduction

Ovine pulmonary adenocarcinoma or pulmonary adenomatosis, jaagsiekte (driving sickness), ovine pulmonary carcinoma (OPC), ovine pulmonary adnenomatosis (OPA), and epizootic adenomatosis, is a contagious lung cancer that primarily affects sheep and, less frequently, goats [1, 2]. This disease is a spontaneous lung tumor caused by a retrovirus in sheep sharing notable similarities with certain types of human adenocarcinoma [1]. The jaagsiekte sheep retrovirus (JSRV), the causative agent of OPA, is the only virus identified as causing naturally occurring lung adenocarcinoma, which can lead to mortality within a few weeks to several months [3]. The disease was first documented in South Africa in 1837 [4]. After that, OPA has been documented in most European countries, and also in Asia and the Americas [2]. The disease typically has an incidence rate of 2-5%, but in some flocks, it can rise to as high as 30%. OPA is not classified as a statutory notifiable disease, which means that accurate data on its prevalence is not collected in any country. Annual mortality rates in affected flocks have been reported to range from negligible to 10% [5]. In certain instances, mortality rates exceeding 50% have been observed [6]. Sheep with OPA exhibit a respiratory disease without fever, accompanied by weight loss [7].

Based on Iranian slaughterhouse investigations, the prevalence was approximately 3% in sheep over three years old from Chahar Mohal Bakhtiari [8], 0.22% from Fars Province [9], and 2.57% from Tabriz. The samples were initially selected based on the observation of gross lesions and subsequently confirmed through histopathological examination. JSRV is identified in the lymphoid tissues, peripheral blood mononuclear cells, tumors, and lung fluid of sheep with OPA, as well as in those that have not shown symptoms but have been in contact with infected flock members [1]. Sheep of any age can be affected; however, due to the prolonged incubation period, clinical symptoms are usually observed in mature sheep between the ages of two and four years [4]. In these animals, a considerable amount of thin, mucoid fluid (up to 200 mL), likely generated by neoplastic cells in the lungs, can be seen flowing from the nostrils. Initial gross lesions appear as enlarged, heavy lungs (2-3 times their normal weight) that are moist and have multiple firm nodules that are light purple or gray in color, varying in size and isolated from the normal lung tissue by a narrow emphysematous band [10]. There are two recognized pathological forms of OPA: classical and atypical [7]. In the classical form, neoplastic lesions are mainly found in the cranioventral areas of all lung lobes, whereas the atypical form is characterized by a more nodular appearance in the advanced and early stages of the disease [7].

We assessed the prevalence of OPA based on the morphopathological characteristics of the atypical and classical types of naturally occurring OPA in native sheep in Semnan Province in northeast Iran.

2. Materials and methods

2.1. Study area

The study was conducted at the Semnan Municipal Abattoir, in the capital of Semnan Province, Iran. Semnan Province is located at 35°34′22″N, 53°23′50″E in Iran. The various districts of the province are situated on the edges of the Iranian central plateau, resulting in the southern region being located in an arid desert zone, while the northern highlands experience a more temperate climate. The average elevation of Semnan Province is approximately 1,755 m above sea level. The province has a hot and dry climate, with an average annual rainfall of 135 mm. Because Semnan Province is located close to the central plateau of Iran, it has hot summers. Otherwise, its climate is relatively cool.

2.2. Sample collection

We assessed the lungs of 4,079 sheep post-slaughter. These sheep were raised on various farms in Semnan and on other farms in other districts of Semnan Province (including Garmsar, Shahrood, and Damghan). They were taken to the Semnan Municipal Abattoir for slaughter from April to September 2016. The sheep were

grouped by age as <1, 1–2, and >2 years old. Age, sex, and origin of the animals were recorded. The ages of the animals were determined according to their dental formulae. Standard meat inspection protocols were employed to identify any pathological lesions.

Macroscopic pneumonic lesions were found in the lungs belonging to 259(6.35%) sheep. A macroscopic examination, with a focus on superficial lung observation—particularly the diaphragmatic and visceral surfaces—was performed to look for OPA lesions. After a thorough gross inspection, we collected 189 lungs (73%) that were enlarged, did not collapse, and, in some cases, contained a small amount of foamy fluid within the respiratory tract for future histopathological analysis

2.3. Histopathologic examination

Histopathological investigation was conducted on tissue samples collected from the 189 grossly suspected lungs. Fixation of the lung specimens was done in 10% buffered formalin for 48 h, followed by paraffin embedding prior to sectioning. Tissue sections (4 µm) underwent haematoxylin and eosin (H&E) staining and were assessed by an optical microscope (OLYMPUS, BX-51M, USA).

3. Results

3.1. Gross pathology

All 189 ovine lungs selected for histopathological investigations had macroscopic lesions of interstitial pneumonia accounting for 73% of the total lesions. The lungs were unusually heavy, edematous, and failed to collapse, showed rib impressions, and were observed in some cases to be waterlogged. In addition, the damaged regions in some lungs were light grey and solid in color.

Among the 189 lungs examined, six had pulmonary adenomatosis. The gross characteristics of the lesions, especially when viewed in cross-section, suggested an atypical type of OPA. The gross lesions observed in the affected regions seemed similar across all six sheep lungs. Consolidated areas, varying in size from a few millimeters to several centimeters in diameter, were observed on the lung surfaces (Figures 1 and 2). The cut surfaces displayed numerous small and slightly raised white-gray nodules in each section. These nodules were encircled by narrow bands of emphysema, containing small translucent gray or reddish-gray foci measuring approximately 2 to 5 cm. All six affected lungs were sourced from sheep older than two years.

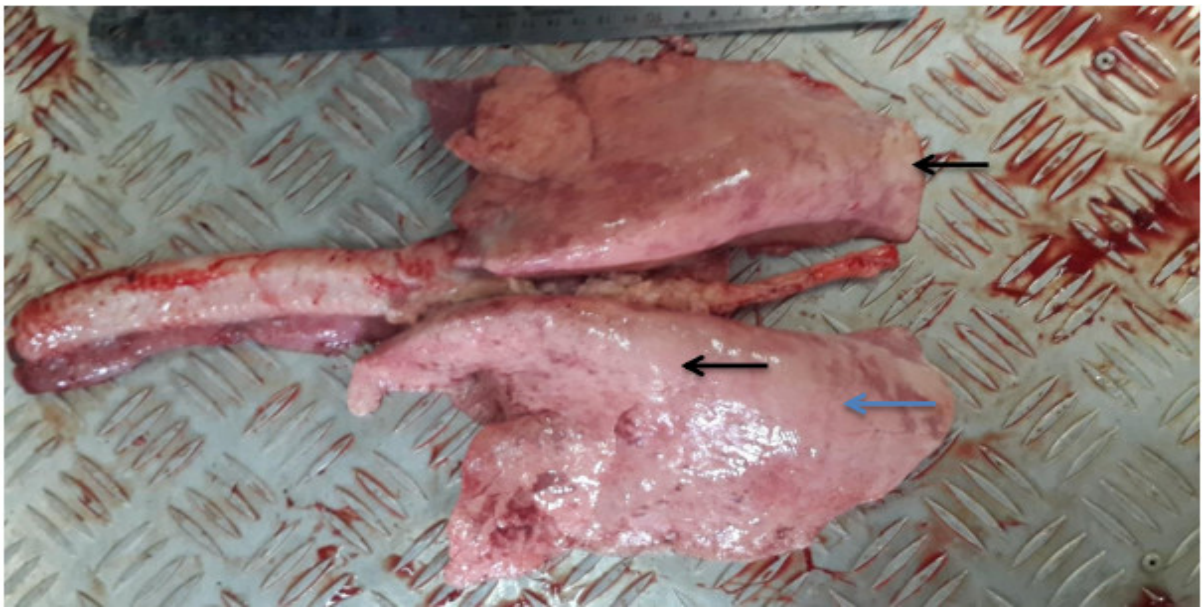

Figure 1. Lung, sheep suspected for OPA

Note: Lung is enlarged, edematous, and fails to collapse. Rib impressions on the dorsal surface are visible (blue arrow) and consolidated light gray foci with a diameter of a few millimeters to a few centimeters are observed on the lung surface (black arrow).

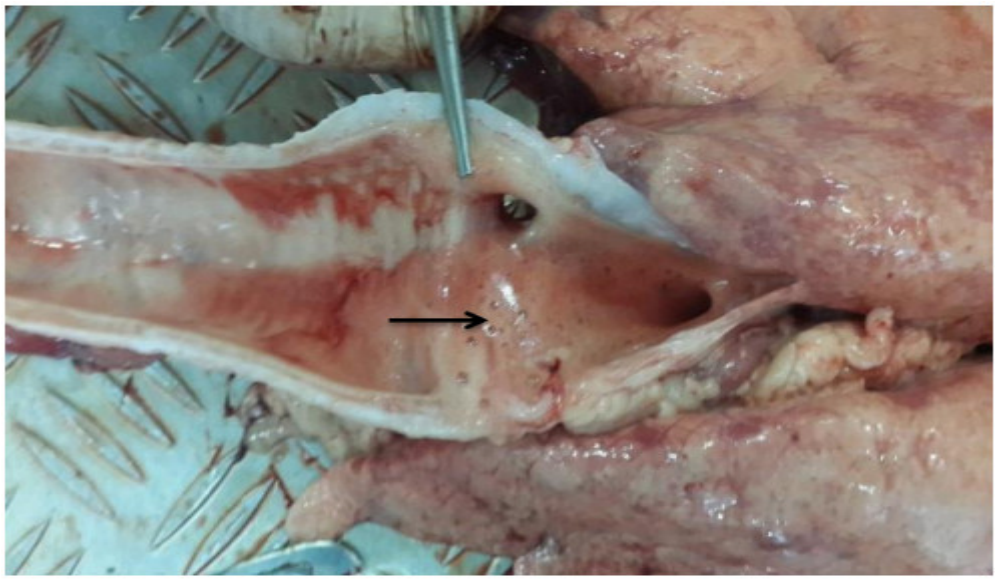

Figure 2. Lung, sheep

Note: A small quantity of foamy fluid is present in the respiratory tract.

3.2. Histopathology

Six out of 189 suspected lung samples showed histopathological OPA lesions, representing 3.17%. The histopathological features of the six affected lungs were uniform, displaying papillary projections of cuboidal to low columnar neoplastic cells within the alveoli and bronchioles (Figure 3). The neoplastic foci were supported by a sparse connective tissue stroma, which showed higher infiltration of mononuclear cells and connective tissue in the atypical form. Swollen and foamy macrophages were found in the alveoli and bronchioles adjacent to the neoplastic lesions (Figure 3).

In one case, despite the presence of similar changes and the infiltration of macrophages and lymphocytes, neutrophils and fibrin casts—typical indicators of the classical form of OPA—were noted in the lumens of the alveoli and bronchi (Figure 4).

4. Discussion

The present study aimed to provide an initial estimate of the prevalence of OPA based on pathological findings in slaughtered sheep. Ovine pulmonary adenocarcinoma is a contagious lung cancer that affects sheep. OPA has been reported in many countries worldwide and is recognized by the Office International des Epizooties (OIE) as a significant disease in the international trade of sheep and sheep products [9]. In classical OPA, a distinctive symptom is the presence of edematous fluids and abundant mucoid secretions in the airways. A key feature of classical OPA is confirmed through a test known as the wheel-barrow test, during which thin, mucoid fluid produced by neoplastic cells in the lungs flows from the nostrils of some animals affected by pulmonary adenomatosis [11, 12].

With no excessive lung fluid, a post-mortem assessment is regarded as the most effective diagnostic method, particularly when no reliable serological assessment is available to detect OPA in live animals [13, 14].

There is no classification regarding the pathological characteristics of OPA, with researchers primarily describing pulmonary lesions, like firm, grayish-white nodules in various lobes and a significant amount of mucoid fluid within the airways [12]. These lesions are attributed to the disease's classic form, which is linked to common clinical symptoms. Conversely, there is no distinct "atypical" morphological type [7].

Atypical OPA appears to be its subclinical variant, typically identified post-slaughter in abattoirs. This form is grossly characterized by solitary or multifocal nodules, often found in the diaphragmatic lobes, which are dry upon being cut, hard, and white. Here, the pathological lesions observed in six affected lung specimens were consistent with the atypical OPA form. Histopathological analysis revealed that the alveoli and bronchioles' basement membrane was lined with cuboidal to columnar epithelial cells, exhibiting papillary or acinar growth patterns. This observation has been documented in the atypical and classic types of the disease [7].

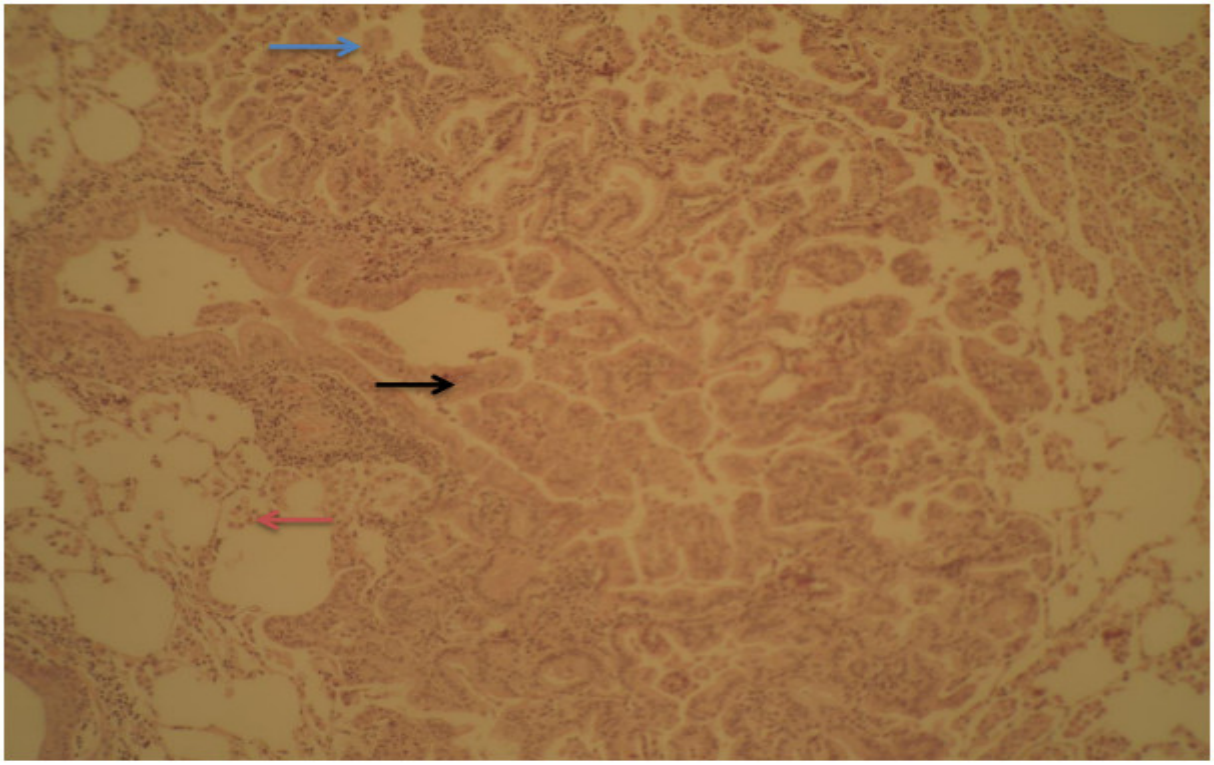

Figure 3. Lung, sheep

Note: Ovine pulmonary adenocarcinoma. Papillary projections of cuboidal to low columnar neoplastic cells in the lumen of the alveoli (black arrow) and bronchioles (blue arrow), respectively. (H&E ×100)

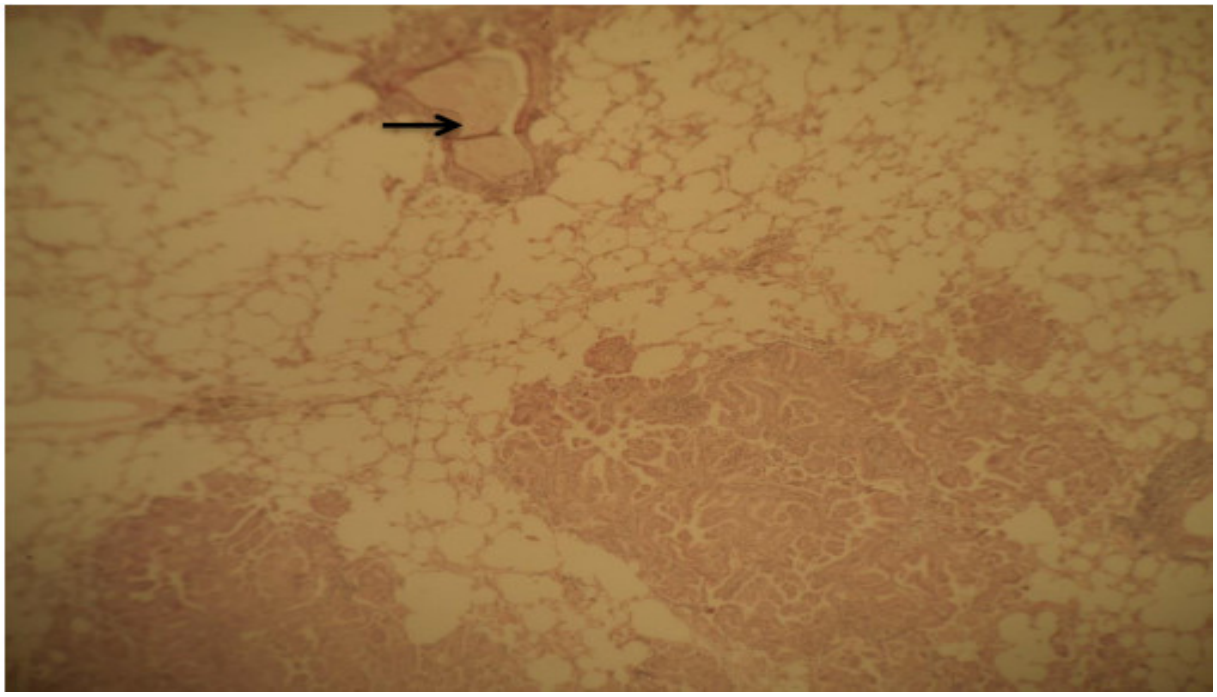

Figure 4. Lung, sheep

Note: Neutrophils and fibrin casts, as a dominant feature of the classic form of OPA, are observed in the bronchial lumen (black arrow). (H&E ×100)

This report is the first to document pulmonary adenomatosis in sheep within Semnan Province. In a study conducted by Khodakaram-Tafti and Razavi (2010) [9] in Fars Province, South Iran, the lungs of 944 sheep were examined, and OPA was identified in 21 sheep (2.22%). They initially selected samples based on the observation of gross lesions, which were later confirmed through histopathological analysis. Kojouri and Karimi (2002) [8] also reported cases of ovine pulmonary adenomatosis in Chahar Mohal Bakhtiari Province, Southwest Iran. Additionally, a similar study in Tabriz found a prevalence of OPA at 2.57% among 468 inspected lungs. The only other reported abattoir study was conducted in Edinburgh, UK, in 1964, where visible OPA lesions were found in 52 out of 280,000 (0.02%) sheep examined. While OPA is generally rare in animals under one year of age, the results of this study indicate that older sheep (two years and above) are more likely to be infected with JSRV, which aligns with previous findings [15].

The classical form of the disease has been documented in numerous nations [6, 16]. These studies established the classical type of pulmonary adenomatosis. In contrast, reports of atypical OPA in the literature are limited. The findings of the current study align with other results [6-9, 17]. De las Heras et al. (1995) [17] stated that such neoplastic forms are classified as "atypical" OPA. Their histopathological characteristics are largely similar to those of the classical form; however, the tumor stroma typically shows significant infiltration by mononuclear inflammatory cells and connective tissue. It has been previously noted that distinguishing between atypical and classical OPA cases is not always straightforward. At times, both disease types can be found in the same lung, and some types exhibit intermediate stages between atypical and classical tumors [7, 9, 16]. This observation aligns with the findings of the current study. In this research, the inflammatory cells identified included monocyte macrophages, lymphocytes, and polymorphonuclear leukocytes. The study noted accumulation and infiltration of mononuclear inflammatory cells, primarily plasma cells, and lymphocytes, along with varying amounts of loose to dense fibrous connective tissue in the neoplastic foci's interstitial areas. These reactive alterations in the tumor stroma are a certain immune reaction from the host rather than a result of concurrent infections [9]. A notable feature of the tumor was the macrophage accumulation in seemingly normal alveoli near the affected ones. This finding is consistent with some studies [17, 15, 7-9].

The immune response to JRSV remains poorly understood. According to Summers et al. (2005) [18], the macrophage influx is the primary local immune reaction observed in OPA. The morphopathological results of OPA in this study support the idea that both classical and atypical types exhibit various manifestations or stages of a "single disease spectrum" [7, 9, 19, 20].

In this research, no tumor metastasis to the mediastinal lymph nodes was detected, which aligns with some earlier reports [21]. However, this finding contrasts with reports of intra- or extra-thoracic metastasis [22, 23, 9].

In contrast to the findings of this study and other reports, Williams and Yates (1988) [15] documented metastasis in the kidneys and mediastinal lymph nodes. Al-Dubaib (2005) [24] and Ortega et al. [25] also reported cardiac and renal metastases of an OPA-like tumor in a goat. The reasons for this discrepancy remain unclear. Considering that OPA tumors can metastasize, and given the ability of OPA tumor cells and their derived cell lines to transplant into nude mice, their nature can be considered neoplastic rather than merely proliferative. Hunter and Munro [23] indicated the classical form to be the predominant type in Scotland, while both forms have been diagnosed in other countries such as Spain. In contrast, the current study found that the atypical OPA form was more prevalent than the classical form. It is challenging to determine whether these two pathological types in natural infections represent different developmental phases of the same disease or if they remain distinct throughout the disease's progression. Furthermore, since the background of the animals in this study was unknown, we do not know whether the immune status of the infected animals influenced the distribution type and pattern of connective tissue proliferation and inflammatory cell infiltration. Given the limited number of studies conducted, it is difficult to determine whether climatic and geographic differences affect the distribution type and pattern of the response against OPA. Conducting more experimental investigations that specify the infection timing and evaluate the animals in different climatic situations could help address some of these questions. The OPA prevalence varies based on sheep breed and flock management practices. However, there has been no research conducted in Iran regarding the prevalence of OPA across different breeds. Additionally, since breeds and farming practices differ among various regions of Iran, it may be challenging to distinguish the effects of breed from those of management. In Semnan Province, northeast Iran, sheep farming is traditional, with practices such as mixing sheep from different flocks and using shared watering facilities, which likely facilitates trans-

mission between flocks. In contrast, other regions of Iran follow different commercial sheep farming practices, leading to variations in both within- and between-flock transmission.

5. Conclusion

The findings of the current study indicate that OPA is common among native sheep breeds in northeastern Iran's Semnan Province. While histopathological and macroscopic methods are effective for diagnosing OPA, molecular investigations provide more reliable confirmation of even small quantities of viral particles in pulmonary secretions and lung tissue. To enhance the efficiency and profitability of the sheep industry in this region, it is recommended to implement measures that could help curb the spread of this virus.

Ethical Considerations

Compliance with ethical guidelines

All the animals in this research were euthanized according to animal protection guidelines approved by the Animal Ethics Committee of Garmsar Branch, Islamic Azad University, Garmsar, Iran.

Data availability

The data that support the findings of this study are available upon request from the corresponding author.

Funding

This research did not receive any grant from funding agencies in the public, commercial, or non-profit sectors.

Authors' contributions

Conceptualization, study design, analysis, data interpretation, and writing the original draft: Keivan Jamshidi; Review and editing: Afshin Zahedi.

Conflict of interest

The authors declared no conflict of interest.

Acknowledgements

The authors thank all the teams who worked on the experiments and provided results during this study.

References

[1] Palmarini M, Fan H. Retrovirusinduced ovine pulmonary adenocarcinoma, an animal model for lung cancer. J Natl Cancer Inst. 2001; 93(21):1603-14. [DOI:10.1093/jnci/93.21.1603] [PMID]

[2] McGavin MD, Zachary JF. Pathologic basis of veterinary disease. Missouri: Mosby & Elsevier; 2007. [Link]

[3] Leroux C, Mornex JF. Retroviral infections in sheep and the associated diseases. Small Rumin. Res. 2008; 76(1-2):68-76. [DOI:10.1016/j.smallrumres.2007.12.010]

[4] Tustin RC. Ovine jaagsiekte. J S Afr Vet Assoc. 1969; 40(1):3-23. [Link]

[5] Bancroft JD, Marilyn G. Theory and practice of histological techniques. Amsterdam: Elsevier Health Sciences; 2008. [Link]

[6] Sharp JM, Angus KW. Sheep pulmonary adenomatosis: Clinical pathological and experimental aspect. In: Petursson G, Hoff-Jorgensen R, editors. Maedi-Visna and related diseases. Developments in Veterinary Virology, vol 10. Boston: Kluwer Academic Publishers; 1990. [DOI:10.1007/978-1-4613-1613-8_9]

[7] García-Goti M, González L, Cousens C, Cortabarría N, Extramiana AB, Minguijón E, et al. Sheep pulmonary adenomatosis: characterization of two pathological forms associated with jaagsiekte retrovirus. J Comp Pathol. 2000; 122(1):55-65. [DOI:10.1053/jcpa.1999.0344] [PMID]

[8] Kojouri, GH, Karimi I. [Sheep pulmonary adenomatosis: A study on prevalence and pathological findings (Persian)]. An Fishries Sci. 2002; 14(4):64-7. [Link]

[9] Khodakaram-Tafti A, Razavi ZA. Morphopathological study of naturally occurring ovine pulmonary adenocarcinoma in sheep in Fars province, Iran. Iran J Vete Res. 2010; 11(2):134-8. [Link]

[10] Wootton SK, Halbert CL, Miller AD. Sheep retrovirus structural protein induces lung tumours. Nature. 2005; 434(7035):904-7. [DOI:10.1038/nature03492] [PMID]

[11] Sharp JM, De las Heras M. Contagious respiratory tumors. In: Martin WB, Aitken ID, editors. Diseases of sheep. Hoboken: Wiley; 2007. [Link]

[12] Kycko AN, Jasik AG, Reichert MI. Detection of jaagsiekte sheep retrovirus in respiratory tract fluid and lung tissue of experimentally infected lambs. Bull Vet Inst Pulawy. 2008; 52:9-13. [Link]

[13] Ortín A, Minguijón E, Dewar P, García M, Ferrer LM, Palmarini M, et al. Lack of a specific immune response against a recombinant capsid protein of Jaagsiekte sheep retrovirus in sheep and goats naturally affected by enzootic nasal tumour or sheep pulmonary adenomatosis. Vet Immunol Immunopathol. 1998; 61(2-4):229-37. [DOI:10.1016/S0165-2427(97)00149-9] [PMID]

[14] Summers C, Neill W, Dewar P, Gonzalez L, van der Molen R, Norval M, et al. Systemic immune responses following infection with Jaagsiekte sheep retrovirus and in the terminal stages of ovine pulmonary adenocarcinoma. J Gen Virol. 2002; 83(Pt 7):1753-7. [DOI:10.1099/0022-1317-83-7-1753] [PMID]

[15] William DG, Yates DVM. Pulmonary adenomatosis. In: Thomson, RG, Decker BC, editors. Special veterinary pathology. Philadelphia: Decker Inc., 1988.

[16] Al-Hizab FA, Abdelsalam EB. Adenomatous lesion in a pneumonic lung of a local indigenous Saudi goat. Pak J Biol Sci. 2005; 4:542-5. [DOI:10.3923/pjbs.2005.542.545]

[17] De las Heras M, Minguinjon E, Ferrer LM, Perez V, Bolea R. Adenomatosis pulmonary ovina (Jaagsiekte): Celulas que infiltran el tumor y modificaciones en ganglios linfaticos regionales. Med Vet. 1995; 12:32-6. [Link]

[18] Summers C, Norval M, De Las Heras M, Gonzalez L, Sharp JM, Woods GM. An influx of macrophages is the predominant local immune response in ovine pulmonary adenocarcinoma. Vet Immunol Immunopathol. 2005; 106(3-4):285-94. [DOI:10.1016/j.vetimm.2005.03.006] [PMID]

[19] Sasani F, Khaki F, Gharaghozlou MJ. Identification of Atypic and classic, mucinous and nonmucinous forms of ovine pulmonary adenocarcinoma (OPA) and TTF1 marker expression. Iran J Vet Med. 2017; 11(3):279-87. [Link]

[20] Mahaki, ME, Sadeghian Chaleshtori S, Azarabad H, Shokri n A. Omental lipoma in a slaughtered lamb. Iran J Vet Med. 2024; 18(4):619-24. [DOI:10.32598/ijvm.18.4.1005410]

[21] Sarkar CR, Chakrabaril A, Deb S, Nandy SN. Pulmonary adenomatosis (jaagsiekte) of sheep in West Bengal. Indian Vet J. 1988; 65(4):353-4. [Link]

[22] Nobel TA, Neumann F, Klopfer U. Histological patterns of the metastases in pulmonary adenomatosis of sheep (jaagsiekte). J Comp Pathol. 1969; 79(4):537-40. [DOI:10.1016/0021-9975(69)90074-7] [PMID]

[23] Hunter AR, Munro R. The diagnosis, occurrence and distribution of sheep pulmonary adenomatosis in Scotland 1975 to 1981. Br Vet J. 1983; 139(2):153-64. [DOI:10.1016/S0007-1935(17)30539-0] [PMID]

[24] Al-Dubaib MA. Renal and cardiac metastases of jaagsiekte-like tumour in a goat. Small Rum Res. 2005; 58(1):75-8. [DOI:10.1016/j.smallrumres.2004.09.009]

[25] Ortega J, Corpa JM, Castillo D, Murphy BG. Pathological spectrum of ovine pulmonary adenocarcinoma in small ruminants: A focus on the mixed form. Animals (Basel). 2023; 13(18):2828. [DOI:10.3390/ani13182828] [PMID]