Archives of Razi Institute Journal
"Arch. Razi Inst."

Journal Homepage: https://archrazi.areeo.ac.ir/

Research Paper

Study of the Incidence of Pregnancy Toxemia in a Colony of Pirbright Guinea Pigs (*Cavia porcellus*)

Roozbeh Fallahi[1*], Mojtaba Moharrami[1], Mohammad Eslam Panah[2], Mahnaz Jafari Sohi[1]

1. Department of Research, Breeding and Production of Laboratory Animals, Razi Vaccine and Serum Research Institute, Agricultural Research Education and Extension Organization (AREEO), Karaj, Iran.
2. Department of Pathology, Razi Vaccine and Serum Research Institute, Agricultural Research Education and Extension Organization (AREEO), Karaj, Iran.

Use your device to scan and read the article online

How to cite this article Fallahi R, Moharrami M, Eslam Panah M, Jafari Sohi M. Study of the Incidence of Pregnancy Toxemia in a Colony of Pirbright Guinea Pigs (*Cavia porcellus*). Archives of Razi Institute Journal. 2026; 81(3):757-766. https://doi.org/10.32598/ARI.81.3.4007

https://doi.org/10.66224/ARI.81.3.4007

Article info:
Received: 18 Dec 2025
Accepted: 25 Jan 2026
Published: 01 May 2026

Keywords:
Acidosis, Facility, Ketosis, Laboratory animals, Syndrome

ABSTRACT

Introduction: Guinea pigs are susceptible to pregnancy toxemia. This disorder is a metabolic disease.

Materials & Methods: A colony of laboratory guinea pigs was monitored for the occurrence of pregnancy toxemia at a breeding center. Blood and urine samples were collected from suspected cases for measurement of pH, glucose, triglycerides, total protein, ALP, creatinine and ketone bodies. Following necropsy, samples from internal organs were collected for bacterial culture, and tissues were prepared for histopathological examination. The diet used was also sent to the laboratory for chemical and toxicological analysis.

Results: Only five pregnant female guinea pigs showed clinical signs suspicious of pregnancy toxemia. At necropsy, the stomach and cecum were empty, and the liver was large and pale. On cross-section, the kidneys appeared pale. In the histological section of the liver, balloon cells and an abundance of fat vacuoles were observed, and in the kidney, foci of tubular coagulation necrosis were observed. The results of the cultures were negative for opportunistic and pathogenic bacterial agents. Blood total protein, pH and glucose decreased, and creatinine , ALP, and ketone bodies increased. In urine, the pH changed from completely alkaline to acidic, and ketone bodies increased sharply. Chemical and microbiological analysis of the diet did not detect any significant changes in nutrients. In addition, it was negative for *salmonella* and *shigella*, and the aflatoxin content was within the permissible range.

Conclusion: In conclusion, it is recommended to replace old female guinea pigs with young females in the colony to prevent the occurrence of this syndrome.

*** Corresponding Author:**
Roozbeh Fallahi, Associate Professor.
Address: *Department of Research, Breeding and Production of Laboratory Animals, Razi Vaccine and Serum Research Institute, Agricultural Research Education and Extension Organization (AREEO), Karaj, Iran.*
Tel: *+98 (912) 5405972*
E-mail: *r.fallahi@rvsri.ac.ir*

Copyright © 2026 The Author(s);
This work is licensed under a Creative Commons Attribution-NonCommercial 4.0 International license (https://creativecommons.org/licenses/by-nc/4.0/).
Noncommercial uses of the work are permitted, provided the original work is properly cited.

1. Introduction

Like humans, guinea pigs are susceptible to pregnancy toxemia [1]. Pregnancy toxemia is a metabolic disease [1]. Factors contributing to its development include aging, poor diet (lack of carbohydrates and high-fat intake), obesity, malnutrition, non-specific or undefined stressors such as handling, transportation, etc. a large and number of fetuses, and genetic factors [1-5]. Obesity and malnutrition are critical predisposing factors [1, 2]. Although the disease is most common during pregnancy, it can also occur in male guinea pigs as a related metabolic disease called ketosis [1]. Pregnancy toxemia usually occurs in pregnant guinea pigs, especially obese ones, during the last two weeks of pregnancy or 7–10 days after parturition [2, 6]. Female guinea pigs in their first pregnancy and older females that have had multiple pregnancies are more affected by this disorder [1].

Two main mechanisms contribute to pregnancy toxemia in guinea pigs. One is a metabolic disorder and the other is a cardiovascular disorder or circulatory or toxic form [2, 3]. In both forms, the clinical signs are similar and are mainly seen in late pregnancy [2, 3]. The metabolic form, also called ketosis, typically occurs in pregnant guinea pigs, especially obese ones, at 2-3 weeks of gestation or 7-10 days after parturition [3, 7]. Obese male guinea pigs may also develop the metabolic form, or ketosis under the influence of other predisposing factors [3]. In the circulatory or toxic form, the large number and size of fetuses cause excessive uterine volume and pressure on the caudal aorta, renal, and hepatic vessels, and may lead to ischemia in the placental and uterine vessels due to decreased blood flow in the uterine vessels, along with thrombocytopenia due to hemorrhage and necrosis in the placenta, which ultimately leads to acute ketosis, coma, and death [2, 3].

In terms of clinical signs, guinea pigs with pregnancy toxemia usually become calm and lethargic at first. Eating and drinking stops. The body hair becomes ruffled, and the animal may suffer from hair loss due to trichophagia (hair pulling due to stress). Another sign is weight loss. After 48 hours from the onset of clinical signs, the animal becomes dyspneic and falls to the ground, eventually falling into a coma and dying 5-6 days after the onset of clinical signs. Similar symptoms are seen in obese male guinea pigs with metabolic ketosis. The urine of healthy guinea pigs is pale yellow and clear to slightly cloudy, whereas in pregnancy toxemia, due to dehydration, the animal becomes very dehydrated and the urine becomes very concentrated and dark yellow to deep orange in color [2, 3, 6, 8].

Necropsy findings are similar in both forms, but in the circulatory form of pregnancy toxemia, the changes are more severe than in the metabolic form [7]. The stomach and cecum are empty of food and contents. The liver is enlarged, pale or yellow, and may exhibit focal areas of necrosis. The adrenals are enlarged with petechial and ecchymotic hemorrhages. On cross-section, the kidneys appear pale and may present subcapsular hemorrhages. The placental attachment to the uterus is easily torn and has petechial and ecchymotic hemorrhages [1-3, 9, 10]. In the histological section of the liver of a guinea pig with pregnancy toxemia, an abundance of fat vacuoles is visible. Histopathology also shows ischemia between the placenta and uterus, resulting from excessive pressure on the caudal aorta exerted by the fetuses. Other histopathological findings include hemorrhage and necrosis in the placenta, as well as in the renal tubules and, to a lesser extent, in the adrenal glands and lungs [2].

The diagnosis of pregnancy toxemia is based on clinical signs in pregnant or obese animals [1]. Biochemical changes in blood and urine also help considerably in diagnosing the disease. Urine becomes clear and acidic. Urine pH decreases from normal alkaline (8-9) to acidic (5-6) and shows increased ketones and protein in urine (proteinuria and ketonuria). In the blood, there is a decrease in glucose (hypoglycemia), an increase in fat (hyperlipidemia) (mostly in the form of increased triglycerides), an increase in creatinine and ALP enzyme, and an increase in potassium ions (hyperkalemia) [1-3, 11, 12]. Once clinical signs are seen in affected guinea pigs, treatment is ineffective. Administration of fluids and Ringer's saline, calcium gluconate, 5% glucose, and corticosteroids have little effect. In general, prevention of pregnancy toxemia is more successful. Avoidance of environmental stressors, feeding a balanced and consistent diet, prevention of obesity by limiting food intake, maintaining animals at appropriate body weights (approximately 450-500 g) in the colony, and prevention of opportunistic infections are recommended. The aforementioned clinical, necropsy, and histopathological signs, especially in late pregnancy, acidification of urine, and other biochemical changes, as well as the failure to diagnose infectious diseases such as salmonellosis, bordetellosis, etc. and the poor response of affected animals to treatment methods, help in the differential and definitive diagnosis of this disease [1, 2, 8, 13].

2. Materials and Methods

2.1. Study population and conditions

The colony of Pirbright laboratory guinea pigs, consisting of 210 males and 420 females, along with 1350 growing offspring, were monitored for the possibility of pregnancy toxemia over a one-year period (from January 2014 to January 2015). The animals were fed standard laboratory guinea pig pellets and water ad libitum. The breeding system was conventional, using polycarbonate shoebox-type cages (type 4), with two females and one male per cage. Post-weaning, pups were separated at a body weight of 200 g, sexed, and transferred to separate cages. Sterilized aspen wood shavings were used as bedding and replaced twice weekly. The breeding room was maintained at 22–24 ˚C, 45–55% humidity, with 8–10 air exchanges per hour (3-minute cycles), a 12:12-hour light/dark cycle, and light intensity below 325 Lux [10]. During the study period, blood and urine samples were collected from a number of suspected cases, in accordance with the principles of ethical work with laboratory animals, to measure pH, glucose, triglycerides, total protein, ALP, creatinine, and ketone bodies (β-hydroxybutyrate). After euthanasia and necropsy, bacterial cultures were performed from the liver, lungs, kidneys, and intestines on blood agar, MacConkey agar, and tryptic soy broth media. Tissue samples from the lungs, liver, and kidneys were also collected for histopathological examination and fixed in 10% formaldehyde solution. After the required time for fixation, 5-micrometer tissue sections were cut from paraffin-embedded blocks, stained with Hematoxylin and Eosin (H&E), and examined microscopically. Carcasses of euthanized guinea pigs were disposed of using an infectious waste disposal system (Hydroclave). Also, the diet samples were sent to the laboratory for chemical and toxicological analysis.

3. Results

3.1. Morbidity rate and clinical signs

During a one-year study, in a guinea pig colony, only five pregnant female guinea pigs showed clinical signs suspicious of pregnancy toxemia. By examining the breeding history, it was determined that all of them were at least in their third or fourth pregnancy, and the symptoms mentioned were observed in them a few days before to a few days after parturition. Two of them died approximately 7-10 days after the onset of clinical symptoms. From three guinea pigs with acute clinical symptoms that had gone into a coma, the blood and urine samples were collected after anesthesia and necropsy. Clinical symptoms included lethargy, anorexia, immobility, ruffled hair coat, hair loss, and ultimately falling to the ground, coma, and death (Figure 1).

3.2. Necropsy findings

In all specimens, the number of fetuses was at least 3-4 and their size appeared relatively large. The stomach and cecum were empty, and the liver appeared enlarged and pale. On cross-section, the kidneys appeared pale. In some specimens, the adrenal glands were enlarged and exhibited petechial and ecchymotic hemorrhages, and the placental attachment to the uterus was easily detached and showed hemorrhages (Figures 2, 3 and 4).

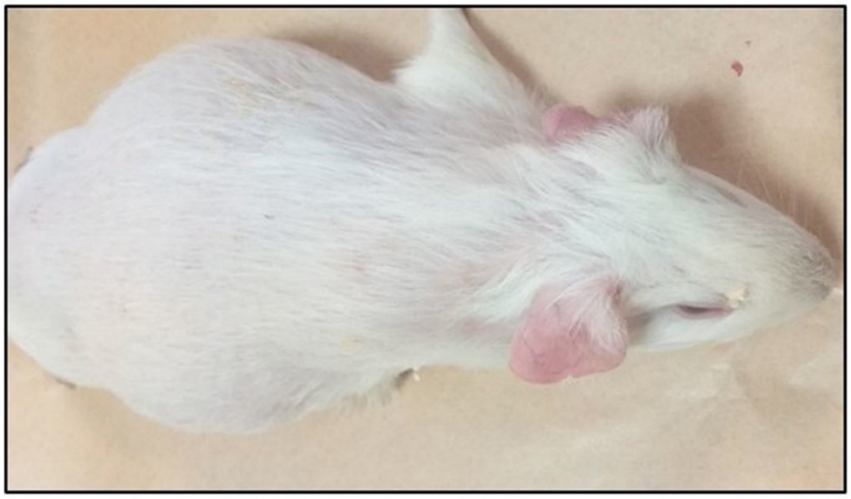

Figure 1. Dead guinea pig in late pregnancy with hair loss

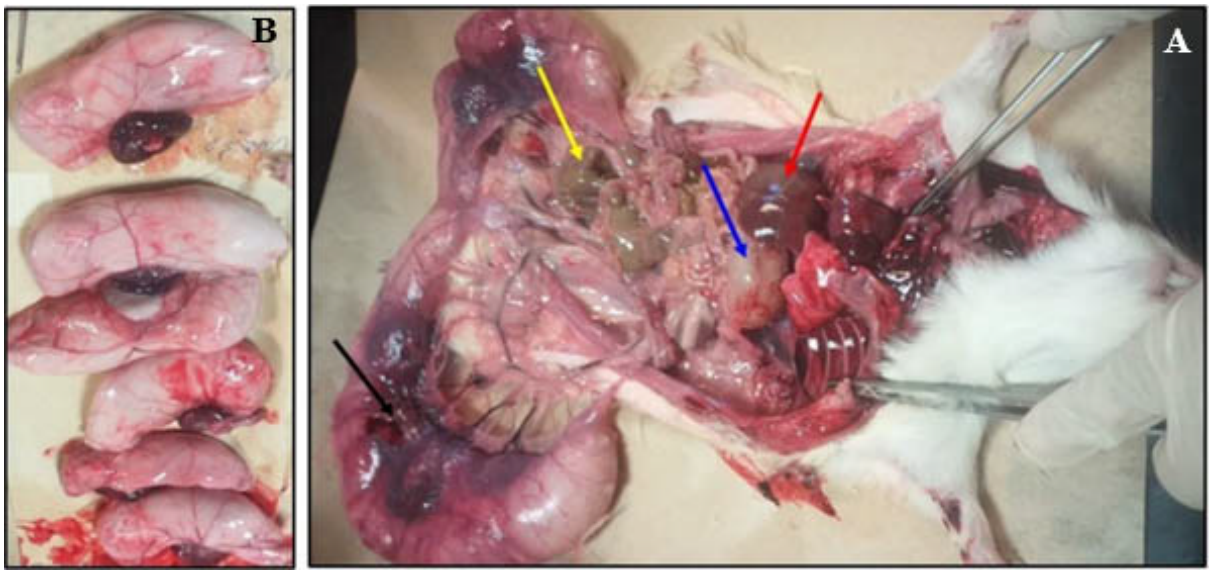

Figure 2. A) Empty stomach (blue arrow) and intestines, especially cecum (yellow arrow), pale liver (red arrow) and intrauterine bleeding (black arrow); B) 6 fetuses, relatively large

3.3. Histopathology

In the histological examination of the liver of guinea pigs with pregnancy toxemia, balloon cells and an abundance of micro- and macrovesicular fat vacuoles were observed, and in the kidney, intertubular edema with focal tubular coagulation necrosis was observed (Figures 5 and 6).

3.4. Bacterial cultures and measurement of blood and urine biochemical factors

The results of bacterial cultures of samples prepared from the liver, lungs, kidneys, and intestines on blood agar, MacConkey agar, and tryptic soy broth media were negative for opportunistic and pathogenic bacterial agents such as *Salmonella*, *Bordetella*, etc. The biochemical factors measured in the blood and urine of guinea pigs with pregnancy toxemia and their normal values are shown in Table 1.

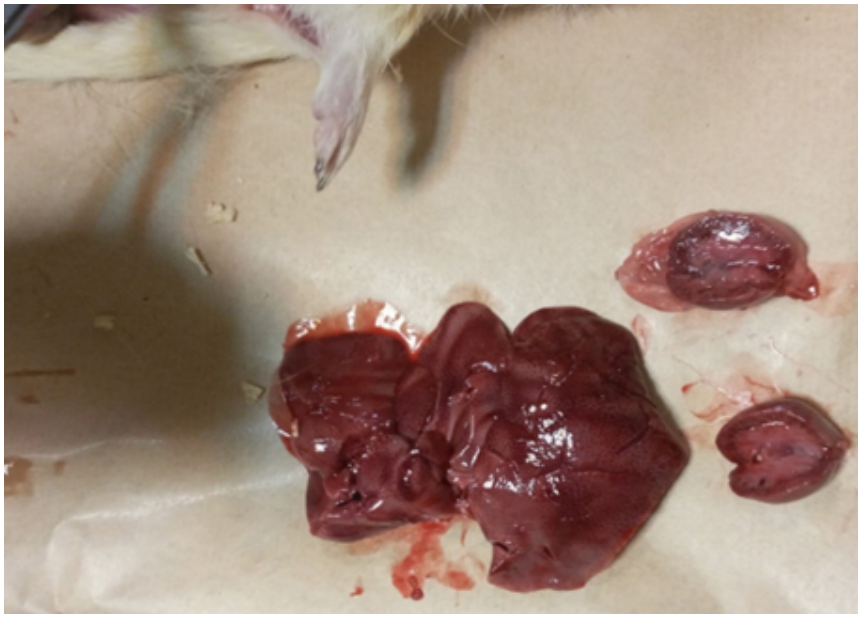

Figure 3. Pale kidneys and a relatively large, pale liver with swollen edges in a guinea pig that died of pregnancy toxemia

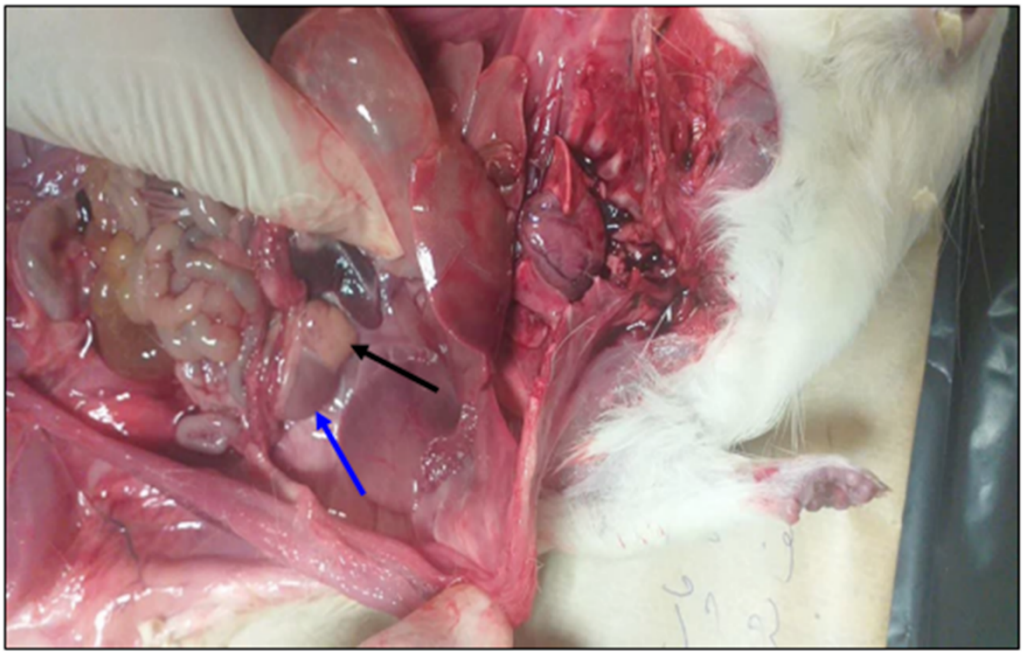

Figure 4. Pale kidney (blue arrow) and enlarged adrenal with petechial hemorrhages (black arrow)

3.5. Diet analysis

In the chemical and microbiological analysis of the guinea pig diet, no significant changes in nutrients were detected, especially in terms of carbohydrate deficiency or fat excess. In addition, the diet was negative for *Salmonella* and *Shigella*, and the aflatoxin content was within the permissible range. The nutritional requirements and diet analysis are shown in Table 2.

4. Discussion

Many mammalian species, including humans, rabbits, dogs, ruminants, and guinea pigs, develop pregnancy toxemia in late pregnancy or early lactation, although their characteristics are different [2, 7, 8]. It is more common in guinea pigs than in rabbits [7, 15-17]. In guinea pigs, this syndrome closely resembles pre-eclampsia in humans. The disease can be induced experimentally in pregnant or non-pregnant guinea pigs by reducing the

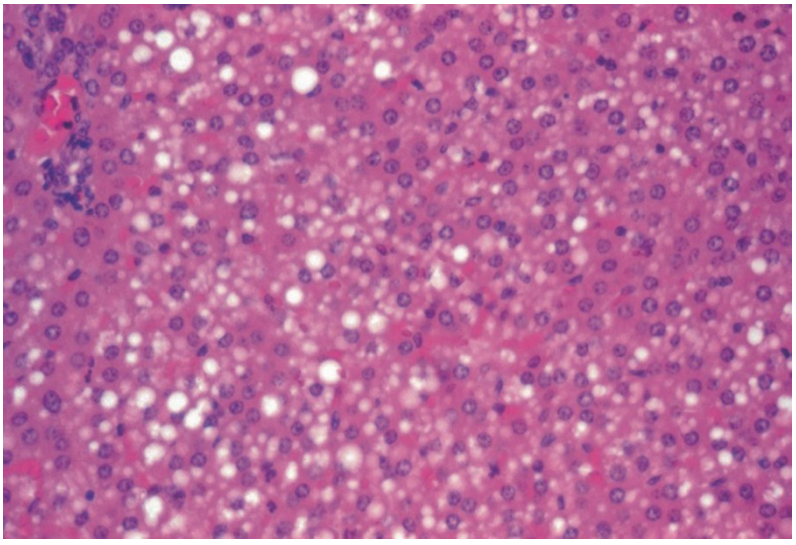

Figure 5. Fatty liver with balloon cells and abundance of micro- and macrovesicular fat vacuoles (white dots) in a section of liver tissue from a guinea pig that died due to pregnancy toxemia

Table 1. Biochemical factors measured in the blood and urine of guinea pigs with pregnancy toxemia and their normal values [1, 6, 12]

Biochemical Factors	In the Blood of Affected Guinea Pigs	Normal Range in Blood	In the Urine of Affected Guinea Pigs	Normal Range in Urine
pH	6.9-7.1	7.35-7.45	5-5.8	8-9
Ketone body (beta hydroxybutyrate) (mmol/L)	1.12-1.17	<0.5	+++	0
Glucose (mg/dL)	18-20	60-120	Not measured	
Triglycerides (mg/dL)	3000-3550	20-90	Not measured	
Total protein (g/dL)	4-4.2	5.5-6.5	Not measured	
ALP (IU/L)	1580-1992	70-200	Not measured	
Creatinine (mg/dL)	2.5-3.1	0.6-2.2	Not measured	

amount of food, and in obese males and females by occluding the uterine arteries and disrupting uteroplacental blood flow, leading to placental hypoxia, inflammation, or maternal endothelial dysfunction. Therefore, this animal is used as a model for pregnancy toxemia of in humans, called pre-eclampsia [18-21]. The circulatory form of pre-eclampsia develops in guinea pigs in late pregnancy. At this time, approximately 50% of body weight is due to the fetal mass. In this situation, pressure on the caudal aorta causes uteroplacental ischemia and renal vascular disorder. Blood flow in the uterus decreases by up to 30%, leading to placental infarction and intravascular coagulation [7]. In the last two weeks of pregnancy and up to one week after parturition, the energy requirement to maintain the fetuses and support growth and lactation increases, and the guinea pig is forced to catabolize fat to provide energy. Because the body metabolizes fats and proteins in the absence of glucose, it produces substances called ketone bodies. These are used instead of glucose and provide energy for the body. Ketone bodies are produced by the liver. The two main ketone bodies are acetoacetate and β-hydroxybutyrate. The third ketone body is acetone, which is not present in large quantities. If ketone bodies increase in the blood and urine, the animal is in ketosis. Ketone bodies are acidic, and the consequence of ketosis is acidosis (a decrease in the body pH), which causes damage to body tissues, especially the central nervous system. In addition, the enzyme phosphofructokinase is inhibited, which is dangerous for cells due to its role in glycolysis [9, 20, 22, 23].

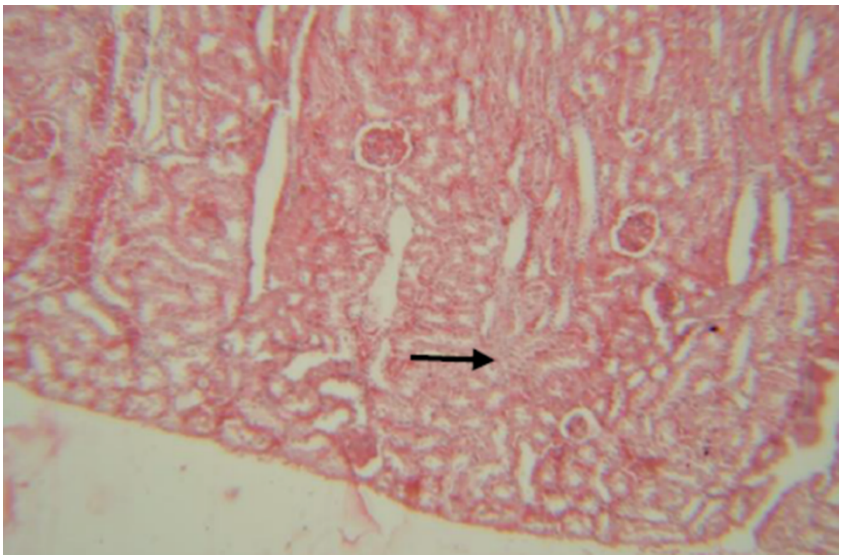

Figure 6. Intertubular edema with focal tubular coagulative necrosis in the kidney of a guinea pig with pregnancy toxemia (H&E staining, 32x magnification)

Table 2. Nutritional requirements and diet analysis of guinea pigs under investigation [14]

Material	Guinea Pig Nutritional Requirements	Analysis of Guinea Pig Diet
Crude protein (%)	16-18	18.51
Energy (Kcal/lb)	900	886
Crude fat (%)	2.4	3.36
Crude fiber (%)	15	20.31
Calcium (%)	0.8	0.91
Phosphorus (%)	0.4	0.33
Sodium (%)	0.05	0.27
Chloride (%)	0.05	0.23
Methionine (%)	0.6	0.32
Lysine (%)	0.84	0.29
Arginine (%)	1.2	1.11
Histidine (%)	0.36	0.46
Isoleucine (%)	0.6	0.94
Leucine (%)	1.1	1.44
Phenylalanine (%)	1.1	0.90
Threonine (%)	0.6	0.74
Tryptophan (%)	0.18	0.24
Valine (%)	0.84	0.93
Vit A (mg/Kg)	6.6	1.58
Vit D3 (IU/Kg)	0.025	0.004
Vit E (mg/Kg)	26.7	74
Vit C (mg/Kg)	200	145
Vit B7 (biotin) (mg/Kg)	0.2	0.3
Vitamin B6 (pyridoxine) (mg/kg)	2-3	6.4
Vitamin B2 (riboflavin) (mg/kg)	3	5
Choline (mg/kg)	1800	1340
Salmonella culture (/25gr)	Negative	Negative
Escherichia coli (CFU/gr)	Negative	Negative
Total aflatoxin (ppb)	5-20	1.9

In this study, by measuring biochemical factors in the blood and urine of guinea pigs suspected of pregnancy toxemia, all of whom had a history of at least three parturitions, it was determined that the blood showed a decrease in total protein and pH, a severe decrease in glucose, an increase in creatinine, and a marked increase in Alkaline phosphatase (ALP) enzyme and ketone bodies (β-hydroxybutyrate). In the urine, a change in pH from completely alkaline to strongly acidic and a very sharp increase in the amount of ketone bodies were observed, all of which are characteristics of pregnancy toxemia. Considering the clinical and necropsy symptoms, histopathological changes in liver and kidney tissues, and the lack of bacterial culture of opportunistic and pathogenic organisms, the diagnosis of this disease is confirmed. Given the absence of signs of obesity in the guinea pig colony and the absence of disease in male or non-pregnant females, as well as the appropriateness of the results of diet analysis, and the fact that during the investigation, the presence of environmental stressors, transportation conditions, and inappropriate handling were not detected, the reason for the occurrence of this syndrome in the colony could be the high age of the pregnant guinea pigs and the relatively large number of fetuses or their large size in the breeding females in the third or fourth pregnancies onwards. Given the low incidence of this syndrome in the colony (0.8%), it is concluded that the role of genetic factors is also negligible.

5. Conclusion

It is recommended that, to prevent the occurrence of pregnancy toxemia from the third parturition onwards, these animals should be replaced with young females in the colony so that the effect of increasing age and intolerance of heavy pregnancies in the occurrence of this syndrome is completely eliminated.

Acknowledgements

The authors thank all the people who provided advice and assistance in this study.

Compliance with ethical guidelines

The present study was conducted in accordance with the guidelines set by the Animal Ethics Committee of Razi Vaccine and Serum Research Institute, and all experiments were carried out in accordance with relevant guidelines and regulations.

Funding

This study was supported by Razi Vaccine and Serum Research Institute, Karaj, Iran.

Authors' contributions

Conceptualization, study design, data Acquisition, and writing the original draft: Roozbeh Fallahi; Necroposy and sample preparation: Mahnaz Jafari Sohi; Experiments and data interpretation: Mohammad Eslam Panah and Roozbeh Fallahi; Review and editing: Mojtaba Moharrami, Roozbeh Fallahi.

Conflict of interest

The authors declared no conflict of interest.

Data availability

The data that support the findings of this study are available upon request from the corresponding author.

References

[1] Clemons DJ, Seeman JL. The laboratory guinea pig. Boca Raton: CRC Press; 2011. [DOI:10.1201/b12886]

[2] Fox JG, Anderson LC, Otto GM, Pritchett-Corning KR, Whary MT. Laboratory animal medicine. 3rd ed. Cambridge: Academic Press; 2015. [Link]

[3] Hrapkiewicz K, Colby L, Denison P. Clinical laboratory animal medicine. 4th ed. Ames (IA): Wiley Blackwell; 2013. [Link]

[4] Quesenberry KE, Orcutt CJ, Mans C, Carpenter JW. Ferrets, rabbits, and rodents: Clinical medicine and surgery. Missouri: Elsevier, Inc; 2021. [Link]

[5] Garner-Richardson V. Guinea pig nutrition. Vet Nurse. 2012; 3(5):274-82. [DOI:10.12968/vetn.2012.3.5.274]

[6] Golledge H, Richardson C. The UFAW handbook on the care and management of laboratory and other research animals. 9th ed. Hoboken (NJ): Wiley-Blackwell; 2024. [Link]

[7] Harkness JE, Wagner JE. Biology and medicine of rabbits and rodents. Philadelphia, Pa: Williams and Wilkins; 2010. [Link]

[8] Mitchell MA, Tully TN. Manual of exotic pet practice. Philadelphia: Saunders Elsevier; 2009. [Link]

[9] Oglesbee BL. Blackwell's five-minute veterinary consult: Small mammal. Hoboken: Wiley Blackwell; 2024. [Link]

[10] Foley EJ. Toxemia of pregnancy in the guinea pig. J Exp Med. 1942; 75(5):539-46. [DOI:10.1084/jem.75.5.539] [PMID]

[11] Winter Park Veterinary Hospital. Guinea pig diseases and conditions requiring veterinary care. Winter Park (FL): Winter Park Veterinary Hospital; 2024. [Link]

[12] Cernochova H, Hundakova A, Bardi E, Knotek Z. Biochemical profile of urine in guinea pigs (Cavia porcellus). Vet Med. 2020; 65 (10):445-50. [DOI:10.17221/32/2020-VETMED]

[13] Noonan D. The Guinea pig (Cavia porcellus). ANZCCART News. 1994; 7(3):1-8. [Link]

[14] National Research Council. Nutrient requirements of laboratory animals. 4th rev ed. Washington (DC): National Academy Press; 1995. [Link]

[15] Schmid NS, Clauss M, Hetzel U, Riond B, Bochmann M, Hatt JM. Development, diagnosis and therapy of ketosis in non-gravid and non-lactating guinea pigs. BMC Vet Res. 2020; 16(1):41. [DOI:10.1186/s12917-020-2257-2] [PMID]

[16] Greene HS. Toxemia of pregnancy in the rabbit: I. Clinical manifestations and pathology. J Exp Med. 1937; 65(6):809-32. [DOI:10.1084/jem.65.6.809] [PMID]

[17] Lorenz MD, Coates JR, Kent M. Systemic or Multifocal Signs. In: Lorenz MD, Coates JR, Kent M, editors. Handbook of Veterinary Neurology. Amsterdam: Elsevier; 2011. [DOI:10.1016/B978-1-4377-0651-2.10015-3]

[18] Bielohuby M, Menhofer, D, Kirchner H, Stoehr BJM, MiilIer TD, Stock P, et al. Induction of ketosis in rats fed low-carbohydrate, high-fat diets depends on the relative abundance of dietary fat and protein. Am J Physiol Endocrinol Metab. 2011; 300(1): E65-76 [DOI:10.1152/ajpendo.00478.2010] [PMID]

[19] Aguilera N, Salas-Pérez F, Ortíz M, Álvarez D, Echiburú B, Maliqueo M. Rodent models in placental research. Implications for fetal origins of adult disease. Anim Reprod. 2022; 19(1):e20210134. [DOI:10.1590/1984-3143-ar2021-0134] [PMID]

[20] Gatford KL, Andraweera PH, Roberts CT, Care AS. Animal models of preeclampsia: Causes, consequences, and interventions. Hypertension. 2020; 75(6):1363-81. [DOI:10.1161/HYPERTENSIONAHA.119.14598] [PMID]

[21] Sakowicz A, Bralewska M, Kamola P, Pietrucha T. Reliability of rodent and rabbitmodels in preeclampsia research. Int J Mol Sci. 2022; 23(22):14344. [DOI:10.3390/ijms232214344] [PMID]

[22] Specialty Feeds. High energy guinea pig (GPHK5): Diet SF00-210. Glen Forrest (WA): Specialty Feeds; 2023. [Link]

[23] Inaba T, Wakisaka Y. [A reproductive study of Weiser-Maples guinea pigs (Japanese)]. Jikken Dobutsu. 1992; 41(2):139-51. [DOI:10.1538/expanim1978.41.2_139] [PMID]

This Page Intentionally Left Blank