

1 **Zoonotic Parasites in Shelter Cats: Microscopy and Molecular Evidence of**  
2 ***Toxoplasma gondii* in Bogor, Indonesia**

3  
4 **Sekar Pratiwi<sup>1</sup>, Ika Puspa Sari<sup>2\*</sup>, Agnes Kurniawan<sup>2</sup>**

5  
6 **<sup>1</sup>Master's Programme in Biomedical Sciences, Faculty of Medicine,**  
7 **Universitas Indonesia, Jakarta 10430, Indonesia**

8 **<sup>2</sup>Department of Parasitology, Faculty of Medicine, Universitas**  
9 **Indonesia, Jakarta 10430, Indonesia**

10  
11 **\*Corresponding author: Ika Puspa Sari**  
12 **Dept of Parasitology, Faculty of Medicine, Jalan Salemba Raya No.6**  
13 **Universitas Indonesia, Jakarta, Indonesia, 10430**  
14 **email:[ika.puspa@ui.ac.id](mailto:ika.puspa@ui.ac.id)**

15  
16 **ABSTRACT**

17  
18 **Introduction:** Cats serve as definitive hosts for several zoonotic parasites,  
19 most notably *Toxoplasma gondii*, which can contaminate the environment  
20 with infective oocysts and pose significant risks to public health. Shelter  
21 populations, often composed of stray, rescued, and previously owned cats,  
22 represent an important reservoir of infection due to their diverse backgrounds  
23 and variable health conditions.

24 **Material and Methods:** In this study, a total of 156 fecal samples were  
25 collected from shelter cats in Bogor, Indonesia, comprising 102 adults and 54  
26 kittens. Samples were examined using direct microscopy, modified Ziehl–  
27 Neelsen (MZN) staining, and nested PCR targeting the 5'-SAG2 and GRA7  
28 genes. Statistical analysis was performed using the Chi-Square test to  
29 evaluate associations between age and parasite prevalence.

30 **Results:** Overall, intestinal parasites were detected in 25.64% of samples.  
31 Hookworms were the most frequently identified (10.25%), followed by *T.*  
32 *gondii* oocysts (9.61%), *Toxocara* spp. (5.12%), and *Cystoisospora* spp.  
33 (0.64%). The prevalence of *T. gondii* oocysts was significantly higher in  
34 kittens compared to adults ( $p < 0.05$ ), underscoring the role of younger cats  
35 in environmental contamination. Of the 15 microscopy-positive samples,  
36 molecular confirmation identified four positives for the 5'-SAG2 gene and  
37 two for the GRA7 gene, thereby validating the presence of *T. gondii* and  
38 reducing the likelihood of misidentification with morphologically similar  
39 protozoa.

40 **Conclusion:** These findings highlight shelter cats, particularly kittens, as an  
41 important source of zoonotic parasites. The integration of parasitological and  
42 molecular methods enhances detection accuracy and provides a more reliable  
43 assessment of infection dynamics. Strengthened surveillance and targeted

44 control strategies are essential to mitigate environmental contamination,  
45 reduce zoonotic transmission, and protect both animal and human health.

46  
47 Keywords: microscopic examination; molecular detection; shelter cats;  
48 *Toxoplasma gondii*; zoonotic parasites

## 50 1. Introduction

51 Cats are among the most popular companion animals worldwide, resulting in close and frequent  
52 interactions with humans. The growth of the human population has contributed to increasing numbers  
53 of pet cats as well as expanding stray populations [1]. Stray cats are particularly common in urban  
54 and suburban areas, where high human density facilitates close contact between cats and people. As  
55 definitive hosts for several parasites, including *Toxocara*, *Giardia*, *Cryptosporidium*, *Cystoisospora*,  
56 hookworms, and *Toxoplasma gondii*, cats can shed infective stages into the environment,  
57 contaminating soil, water, and food sources, and thereby posing a risk of zoonotic transmission [2].  
58 *Toxoplasma gondii* is an obligate intracellular protozoan responsible for toxoplasmosis, a globally  
59 prevalent zoonotic disease. It can infect humans and other warm-blooded animals, with significant  
60 consequences for livestock such as sheep, where infection may cause abortion and economic losses.  
61 Approximately one-third of the global human population is estimated to be infected, often  
62 asymptotically. Transmission occurs through ingestion of contaminated food or water, vertical  
63 transmission, organ transplantation, and blood transfusion [3].

64 Cats play a critical role in the life cycle of *T. gondii*, as sexual reproduction occurs exclusively in the  
65 feline intestine, producing oocysts that are shed in feces. These oocysts sporulate in the environment,  
66 becoming resistant and capable of surviving for extended periods under favorable conditions. While  
67 toxoplasmosis in cats is often asymptomatic, clinical signs may include fever, anorexia, diarrhea,  
68 respiratory or neurological disturbances, and weight loss [4]. Stray and outdoor-access cats, which  
69 often lack designated defecation sites, may bury feces in soil, allowing oocysts to remain viable for  
70 up to 18 months. Transmission can occur indirectly via earthworms and insects, further contaminating  
71 food and water sources. Human toxoplasmosis prevalence has been shown to correlate strongly with  
72 cat density and environmental oocyst contamination. Given the close interaction between cats and  
73 humans, identifying oocyst infections in definitive hosts is essential for understanding zoonotic  
74 transmission risks. This study aimed to determine the prevalence of *T. gondii* oocysts and other  
75 intestinal parasites in shelter cats in Bogor, Indonesia, and to evaluate their association with age. The  
76 findings provide valuable insights for surveillance, infection prevention, and control strategies  
77 targeting zoonotic parasitic infections.

## 78 2. Materials and Methods

79  
80 2.1 Sample Criteria and Collection. A total of 156 feline fecal samples were collected from a shelter  
81 in Bogor, with selection based on estimated age and duration of stay of the cats in the shelter. The  
82 samples consisted of 102 from adult cats (estimated age 1–5 years) and 54 from juvenile cats or kitten  
83 (estimated age 3–5 months) [5]. The duration of stay of the cats in the shelter ranged from 1 day to 5  
84 months.

85 2.2 Sampling. Fecal samples were collected from each cage housing adult and juvenile cats. Samples  
86 were obtained from litter boxes and cage floors with varying textures. Approximately 5 - 10 grams  
87 of faeces were collected using a sterile plastic spoon in a 25-ml fecal container. Each sample was  
88 labelled with an identification number and placed into a larger plastic container for storage. The  
89 collected fecal samples were transported to the Department of Parasitology, Faculty of Medicine,  
90 Universitas Indonesia, and stored at 4°C until further analysis.

91 2.3 Direct Microscopic Examination. A drop of 1–2 drops of 1% Lugol’s iodine solution was placed  
 92 on a glass slide, followed by approximately 0.5–1 g of fecal sample collected with a wooden  
 93 applicator stick. The sample was homogenized, covered with a cover slip, and examined under an  
 94 *Olympus CX31* microscope (Olympus, Japan) at 400× magnification across the entire microscope  
 95 field of view. A positive sample is declared if at least two experienced examiners observe morphology  
 96 such as eggs, larvae, or parasite oocysts to confirm the observations and a minimum of 20 fields per  
 97 slide.

98 2.4 Modified *Ziehl Neelsen* Staining (MZN). Samples were prepared using a sedimentation  
 99 concentration method as described previously [6], but replacing formalin with water. The resulting  
 100 suspension was centrifuged at 1200 rpm for 5 minutes, and the pellet obtained was used for staining.  
 101 Staining was performed following the protocol outlined by Khurana and Chaudhary [(7)], in which  
 102 carbol-fuchsin was gently heated for several seconds and subsequently decolorized with methanol-  
 103 HCl. The stained preparations were examined under an *Olympus CX31* microscope (Olympus, Japan)  
 104 at 400× and 1000× magnification using immersion oil. At least two experienced examiners  
 105 independently confirmed all observations and a minimum of 20 fields per slide.

106 2.5 Molecular Analysis [8,9]

107 Prior to DNA extraction, *Toxoplasma gondii* oocysts were isolated using a sugar flotation method. A  
 108 200 µL aliquot from the flotation suspension was subjected to 25 freeze–thaw cycles to disrupt the  
 109 oocyst wall. DNA was subsequently extracted using the FavorPrep™ Stool DNA Isolation Mini Kit,  
 110 following the manufacturer’s instructions. Nested PCR was then performed to confirm *T. gondii*  
 111 oocyst with primers targeting the SAG and GRA genes, specifically 5'-SAG2 and GRA7. (Table 1).  
 112

113 Table 1. Primer Sequence and PCR Product for *T. gondii* Detection

Gene Target	PCR	Primer sequence	Product PCR (bp)
5'-SAG2	Unnested	F:5'-GCT ACC TCG AAC AGG AAC AC-3' R:5'-GCA TCA ACA GTC TTC GTT GC-3'	335
	Nested	F:5'-GAA ATG TTT CAG GTT GCT GC-3' R5'-GCA AGA GCG AAC TTG AAC AC-3'	241
GRA7	Unnested	F:5'-CAAGCACCCGTTGACAGTCT-3' R:5'-ACGATGCACCCATACCAACAG-3'	322
	Nested	F:5'-CACCAGCATGGATAAGGCATC-3' R5'-GCGAGCTTCTTCAGCAAGTCT-3'	222

114  
 115 For amplification of the 5'-SAG2 gene, the primary (unnested) PCR was performed in a 20 µL  
 116 reaction containing 10 µL GoTaq® Green Master Mix, 0.4 µL MgCl<sub>2</sub>, 2 µL of each primer, 2 µL  
 117 DNA template, and 5.6 µL nuclease-free water. The nested PCR used the same total volume with 10  
 118 µL GoTaq® Green Master Mix, 0.4 µL MgCl<sub>2</sub>, 1 µL of each primer, 2 µL DNA template, and 6.6 µL  
 119 nuclease-free water. Cycling conditions included an initial denaturation at 94 °C for 5 min, followed  
 120 by 25 cycles of denaturation at 94 °C for 45 s, annealing at 60 °C for 45 s, and extension at 72 °C for  
 121 1 min, with a final extension at 72 °C for 10 min.

122 For the GRA7 gene, both unnested and nested PCRs were carried out in a 20 µL reaction containing  
 123 10 µL GoTaq® Green Master Mix, 0.5 µL of each primer, 2 µL DNA template, and 7.5 µL nuclease-  
 124 free water. Cycling conditions consisted of an initial denaturation at 94 °C for 2 min, followed by 30

125 cycles of denaturation at 94 °C for 40 s, annealing at 59 °C for 40 s, and extension at 72 °C for 40 s,  
126 with a final extension at 72 °C for 1 min.

127 PCR products were separated by electrophoresis on a 2% agarose gel and visualized under UV  
128 illumination.

### 129 2.6 Data Analysis

130 Data were analyzed descriptively to determine *T. gondii* prevalence. The association between age  
131 group (kittens vs adult cats) and the presence of *T. gondii* oocysts was analyzed using the Chi-Square  
132 test with a significance level of  $p < 0.05$ .

133

## 134 3. Results

### 135 3.1 Direct Microscopic Examination

136 Direct microscopic examination revealed that 25.64% (40/156) were positive for parasites with  
137 varying prevalence rates. Among this samples 40% were obtained from kitten (Table 2).

138

139

140

141

Table 2. Prevalence of Intestinal Parasites in Shelter Cats (Direct Microscopy)

Microscopic Examination	Age Group		Total
	Kittens	Adults	
Positive	16	24	40
Negative	38	78	116
Total	54	102	156

142

143 Parasite-positive samples included hookworms in 10.25%, *Toxocara* spp. in 5.12%, and  
144 *Cystoisospora* oocysts in 0.64% of cases. *T. gondii* oocysts were detected in 9.61% of samples, with  
145 80% of these originating from kittens (Table 3). The morphology of identified parasites is described  
146 in Figure 1.

147

148

Table 3. Prevalence of *T. gondii* oocysts by age group

Microscopy Examination	Age Group		Total	<i>p</i> -value
	Kitten	Adult		
Positive	12	3	15	0.000
Negative	4	21	25	
Total	16	24	40	

149

### 150 3.2 Modified Ziehl Neelsen Staining (MZN) and Molecular Analysis

151 Using modified Ziehl–Neelsen (MZN) staining, *Toxoplasma gondii* oocysts were identified in 9.61%  
152 (15/156) of samples, specifically S19, S72, S88, S91, S101, S118, S120, S122, S127, S129, S130,  
153 S132, S138, and S139, with a higher frequency in kittens. The oocysts measured 7–12 µm, exhibited  
154 a double cell wall, and contained sporozoites. Under MZN staining, they appeared as slightly oval,  
155 pink to purplish structures approximately 10–15 µm in diameter (Figure 2). Statistical analysis  
156 confirmed a significant association between oocyst presence and age group ( $p < 0.05$ , *Chi Square* test;  
157 Table 3). Of the 15 microscopy-positive samples, molecular confirmation identified four (S72, S101,

158 S120, S127) as positive for the 5'-SAG2 gene and two (S127, S130) as positive for the GRA7  
159 gene.(Figure 3).

160

#### 161 4. Discussion

162 This study demonstrates the occurrence of *Toxoplasma gondii* and other intestinal parasites in shelter  
163 cats in Bogor, Indonesia, with an overall prevalence of 25.64%. The findings highlight the  
164 susceptibility of shelter populations, where crowding, frequent intake of new animals, and limited  
165 veterinary care increase infection risk.

166 Hookworms were the most common parasites, followed by *T. gondii*, *Toxocara*, and *Cystoisospora*.  
167 The prevalence of hookworm in this study was 10.25%, with eggs observed as uncolored and oval  
168 shape (Figure 1). This rate is lower than that reported in Ireland (23.2%) but slightly higher than in  
169 the United States (9.1%). Variations in prevalence may be explained by differences in transmission  
170 routes, environmental conditions, feline feeding behavior, and food sources. At low intensities,  
171 hookworm infection in cats is often asymptomatic; however, heavy worm burdens can result in  
172 life-threatening anemia [1,10]. The severity of infection depends on worm species, parasite load, host  
173 immunity, and nutritional status. Animals in shelters are generally more susceptible to parasitic  
174 infections due to close contact with other animals, frequent intake of new individuals, and often  
175 inadequate veterinary care—factors that may also apply to the present study [11].

176 The prevalence of *Toxocara* in this study was 5.12%, with eggs appearing brown and circular (Figure  
177 1). Samples were obtained from shelter cats with outdoor access, which increases susceptibility  
178 through free-roaming behavior, predatory habits, and insufficient deworming. The prevalence  
179 observed here is lower than that reported in Nepal (94.4%), the United Kingdom (90.9%), and  
180 Bangladesh (76.9%). Globally, the highest prevalence has been reported in Asia (27.9%), followed  
181 by Africa (21.4%) and North America (18.5%). Infection rates are also higher in feral cats (42.6%)  
182 compared to shelter cats (20.1%) and are elevated in outdoor cats with limited veterinary care.  
183 Clinical signs of toxocariasis, such as diarrhea and inappetence, may occur during patent infection  
184 but are not pathognomonic, as they overlap with other gastrointestinal parasitic diseases. Direct smear  
185 microscopy has been associated with higher prevalence rates (10.5–26.1%); the lower prevalence in  
186 this study may be attributed to a lower intensity of *Toxocara* egg shedding in the samples [12].

187

188

189

190

191

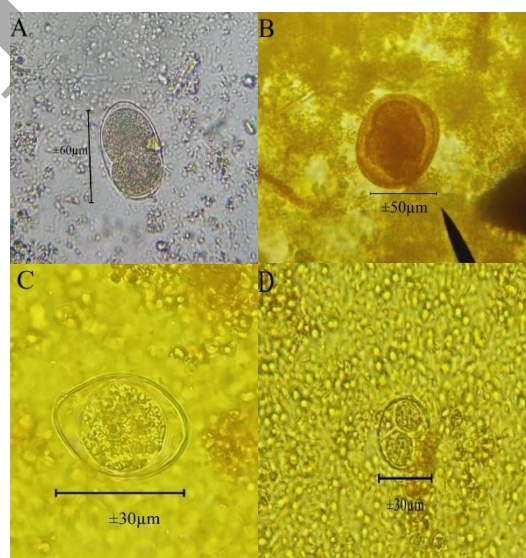
192

193

194

195

196

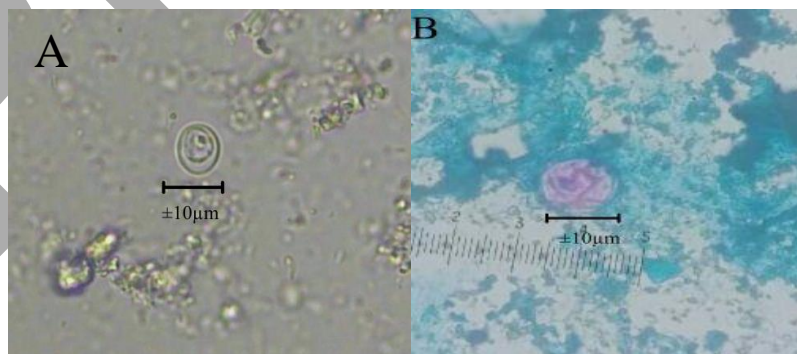


197 Figure 1. Direct Microscopic Examination Results A) Hookworm (Sample No. 151), B) *Toxocara*  
198 (Sample No. 41), C) Unsporulated *Cystoisospora* oocysts, D) Sporulated *Cystoisospora* oocysts

199  
200 The prevalence of *Cystoisospora* in this study was 0.64%, with both unsporulated and sporulated  
201 oocysts detected (Figure 1). This rate is lower than those reported in Greece (33.1%), the United  
202 States (>30%), and the United Kingdom (3%). Kittens and young animals typically shed more  
203 oocysts; the lower prevalence in this study may be explained by the fact that the detected cases were  
204 in adult cats. Additionally, study area, sample size, diagnostic techniques, climatic conditions, and  
205 limited veterinary care may have influenced the results. Cats become infected by ingesting sporulated  
206 oocysts from the environment or through intermediate hosts, infection rates are higher in free-roaming  
207 cats or those kept in large groups with shared litter, increasing exposure to infective stages. While  
208 infections are often asymptomatic, kittens may exhibit vomiting, abdominal discomfort, severe  
209 dehydration, bloody watery diarrhea, and even death [13,14,15].

210 The prevalence of *T. gondii* in this study was 9.61%, with unsporulated oocysts detected (Figure 2).  
211 This finding is lower than rates reported in Malaysia, the United States, Ethiopia (19%), and Thailand  
212 (19.3%), but higher than those in Kuwait and Portugal (9.9% and 9.1%, respectively) [16,17], in the  
213 present study, *T. gondii* oocysts were found more frequently in kittens.

214 In this study, fecal samples were obtained from a shelter housing a heterogeneous population of cats,  
215 including strays, previously owned pets, and rescued individuals, many of which were in poor  
216 condition. Because feeding habits and lifestyle histories could not be precisely determined, multiple  
217 risk factors likely contributed to the observed infections. This finding is consistent with reports of  
218 higher infection rates in stray cats. For example, in Greece, *Toxoplasma gondii* prevalence was higher  
219 in feral cats, which also shed more oocysts (4.1%) compared to owned cats. Toxoplasmosis has  
220 frequently been identified in cats with poor health and inadequate diets, conditions that compromise  
221 immune function. It is important to note that *T. gondii* oocysts may be absent in parasitological tests,  
222 as only about 1% of cats excrete them at any given time. The sample size in this study may therefore  
223 have been insufficient for detection, and morphological differentiation from other protozoa, such as  
224 *Hammondia hammondi*, remains challenging. These factors highlight the need for further diagnostic  
225 confirmation [18].



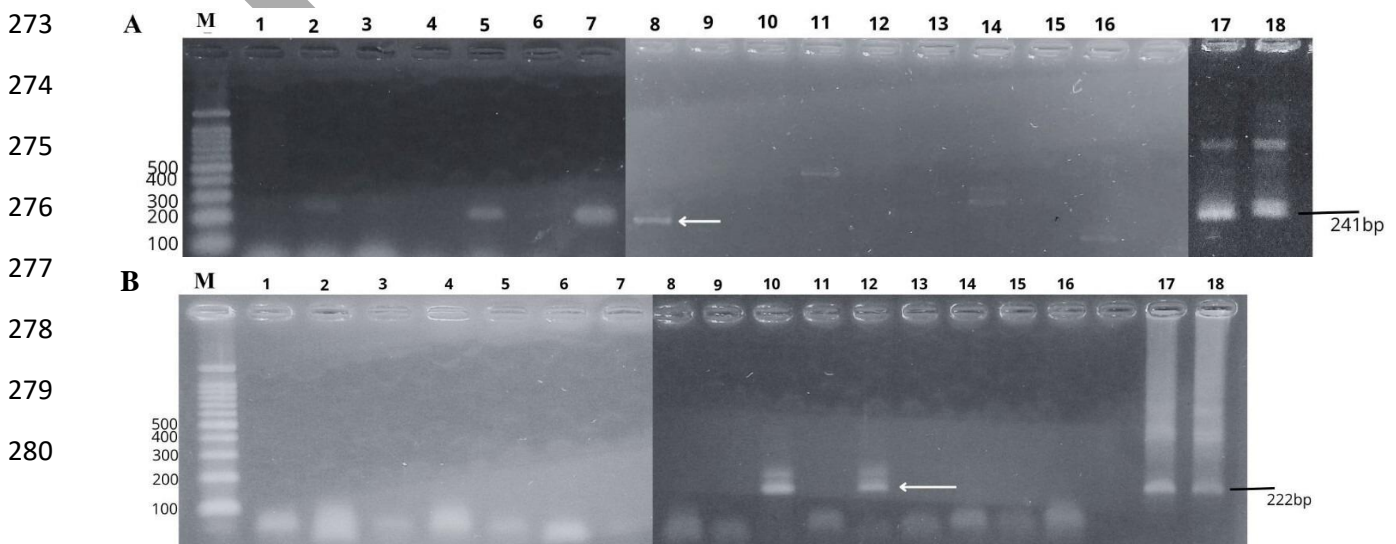
226  
227  
228  
229  
230  
231  
232  
233  
234 Figure 2. *T. gondii* Oocyst: A) Observed by Direct Microscopy, B) stained with in modified Ziehl-  
235 Neelsen (MZN)

236  
237 *T. gondii* oocysts observed via direct microscopy were further examined using the modified Ziehl-  
238 Neelsen (MZN) method. The oocysts appeared as slightly oval, pink to purplish structures,  
239 approximately 10–15 µm in diameter (Figure 2), similar in appearance to *Cryptosporidium* oocysts

240 but difficult to distinguish from other protozoa. A study in Iran also used the MZN method to detect  
241 *T. gondii* oocysts in soil samples but found it insufficiently effective due to interference from soil  
242 particles, which complicated identification [19]. While the MZN method is primarily used for  
243 detecting acid-fast organisms and allows for better morphological observation of oocysts with high  
244 specificity and sensitivity for certain protozoa, in this study it should be combined with other  
245 techniques to confirm the identity of the observed oocysts as *T. gondii*, this finding than confirm using  
246 molecular method. Molecular methods, such as those targeting the B1 gene, are also effective for  
247 detecting *T. gondii* DNA in tissues and blood samples from both definitive and intermediate hosts [3]  
248 but in this study, molecular confirmation was performed using the SAG and GRA genes. Among the  
249 15 samples that were positive by microscopy, four were confirmed by targeting the 5'-SAG2 and two  
250 samples by GRA7 genes. The SAG2 gene is suitable for amplification and genotyping of *T.*  
251 *gondii* because it contains specific polymorphic sites and requires only a small amount of DNA,  
252 meanwhile GRA7 is identified as most conserved genes in *T. gondii* genome making it applicable to  
253 a wide range of sample types, these characteristics may have influenced the results of the present  
254 study, nested PCR that used in this study demonstrates sensitivity and specificity and indicating  
255 potential for accurate diagnosis and genotyping [8,9].

256 Toxoplasmosis in cats is often asymptomatic; however, several studies have reported clinical signs  
257 including fever, ocular inflammation, anorexia, lethargy, respiratory disorders, weight loss, and  
258 neurological abnormalities. Increased human population density correlates with rising cat populations  
259 and higher environmental oocyst loads, leading to contamination that can infect other animals and  
260 subsequently transmit to humans [20].

261 The samples used in this study may not be fully representative, as they were obtained from a single  
262 shelter in a limited geographical area, which could affect prevalence estimates. Expanding the sample  
263 size is recommended. Microscopic examination allows clear observation of the infectious stages of  
264 parasites and is suitable for initial detection, but should be combined with other methods to confirm  
265 findings. Although *T. gondii* oocysts showed a statistically significant difference between kittens and  
266 adult cats ( $p < 0.05$ ) with kitten being more susceptible for *T. gondii* infection. The significantly  
267 higher prevalence of *T. gondii* oocysts in kittens compared to adults but there is a statistically  
268 significant difference ( $p < 0.05$ ). This finding consistent with a report from France which noted that  
269 *T. gondii* oocysts were detected in fecal samples 16 days post-infection with kittens capable of  
270 shedding and re-shedding up to one billion oocysts, which contribute disproportionately to  
271 environmental contamination. This report showed in kitten, oocyst shedding can be also attributed to  
272 congenital toxoplasmosis leading such as toxoplasmic hepatitis and pneumonia [18].



281

282 Figure 3. PCR amplification results: A) 5'-SAG2 gene (241bp), B) GRA7 gene (222 bp)

283 Some studies have reported mixed parasitic infections in cats that prey on intermediate hosts, a pattern  
284 associated with outdoor lifestyles and consumption of untreated water, which may influence disease  
285 severity, although mixed infections were not detected in this study, the findings align with  
286 observations that co-infections can reduce parasite loads through negative interactions, potentially  
287 explaining the absence of specific clinical manifestations in infected cats [21].

288 A novel aspect of this work is the integration of microscopy, MZN staining, and nested PCR targeting  
289 SAG2 and GRA7 genes. This combined approach allowed confirmation of *T. gondii* oocysts in six  
290 samples, underscoring the importance of molecular tools for differentiating morphologically similar  
291 protozoa.

292 Cats serve as a source of human infection by contaminating the environment with infectious stages  
293 of parasites such as *Toxocara*, hookworm, *Cystoisospora*, and *T. gondii*, posing a public health  
294 concern. As the definitive host for *T. gondii*, cats are a primary source of transmission, underscoring  
295 the need for surveillance to determine parasite prevalence. Surveillance should integrate multiple  
296 diagnostic methods to accurately confirm infections. Preventive measures include population control  
297 through trap-neuter-release programs, regular removal of cat feces from the environment, and control  
298 of intermediate hosts. Personal hygiene, especially after contact with cats, is recommended. Cat  
299 owners and shelter staff are advised to avoid feeding raw food and water, maintain household hygiene,  
300 routinely clean litter boxes, and practice hand hygiene to prevent parasitic infections.

301 Several limitations must be acknowledged. The study was restricted to a single shelter, limiting  
302 generalizability. The sample size, while adequate for initial estimates, may not capture the full  
303 diversity of parasitic infections. Morphological overlap with other protozoa, such as *Hammondia*  
304 *hammondi*, complicates microscopic identification, reinforcing the need for molecular confirmation.  
305 The cross-sectional design also precludes assessment of seasonal variation or longitudinal shedding  
306 patterns.

## 307 5. Conclusion

308 This study identified an overall intestinal parasite prevalence in shelter cats in Bogor, Indonesia, there  
309 is 40/156 samples (25.64%) with hookworms as the most common parasite, followed by *Toxoplasma*  
310 *gondii*, *Toxocara* spp., and *Cystoisospora* spp. The significantly higher prevalence of *T. gondii*  
311 oocysts in kittens compared to adults underscores their role as important contributors to  
312 environmental contamination. By integrating parasitological and molecular methods, this study  
313 confirmed *T. gondii* oocysts in shelter cats and highlighted the value of combining diagnostic  
314 approaches to improve detection accuracy.

315 The findings emphasize the zoonotic risk posed by shelter cats, particularly kittens, and the need for  
316 preventive measures such as routine deworming, improved hygiene practices, and public education  
317 on safe handling of cats and litter. Limitations include the single-shelter sampling and restricted  
318 geographical scope, which may affect generalizability. Nevertheless, the study provides valuable  
319 baseline data for Indonesia and contributes to global understanding of feline parasitic infections.

320 Strengthening surveillance systems that integrate microscopy, staining, and molecular tools will be  
321 essential for accurate monitoring and effective control strategies. These measures will help reduce  
322 environmental contamination, protect public health, and support sustainable management of shelter  
323 and stray cat populations

324 **Acknowledgment**

325 This study was supported by Universitas Indonesia which has given the Hibah Publikasi Terindeks  
326 Internasional (PUTI) Pasca Sarjana 2024. Universitas Indonesia only provided financial support but  
327 had no role in the study design, data analysis, interpretation, or manuscript preparation.

328

329 **Author's Contribution**

330 Study concept and design (AK and IPS), acquisition of data (SP), analysis and interpretation of data  
331 (SP, IPS, AK), drafting of the manuscript (SP), critical revision of the manuscript for important  
332 intellectual content (SP, IPS, AK), statistical analysis (SP), all authors reviewed the manuscript.

333

334 **Ethics**

335 This study received ethical approval from the Health Research Ethics Committee of Dr. Cipto  
336 Mangunkusumo National General Hospital, Faculty of Medicine, Universitas Indonesia (Approval  
337 No. KET-330/UN2.F1/ETIK/PPM.00.02/2025; Protocol No. 25-02-0195).

338

339 **Conflict of Interest**

340 There is no conflict of interest by the authors.

341 **Data Availability**

342 All data and supplementary information would be available upon request from the corresponding  
343 author

344

345 **Funding**

346 The Funding source of this research is supported by Hibah Publikasi Terindeks Internasional (PUTI)  
347 Pasca Sarjana 2024 from Universitas Indonesia No. NKB-55/UN2.RST/HKP.05.00/2024.

348

349 **AI Disclosure**

350 Portions of draft text were corrected with assistance from an AI tool; all authors reviewed, revised,  
351 and take responsibility for the final content.

352

353 **References**

- 354 1. Waal T De, Aungier S, Lawlor A, Goddu T, Jones M, Szlosek D. Retrospective Survey of Dog  
355 and Cat Endoparasites in Ireland: Antigen Detection. *Animals*. 2023,13,137. [https://doi.org/](https://doi.org/10.3390/ani13010137)  
356 [10.3390/ani13010137](https://doi.org/10.3390/ani13010137)
- 357 2. Candela MG, Fanelli A, Carvalho J, Serrano E, Domenech G, Alonso F. Urban landscape and  
358 infection risk in free-roaming cats. *Zoonosis Public Health*. 2022;69:295–311. DOI:  
359 [10.1111/zph.12919](https://doi.org/10.1111/zph.12919)
- 360 3. Jahantigh FF, Rasekh M, Ganjali M, Sarani A. Seroprevalence of *Toxoplasma Gondii* Infection  
361 Among Pregnant Women and Small Ruminant Populations in Sistan Region, Iran. *Iran J Vet*  
362 *Med*. 2020;14(03):239–50. DOI: [10.22059/ijvm.2020.294216.1005048](https://doi.org/10.22059/ijvm.2020.294216.1005048)
- 363 4. Altner N, Kemmling L, Rentería-solís Z, Obiegala A, Fietz SA, Heilmann RM. *Toxoplasma*  
364 *gondii* Seroprevalence and Risk Factors in Feline Patients Admitted to a Small Animal  
365 Veterinary Teaching Hospital in Central Germany over 11 Years ( 2012 – 2023 ). *Pets*. 2025;1–  
366 9. <https://doi.org/10.3390/pets2010007>
- 367 5. Quimby J, Gowland S, Carney HC, DePorter T, Plummer P, Westropp J. 2021 AAHA/AAFP  
368 Feline Life Stage Guidelines. *J Feline Med Surg*. 2021;23(3):211–33. DOI:  
369 [10.1177/1098612X21993657](https://doi.org/10.1177/1098612X21993657)

- 370 6. Tahvildar-biderouni F, Salehi N. Detection of Cryptosporidium infection by modified ziehl-  
371 neelsen and PCR methods in children with diarrheal samples in pediatric hospitals in Tehran.  
372 Gastroenterol Hepatol Bed Bench. 2014;7(4):125–30.  
373 <https://pmc.ncbi.nlm.nih.gov/articles/PMC4017569/>
- 374 7. Khurana S, Chaudhary P. Laboratory diagnosis of cryptosporidiosis. Trop Parasitol.  
375 2018;8(1):2–7. <https://pmc.ncbi.nlm.nih.gov/articles/PMC5991046/>
- 376 8. Kurniawan A, Sari IP, Harminarti N, Edwar L, Susiyanti M. Toxoplasma gondii SAG2 type  
377 III in an atypical presentation of ocular toxoplasmosis in Indonesia. Int J Infect Dis.  
378 2020;96:440–4. DOI: <https://doi.org/10.1016/j.ijid.2020.05.017>
- 379 9. Harminarti N, Sari IP, Artama WT, Imran D, Kurniawan A. Comparative GRA6 and GRA7  
380 for their Utility as Genetic Markers in the Genotyping of Cerebral Toxoplasmosis in  
381 Cerebrospinal Fluid. Acta Parasitol. 2024;69(3):1555–61. DOI:  
382 <https://doi.org/10.1007/s11686-024-00901-3>
- 383 10. Baker E, DeBolt R, Smith E, Gerhold R, Wyrosdick H. Fecal prevalence and diversity of  
384 endoparasites in shelter dogs and cats from East Tennessee. Vet Parasitol Reg Stud Reports  
385 [Internet]. 2025;58(November 2024):101212. Available from:  
386 <https://doi.org/10.1016/j.vprsr.2025.101212>
- 387 11. Traub RJ, Zendejas-Heredia PA, Massetti L, Colella V. Zoonotic hookworms of dogs and cats  
388 – lessons from the past to inform current knowledge and future directions of research. Int J  
389 Parasitol [Internet]. 2021;51(13–14):1233–41. Available from:  
390 <https://doi.org/10.1016/j.ijpara.2021.10.005>
- 391 12. Bonilla-Aldana JL, Espinosa-Nuñez AC, Bonilla-Aldana DK, Rodriguez-Morales AJ.  
392 Toxocara cati Infection in Cats (Felis catus): A Systematic Review and Meta-Analysis.  
393 Animals. 2024;14(7). <https://doi.org/10.3390/ani14071022>
- 394 13. Alhamza ARA, Al-Hasnawy MH. First microscopic detection of Cystoisospora protozoan  
395 infecting dogs in Babylon province. Acta Entomol Zool. 2025;6(1):150–5.  
396 <https://www.doi.org/10.33545/27080013.2025.v6.i1b.202>
- 397 14. Lappin MR, Medicine DI. Update on the Diagnosis and Management of Isospora spp  
398 Infections in Dogs and Cats. Top Companion Anim Med. 2010;133–5.  
399 doi:10.1053/j.tcam.2010.07.001
- 400 15. Morelli S, Di Cesare A, Traversa D, Astuti C, Lallone I, Tsokana CN, et al. Occurrence of  
401 Cystoisospora spp. and other intestinal parasites in dogs and cats with diarrhea. Vet Parasitol  
402 [Internet]. 2025;338(March):110546. Available from:  
403 <https://doi.org/10.1016/j.vetpar.2025.110546>
- 404 16. Wana MN, Mohd Moklas MA, Watanabe M, Unyah NZ, Abdullahi SA, Alapid AAI, et al.  
405 Molecular detection and genetic diversity of Toxoplasma gondii oocysts in cat faeces from  
406 Klang Valley, Malaysia, using B1 and rep genes in 2018. Pathogens. 2020;9(7):1–16.  
407 doi:10.3390/pathogens9070576
- 408 17. Ismail MT, Al-Kafri A. Prevalence of Toxoplasma gondii-like oocyst shedding in feral and  
409 owned cats in Damascus, Syria. J Vet Intern Med. 2023;37(3):976–9. DOI:  
410 10.1111/jvim.16683
- 411 18. Sioutas G, Symeonidou I, Gelasakis AI, Tzirinis C, Papadopoulos E. Feline Toxoplasmosis in  
412 Greece: A Countrywide Seroprevalence Study and Associated Risk Factors. Pathogens.  
413 2022;11(12):1–13. <https://doi.org/10.3390/pathogens11121511>
- 414 19. Solymane H, Eslamirad Z, Bayat M, Hajihosseini R. Molecular Detection of Toxoplasma  
415 gondii Oocytes in the Soil from the Public Parks of the Arak City, Iran. Res Mol Med.  
416 2014;2(1):35–8. DOI:10.18869/acadpub.rmm.2.1.35
- 417 20. Wit LA De, Kilpatrick AM, Vanwormer E, Croll DA, Tershy BR, Kim M, et al. Seasonal and  
418 spatial variation in Toxoplasma gondii contamination in soil in urban public spaces in  
419 California, United States. Zoonoses Public Health. 2019;00:1–9. DOI: 10.1111/zph.12656

- 420 21. da Igreja JASL, Rezende HHA, Melo J de O, Garcia JL, Martins FDC, de Castro AM. Copro-  
421 PCR in the detection and confirmation of *Toxoplasma gondii* oocysts in feces of stray and  
422 domiciled cats. *Rev Bras Parasitol Vet.* 2021;30(2):6–11. [https://doi.org/10.1590/S1984-](https://doi.org/10.1590/S1984-29612021022)  
423 29612021022  
424

Preprint