Archives of Razi Institute Journal
"Arch. Razi Inst."

Journal Homepage: https://archrazi.areeo.ac.ir/

Research Paper

Zoonotic Parasites in Shelter Cats: Microscopy and Molecular Evidence of *Toxoplasma gondii* in Bogor, Indonesia

Sekar Pratiwi[1], Ika Puspa Sari[2*], Agnes Kurniawan[2]

1. Master's Programme in Biomedical Sciences, Faculty of Medicine, Universitas Indonesia, Jakarta, Indonesia.
2. Department of Parasitology, Faculty of Medicine, Universitas Indonesia, Jakarta, Indonesia.

Use your device to scan and read the article online

How to cite this article Pratiwi S, Sari IP, Kurniawan A. Zoonotic Parasites in Shelter Cats: Microscopy and Molecular Evidence of Toxoplasma gondii in Bogor, Indonesia. Archives of Razi Institute Journal. 2026; 81(4):961-970. https://doi.org/10.32598/ARI.81.4.3912

https://doi.org/10.32598/ARI.81.4.3912

Article info:
Received: 21 Mar 2026
Accepted: 28 Apr 2026
Published: 01 Jul 2026

Keywords:
Microscopic examination, Molecular detection, Shelter cats, *Toxoplasma gondii*, Zoonotic parasites

ABSTRACT

Introduction: Cats serve as definitive hosts for several zoonotic parasites, most notably *Toxoplasma gondii*, which can contaminate the environment with infective oocysts and pose significant risks to public health. Shelter populations, often composed of stray, rescued, and previously owned cats, represent an important reservoir of infection due to their diverse backgrounds and variable health conditions.

Materials & Methods: In this study, a total of 156 fecal samples were collected from shelter cats in Bogor, Indonesia, comprising 102 adults and 54 kittens. Samples were examined using direct microscopy, modified Ziehl–Neelsen (MZN) staining, and nested PCR targeting the *5'SAG2* and *GRA7* genes. Statistical analysis was performed using the chi-square test to evaluate associations between age and parasite prevalence.

Results: Overall, intestinal parasites were detected in 25.64% of samples. Hookworms were the most frequently identified (10.25%), followed by *T. gondii* oocysts (9.61%), *Toxocara* spp. (5.12%), and *Cystoisospora* spp. (0.64%). The prevalence of *T. gondii* oocysts was significantly higher in kittens compared to adults ($P<0.05$), underscoring the role of younger cats in environmental contamination. Of the 15 microscopypositive samples, molecular confirmation identified four positives for the *5'SAG2* gene and two for the *GRA7* gene, thereby validating the presence of *T. gondii* and reducing the likelihood of misidentification with morphologically similar protozoa.

Conclusion: These findings highlight shelter cats, particularly kittens, as an important source of zoonotic parasites. The integration of parasitological and molecular methods enhances detection accuracy and provides a more reliable assessment of infection dynamics. Strengthened surveillance and targeted control strategies are essential to mitigate environmental contamination, reduce zoonotic transmission, and protect both animal and human health.

*** Corresponding Author:**
Ika Puspa Sari, Assistant Professor.
Address: *Department of Parasitology, Faculty of Medicine, Universitas Indonesia, Jakarta, Indonesia.*
E-mail: *ika.puspa@ui.ac.id*

Copyright © 2026 The Author(s);
This work is licensed under a Creative Commons Attribution-NonCommercial 4.0 International license (https://creativecommons.org/licenses/by-nc/4.0/).
Noncommercial uses of the work are permitted, provided the original work is properly cited.

1. Introduction

Cats are among the most popular companion animals worldwide, resulting in close and frequent interactions with humans. The growth of the human population has contributed to increasing numbers of pet cats as well as expanding stray populations [1]. Stray cats are particularly common in urban and suburban areas, where high human density facilitates close contact between cats and people. As definitive hosts for several parasites, including *Toxocara*, *Giardia*, *Cryptosporidium*, *Cystoisospora*, hookworms, and *Toxoplasma gondii*, cats can shed infective stages into the environment, contaminating soil, water, and food sources, and thereby posing a risk of zoonotic transmission [2].

T. gondii is an obligate intracellular protozoan responsible for toxoplasmosis, a globally prevalent zoonotic disease. It can infect humans and other warm-blooded animals, with significant consequences for livestock such as sheep, where infection may cause abortion and economic losses. Approximately one-third of the global human population is estimated to be infected, often asymptomatically. Transmission occurs through ingestion of contaminated food or water, vertical transmission, organ transplantation, and blood transfusion [3].

Cats play a critical role in the life cycle of *T. gondii*, as sexual reproduction occurs exclusively in the feline intestine, producing oocysts that are shed in feces. These oocysts sporulate in the environment, becoming resistant and capable of surviving for extended periods under favorable conditions. While toxoplasmosis in cats is often asymptomatic, clinical signs may include fever, anorexia, diarrhea, respiratory or neurological disturbances, and weight loss [4]. Stray and outdoor access cats, which often lack designated defecation sites, may bury feces in soil, allowing oocysts to remain viable for up to 18 months. Transmission can occur indirectly via earthworms and insects, further contaminating food and water sources. Human toxoplasmosis prevalence has been shown to correlate strongly with cat density and environmental oocyst contamination. Given the close interaction between cats and humans, identifying oocyst infections in definitive hosts is essential for understanding zoonotic transmission risks. This study aimed to determine the prevalence of *T. gondii* oocysts and other intestinal parasites in shelter cats in Bogor, Indonesia, and to evaluate their association with age. The findings provide valuable insights for surveillance, infection prevention, and control strategies targeting zoonotic parasitic infections.

2. Materials and Methods

2.1. Sample criteria and collection

A total of 156 feline fecal samples were collected from a shelter in Bogor, with selection based on estimated age and duration of stay of the cats in the shelter. The samples consisted of 102 from adult cats (estimated age 1–5 years) and 54 from juvenile cats or kitten (estimated age 3–5 months) [5]. The duration of stay of the cats in the shelter ranged from 1 day to 5 months.

2.2. Sampling

Fecal samples were collected from each cage housing adult and juvenile cats. Samples were obtained from litter boxes and cage floors with varying textures. Approximately 5-10 grams of faeces were collected using a sterile plastic spoon in a 25-mL- fecal container. Each sample was labelled with an identification number and placed into a larger plastic container for storage. The collected fecal samples were transported to the Department of Parasitology, Faculty of Medicine, Universitas Indonesia, and stored at 4 °C until further analysis.

2.3. Direct microscopic examination

A drop of 1–2 drops of 1% Lugol's iodine solution was placed on a glass slide, followed by approximately 0.5–1 g of fecal sample collected with a wooden applicator stick. The sample was homogenized, covered with a cover slip, and examined under an Olympus CX31 microscope (Olympus, Japan) at 400× magnification across the entire microscope field of view. A positive sample is declared if at least two experienced examiners observe morphology such as eggs, larvae, or parasite oocysts to confirm the observations and a minimum of 20 fields per slide.

2.4. Modified Ziehl Neelsen staining

Samples were prepared using a sedimentation concentration method as described previously [6], but replacing formalin with water. The resulting suspension was centrifuged at 1200 rpm for 5 minutes, and the pellet obtained was used for staining. Staining was performed following the protocol outlined by Khurana and Chaudhary [7], in which carbol-fuchsin was gently heated for several seconds and subsequently decolorized with methanol-HCl. The stained preparations were examined under an Olympus CX31 microscope (Olympus, Japan) at 400× and 1000× magnification using immersion oil. At least two experienced examiners independently confirmed all observations and a minimum of 20 fields per slide.

2.5. Molecular analysis [8, 9]

Prior to DNA extraction, *T. gondii* oocysts were isolated using a sugar flotation method. A 200 µL aliquot from the flotation suspension was subjected to 25 freeze–thaw cycles to disrupt the oocyst wall. DNA was subsequently extracted using the FavorPrep™ Stool DNA Isolation Mini Kit, following the manufacturer's instructions. Nested polymerase chain reaction (PCR) was then performed to confirm *T. gondii* oocyst with primers targeting the *SAG* and *GRA* genes, specifically *5′ SAG2* and *GRA7* (Table 1).

For amplification of the *5′ SAG2* gene, the primary (unnested) PCR was performed in a 20 µL reaction containing 10 µL GoTaq® Green Master Mix, 0.4 µL $MgCl_2$, 2 µL of each primer, 2 µL DNA template, and 5.6 µL nuclease-free water. The nested PCR used the same total volume with 10 µL GoTaq® Green Master Mix, 0.4 µL $MgCl_2$, 1 µL of each primer, 2 µL DNA template, and 6.6 µL nuclease-free water. Cycling conditions included an initial denaturation at 94 ˚C for 5 min, followed by 25 cycles of denaturation at 94 ˚C for 45 s, annealing at 60 ˚C for 45 s, and extension at 72 ˚C for 1 min, with a final extension at 72 ˚C for 10 min.

For the *GRA7* gene, both unnested and nested PCRs were carried out in a 20 µL reaction containing 10 µL GoTaq® Green Master Mix, 0.5 µL of each primer, 2 µL DNA template, and 7.5 µL nuclease-free water. Cycling conditions consisted of an initial denaturation at 94 ˚C for 2 min, followed by 30 cycles of denaturation at 94 ˚C for 40 s, annealing at 59 ˚C for 40 s, and extension at 72 ˚C for 40 s, with a final extension at 72 ˚C for 1 min.

PCR products were separated by electrophoresis on a 2% agarose gel and visualized under UV illumination.

2.6. Data analysis

Data were analyzed descriptively to determine *T. gondii* prevalence. The association between age group (kittens vs adult cats) and the presence of *T. gondii* oocysts was analyzed using the chi-square test with a significance level of $P<0.05$.

3. Results

3.1. Direct microscopic examination

Direct microscopic examination revealed that 25.64% (40/156) were positive for parasites with varying prevalence rates. Among this samples 40% were obtained from kitten (Table 2).

Parasite-positive samples included hookworms in 10.25%, *Toxocara* spp. in 5.12%, and *Cystoisospora* oocysts in 0.64% of cases. *T. gondii* oocysts were detected in 9.61% of samples, with 80% of these originating from kittens (Table 3). The morphology of identified parasites is described in Figure 1.

3.2. Modified Ziehl Neelsen staining and molecular analysis

Using modified Ziehl–Neelsen (MZN) staining, *T. gondii* oocysts were identified in 9.61% (15/156) of samples, specifically S19, S72, S88, S91, S101, S118, S120, S122, S127, S129, S130, S132, S138, and S139, with a higher frequency in kittens. The oocysts measured 7–12 µm, exhibited a double cell wall, and contained sporozoites. Under MZN staining, they appeared as slightly oval, pink to purplish structures approximately 10–15 µm in diameter (Figure 2). Statistical analysis confirmed a significant association between oocyst presence and age group ($P<0.05$, chi square test; Table 3). Of the 15 microscopypositive samples, molecular confirmation identified four (S72, S101, S120, S127) as positive for the *5′SAG2* gene and two (S127, S130) as positive for the *GRA7* gene (Figure 3).

Table 1. Primer sequence and PCR product for *T. gondii* detection

Gene Target	PCR	Primer Sequence	Product PCR (bp)
5′-SAG2	Unnested	F:5′-GCT ACC TCG AAC AGG AAC AC-3′ R:5′-GCA TCA ACA GTC TTC GTT GC-3′	335
	Nested	F:5′-GAA ATG TTT CAG GTT GCT GC-3′ R5′-GCA AGA GCG AAC TTG AAC AC-3′	241
GRA7	Unnested	F:5′-CAAGCACCCGTTGACAGTCT-3′ R:5′-ACGATGCACCCATACCAACAG-3′	322
	Nested	F:5′-CACCAGCATGGATAAGGCATC-3′ R5′-GCGAGCTTCTTCAGCAAGTCT-3′	222

Table 2. Prevalence of intestinal parasites in shelter cats (direct microscopy)

Microscopic Examination	Age Group		Total
	Kittens	Adults	
Positive	16	24	40
Negative	38	78	116
Total	54	102	156

Table 3. Prevalence of *T. gondii* oocysts by age group

Microscopy Examination	Age Group		Total	P
	Kitten	Adult		
Positive	12	3	15	
Negative	4	21	25	0.000
Total	16	24	40	

4. Discussion

This study demonstrates the occurrence of *T. gondii* and other intestinal parasites in shelter cats in Bogor, Indonesia, with an overall prevalence of 25.64%. The findings highlight the susceptibility of shelter populations, where crowding, frequent intake of new animals, and limited veterinary care increase infection risk.

Hookworms were the most common parasites, followed by *T. gondii*, *Toxocara*, and *Cystoisospora*. The prevalence of hookworm in this study was 10.25%, with eggs observed as uncolored and oval shape (Figure 1). This rate is lower than that reported in Ireland (23.2%) but slightly higher than in the United States (9.1%). Variations in prevalence may be explained by differences in transmission routes, environmental conditions, feline feeding behavior, and food sources. At low intensities, hookworm infection in cats is often asymptomatic; however, heavy worm burdens can result in life threatening anemia [1, 10]. The severity of infection depends on worm species, parasite load, host immunity, and nutritional status. Animals in shelters are generally more susceptible to parasitic infections due to close contact with other animals, frequent intake of new individuals, and often inadequate veterinary care—factors that may also apply to the present study [11].

The prevalence of *Toxocara* in this study was 5.12%, with eggs appearing brown and circular (Figure 1). Samples were obtained from shelter cats with outdoor access, which increases susceptibility through free-roaming behavior, predatory habits, and insufficient deworming. The prevalence observed here is lower than that reported in Nepal (94.4%), the United Kingdom (90.9%), and Bangladesh (76.9%). Globally, the highest prevalence has been reported in Asia (27.9%), followed by Africa (21.4%) and North America (18.5%). Infection rates are also higher in feral cats (42.6%) compared to shelter cats (20.1%) and are elevated in outdoor cats with limited veterinary care. Clinical signs of toxocariasis, such as diarrhea and inappetence, may occur during patent infection but are not pathognomonic, as they overlap with other gastrointestinal parasitic diseases. Direct smear microscopy has been associated with higher prevalence rates (10.5–26.1%); the lower prevalence in this study may be attributed to a lower intensity of Toxocara egg shedding in the samples [12].

The prevalence of *Cystoisospora* in this study was 0.64%, with both unsporulated and sporulated oocysts detected (Figure 1). This rate is lower than those reported in Greece (33.1%), the United States (>30%), and the United Kingdom (3%). Kittens and young animals typically shed more oocysts; the lower prevalence in this study may be explained by the fact that the detected cases were in adult cats. Additionally, study area, sample size, diagnostic techniques, climatic conditions, and limited veterinary care may have influenced the results. Cats become infected by ingesting sporulated oocysts from the environment or through intermediate hosts, infection rates are higher in free-roaming cats or those kept

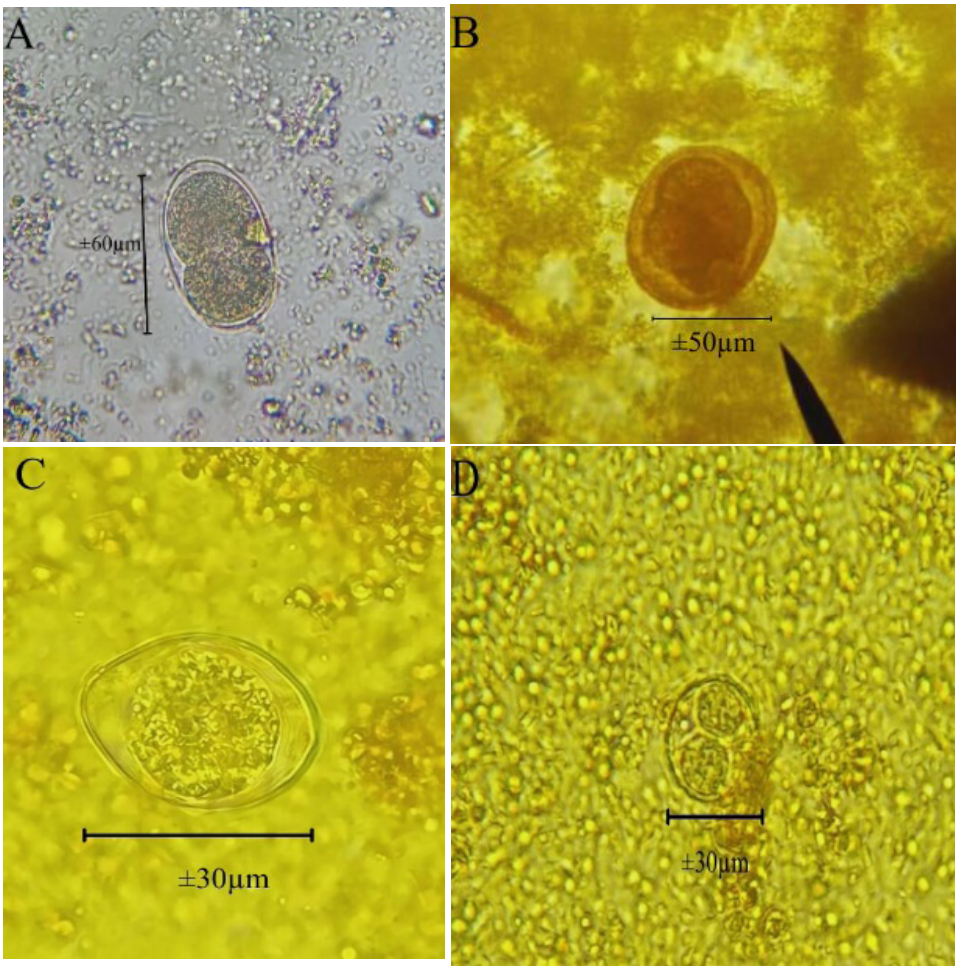

Figure 1. Direct microscopic examination results

A) Hookworm (sample No. 151), B) *Toxocara* (sample No. 41), C) Unsporulated *Cystoisospora* oocysts, D) Sporulated *Cystoisospora* oocysts

in large groups with shared litter, increasing exposure to infective stages. While infections are often asymptomatic, kittens may exhibit vomiting, abdominal discomfort, severe dehydration, bloody watery diarrhea, and even death [13-15].

The prevalence of *T. gondii* in this study was 9.61%, with unsporulated oocysts detected (Figure 2). This finding is lower than rates reported in Malaysia, the United States, Ethiopia (19%), and Thailand (19.3%), but higher than those in Kuwait and Portugal (9.9% and 9.1%, respectively) [16, 17], in the present study, *T. gondii* oocysts were found more frequently in kittens.

In this study, fecal samples were obtained from a shelter housing a heterogeneous population of cats, including strays, previously owned pets, and rescued individuals, many of which were in poor condition. Because feeding habits and lifestyle histories could not be precisely determined, multiple risk factors likely contributed to the observed infections. This finding is consistent with reports of higher infection rates in stray cats. For example, in Greece, *T. gondii* prevalence was higher in feral cats, which also shed more oocysts (4.1%) compared to owned cats. Toxoplasmosis has frequently been identified in cats with poor health and inadequate diets, conditions that compromise immune function. It is important to note that *T. gondii* oocysts may be absent in parasitological tests, as only about 1% of cats excrete them at any given time. The sample size in this study may therefore have been insufficient for detection, and morphological differentiation from other protozoa, such as *Hammondia hammondi*, remains challenging. These factors highlight the need for further diagnostic confirmation [18].

T. gondii oocysts observed via direct microscopy were further examined using the MZN method. The oocysts appeared as slightly oval, pink to purplish structures, ap-

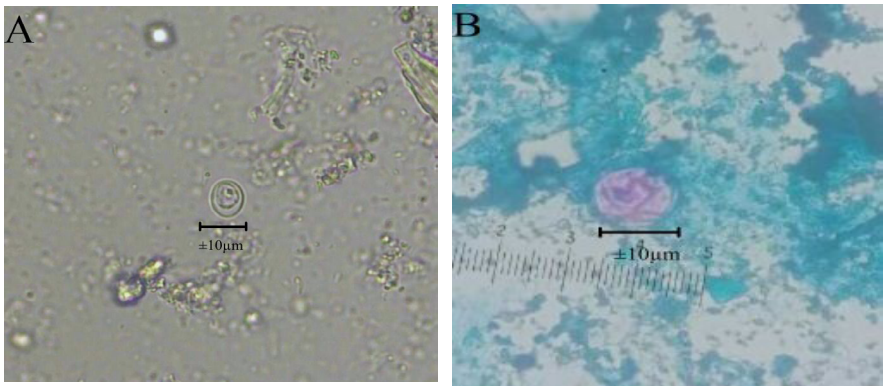

Figure 2. *T.gondii* oocyst

A) Observed by direct microscopy, B) Stained with in modified MZN

proximately 10–15 µm in diameter (Figure 2), similar in appearance to *Cryptosporidium* oocysts but difficult to distinguish from other protozoa. A study in Iran also used the MZN method to detect *T. gondii* oocysts in soil samples but found it insufficiently effective due to interference from soil particles, which complicated identification [19]. While the MZN method is primarily used for detecting acid-fast organisms and allows for better morphological observation of oocysts with high specificity and sensitivity for certain protozoa, in this study it should be combined with other techniques to confirm the identity of the observed oocysts as *T. gondii*, this finding than confirm using molecular method. Molecular methods, such as those targeting the B1 gene, are also effective for detecting *T. gondii* DNA in tissues and blood samples from both definitive and intermediate hosts [3] but in this study, molecular confirmation was performed using the *SAG* and *GRA* genes. Among the 15 samples that were positive by microscopy, four were confirmed by targeting the 5'-SAG2 and two samples by GRA7 genes. The *SAG2* gene is suitable for amplification and genotyping of *T. gondii* because it contains specific polymorphic sites and requires only a small amount of DNA, meanwhile *GRA7* is identified as most conserved genes in *T. gondii* genome making it applicable to a wide range of sample types, these characteristics may have influenced the results of the present study, nested PCR that used in this study demonstrates sensitivity and specificity and indicating potential for accurate diagnosis and genotyping [8, 9].

Toxoplasmosis in cats is often asymptomatic; however, several studies have reported clinical signs including fever, ocular inflammation, anorexia, lethargy, respira-

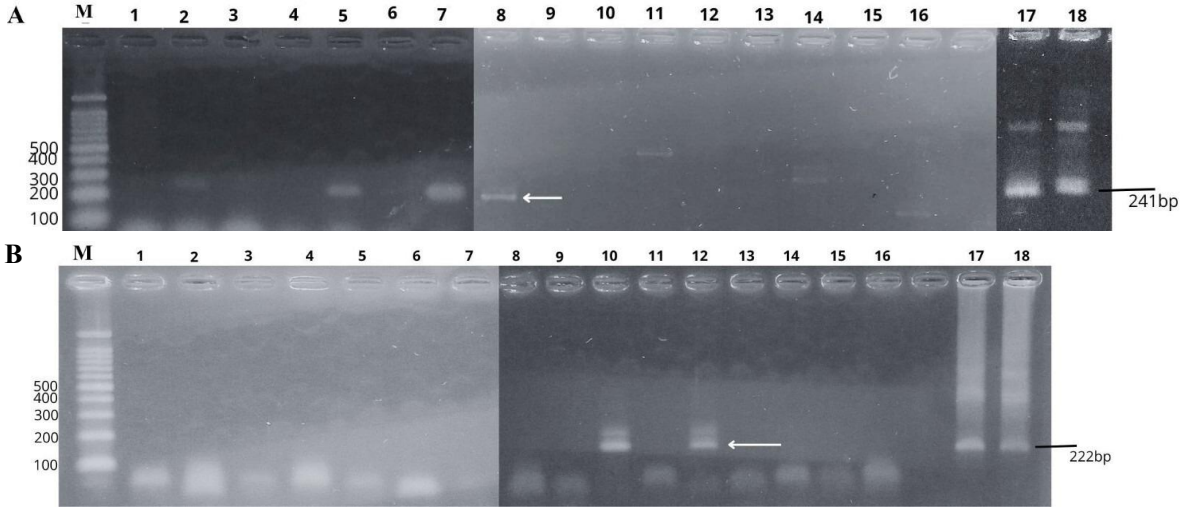

Figure 3. PCR amplification results

A) *5'-SAG2* gene (241bp), B) *GRA7* gene (222 bp)

tory disorders, weight loss, and neurological abnormalities. Increased human population density correlates with rising cat populations and higher environmental oocyst loads, leading to contamination that can infect other animals and subsequently transmit to humans [20].

The samples used in this study may not be fully representative, as they were obtained from a single shelter in a limited geographical area, which could affect prevalence estimates. Expanding the sample size is recommended. Microscopic examination allows clear observation of the infectious stages of parasites and is suitable for initial detection, but should be combined with other methods to confirm findings. Although *T. gondii* oocysts showed a statistically significant difference between kittens and adult cats ($P<0.05$) with kitten being more susceptible for *T. gondii* infection. The significantly higher prevalence of *T. gondii* oocysts in kittens compared to adults but there is a statistically significant difference ($P<0.05$). This finding consistent with a report from France which noted that *T. gondii* oocysts were detected in fecal samples 16 days post-infection with kittens capable of shedding and re-shedding up to one billion oocysts, which contribute disproportionately to environmental contamination. This report showed in kitten, oocyst shedding can be also attributed to congenital toxoplasmosis leading such as toxoplasmic hepatitis and pneumonia [18].

Some studies have reported mixed parasitic infections in cats that prey on intermediate hosts, a pattern associated with outdoor lifestyles and consumption of untreated water, which may influence disease severity, although mixed infections were not detected in this study, the findings align with observations that co-infections can reduce parasite loads through negative interactions, potentially explaining the absence of specific clinical manifestations in infected cats [21].

A novel aspect of this work is the integration of microscopy, MZN staining, and nested PCR targeting *SAG2* and *GRA7* genes. This combined approach allowed confirmation of *T. gondii* oocysts in six samples, underscoring the importance of molecular tools for differentiating morphologically similar protozoa.

Cats serve as a source of human infection by contaminating the environment with infectious stages of parasites such as *Toxocara*, hookworm, *Cystoisospora*, and *T. gondii*, posing a public health concern. As the definitive host for *T. gondii*, cats are a primary source of transmission, underscoring the need for surveillance to determine parasite prevalence. Surveillance should integrate multiple diagnostic methods to accurately confirm infections. Preventive measures include population control through trap-neuter-release programs, regular removal of cat feces from the environment, and control of intermediate hosts. Personal hygiene, especially after contact with cats, is recommended. Cat owners and shelter staff are advised to avoid feeding raw food and water, maintain household hygiene, routinely clean litter boxes, and practice hand hygiene to prevent parasitic infections.

Several limitations must be acknowledged. The study was restricted to a single shelter, limiting generalizability. The sample size, while adequate for initial estimates, may not capture the full diversity of parasitic infections. Morphological overlap with other protozoa, such as *H. hammondi*, complicates microscopic identification, reinforcing the need for molecular confirmation. The cross-sectional design also precludes assessment of seasonal variation or longitudinal shedding patterns.

5. Conclusion

This study identified an overall intestinal parasite prevalence in shelter cats in Bogor, Indonesia, there is 40/156 samples (25.64%) with hookworms as the most common parasite, followed by *T. gondii*, *Toxocara* spp., and *Cystoisospora* spp. The significantly higher prevalence of *T. gondii* oocysts in kittens compared to adults underscores their role as important contributors to environmental contamination. By integrating parasitological and molecular methods, this study confirmed *T. gondii* oocysts in shelter cats and highlighted the value of combining diagnostic approaches to improve detection accuracy.

The findings emphasize the zoonotic risk posed by shelter cats, particularly kittens, and the need for preventive measures such as routine deworming, improved hygiene practices, and public education on safe handling of cats and litter. Limitations include the single shelter sampling and restricted geographical scope, which may affect generalizability. Nevertheless, the study provides valuable baseline data for Indonesia and contributes to global understanding of feline parasitic infections.

Strengthening surveillance systems that integrate microscopy, staining, and molecular tools will be essential for accurate monitoring and effective control strategies. These measures will help reduce environmental contamination, protect public health, and support sustainable management of shelter and stray cat populations.

Acknowledgements

This study was supported by Universitas Indonesia which has given the Hibah Publikasi Terindeks Internasional (PUTI) Pasca Sarjana 2024. Universitas Indonesia only provided financial support but had no role in the study design, data analysis, interpretation, or manuscript preparation.

Compliance with ethical guidelines

This study received ethical approval from the Health Research Ethics Committee of Dr. Cipto Mangunkusumo National General Hospital, Faculty of Medicine, Universitas Indonesia (Code: KET-330/UN2.F1/ETIK/PPM.00.02/2025; Protocol No.: 25-02-0195).

Funding

The Funding source of this research is supported by Hibah Publikasi Terindeks Internasional (PUTI) Pasca Sarjana 2024 from Universitas Indonesia No.: NKB-55/UN2.RST/HKP.05.00/2024.

Authors' contributions

Conceptualization and study design: Agnes Kurniawan and Ika Puspa Sari; Data acquisition, statistical analysis, and writing the original draft: Sekar Pratiwi; Analysis and data interpretation: Sekar Pratiwi, Ika Puspa Sari, and Agnes Kurniawan; Review and editing: Sekar Pratiwi, Ika Puspa Sari, and Agnes Kurniawan; Final approval: All authors.

Conflict of interest

The authors declared no conflict of interest.

Data availability

All data and supplementary information would be available upon request from the corresponding author.

References

[1] de Waal T, Aungier S, Lawlor A, Goddu T, Jones M, Szlosek D. Retrospective survey of dog and cat endoparasites in Ireland: Antigen Detection. Animals. 2023, 13(1):137. [DOI:10.3390/ani13010137] [PMID]

[2] Candela MG, Fanelli A, Carvalho J, Serrano E, Domenech G, Alonso F. Urban landscape and infection risk in free-roaming cats. Zoonoses Public Health. 2022; 69(4):295-311. [DOI:10.1111/zph.12919] [PMID]

[3] Jahantigh FF, Rasekh M, Ganjali M, Sarani A. Seroprevalence of Toxoplasma gondii infection among pregnant women and small ruminant populations in Sistan Region, Iran. Iran J Vet Med. 2020; 14(03):239-50. [Link]

[4] Altner N, Kemmling L, Rentería-solís Z, Obiegala A, Fietz SA, Heilmann RM. Toxoplasma gondii seroprevalence and risk factors in feline patients admitted to a small animal veterinary teaching hospital in central Germany over 11 years (2012-2023). Pets. 2025; 2(1):7. [DOI:10.3390/pets2010007]

[5] Quimby J, Gowland S, Carney HC, DePorter T, Plummer P, Westropp J. 2021 AAHA/AAFP Feline Life Stage Guidelines. J Feline Med Surg. 2021; 23(3):211-33. [DOI:10.1177/1098612X21993657] [PMID]

[6] Tahvildar-biderouni F, Salehi N. Detection of Cryptosporidium infection by modified ziehl-neelsen and PCR methods in children with diarrheal samples in pediatric hospitals in Tehran. Gastroenterol Hepatol Bed Bench. 2014; 7(4):125-30. [PMID]

[7] Khurana S, Chaudhary P. Laboratory diagnosis of cryptosporidiosis. Trop Parasitol. 2018; 8(1):2-7. [DOI:10.4103/tp.TP_34_17] [PMID]

[8] Kurniawan A, Sari IP, Harminarti N, Edwar L, Susiyanti M. Toxoplasma gondii SAG2 type III in an atypical presentation of ocular toxoplasmosis in Indonesia. Int J Infect Dis. 2020; 96:440-4. [DOI:10.1016/j.ijid.2020.05.017] [PMID]

[9] Harminarti N, Sari IP, Artama WT, Imran D, Kurniawan A. Comparative GRA6 and GRA7 for their utility as genetic markers in the genotyping of cerebral toxoplasmosis in cerebrospinal fluid. Acta Parasitol. 2024; 69(3):1555-61. [DOI:10.1007/s11686-024-00901-3] [PMID]

[10] Baker E, DeBolt R, Smith E, Gerhold R, Wyrosdick H. Fecal prevalence and diversity of endoparasites in shelter dogs and cats from East Tennessee. Vet Parasitol Reg Stud Reports. 2025; 58:101212. [DOI:10.1016/j.vprsr.2025.101212] [PMID]

[11] Traub RJ, Zendejas-Heredia PA, Massetti L, Colella V. Zoonotic hookworms of dogs and cats - lessons from the past to inform current knowledge and future directions of research. Int J Parasitol. 2021; 51(13-14):1233-41. [DOI:10.1016/j.ijpara.2021.10.005] [PMID]

[12] Bonilla-Aldana JL, Espinosa-Nuñez AC, Bonilla-Aldana DK, Rodriguez-Morales AJ. Toxocara cati infection in cats (Felis catus): A systematic review and meta-analysis. Animals. 2024; 14(7):1022. [DOI:10.3390/ani14071022] [PMID]

[13] Alhamza ARA, Al-Hasnawy MH. First microscopic detection of Cystoisospora protozoan infecting dogs in Babylon province. Acta Entomol Zool. 2025; 6(1):150-5. [DOI:10.33545/27080013.2025.v6.i1b.202]

[14] Lappin MR. Update on the Diagnosis and Management of Isospora spp Infections in Dogs and Cats. Top Companion Anim Med. 2010; 25(3):133-5. [DOI:10.1053/j.tcam.2010.07.001] [PMID]

[15] Morelli S, Di Cesare A, Traversa D, Astuti C, Lallone I, Tsokana CN, et al. Occurrence of Cystoisospora spp. and other intestinal parasites in dogs and cats with diarrhea. Vet Parasitol. 2025; 338:110546. [DOI:10.1016/j.vetpar.2025.110546] [PMID]

[16] Nasiru Wana M, Mohd Moklas MA, Watanabe M, Zasmy Unyah N, Alhassan Abdullahi S, Ahmad Issa Alapid A, et al. Molecular detection and genetic diversity of Toxoplasma gondii oocysts in cat faeces from Klang Valley, Malaysia, using B1 and rep genes in 2018. Pathogens. 2020; 9(7):576. [DOI:10.3390/pathogens9070576] [PMID]

[17] Ismail MT, Al-Kafri A. Prevalence of Toxoplasma gondii-like oocyst shedding in feral and owned cats in Damascus, Syria. J Vet Intern Med. 2023; 37(3):976-9. [DOI:10.1111/jvim.16683] [PMID]

[18] Sioutas G, Symeonidou I, Gelasakis AI, Tzirinis C, Papadopoulos E. Feline toxoplasmosis in Greece: A countrywide seroprevalence study and associated risk factors. pathogens. 2022; 11(12):1511. [DOI:10.3390/pathogens11121511] [PMID]

[19] Solymane H, Eslamirad Z, Bayat M, Hajihossein R. Molecular Detection of Toxoplasma gondii Oocytes in the Soil from the Public Parks of the Arak City, Iran. Res Mol Med. 2014; 2(1):35-8. [DOI:10.18869/acadpub.rmm.2.1.35]

[20] de Wit LA, Kilpatrick AM, VanWormer E, Croll DA, Tershy BR, Kim M, et al. Seasonal and spatial variation in Toxoplasma gondii contamination in soil in urban public spaces in California, United States. Zoonoses Public Health. 2020; 67(1):70-8. [DOI:10.1111/zph.12656] [PMID]

[21] Igreja JASLD, Rezende HHA, Melo JO, Garcia JL, Martins FDC, Castro AM. Copro-PCR in the detection and confirmation of Toxoplasma gondii oocysts in feces of stray and domiciled cats. Rev Bras Parasitol Vet. 2021; 30(2):e000621. [DOI:10.1590/S1984-29612021022] [PMID]

This Page Intentionally Left Blank