



Research Paper

Gastrointestinal Parasites in Working Donkeys (*Equus asinus*) From Cusco, Peru: First Report of *Fasciola hepatica* Infection in Equids From Southern PeruMilena Alison Villafuerte Pancorbo¹, Ines Milagros Limaymanta Zavala², Daniel A. Zárate-Rendón^{2*}

1. Veterinary Medicine and Animal Science Program, Scientific University of the South, Lima, Peru.

2. Laboratory of Parasitology, Faculty of Animal Science, National Agrarian University La Molina, Lima, Peru.

**How to cite this article** Villafuerte Pancorbo MA, IM, Zárate-Rendón DA. Gastrointestinal Parasites in Working Donkeys (*Equus asinus*) From Cusco, Peru: First Report of *Fasciola hepatica* Infection in Equids From Southern Peru. *Archives of Razi Institute Journal*. 2026; 81(2):525-534. <https://doi.org/10.32598/ARI.81.2.3945> <https://doi.org/10.32598/ARI.81.2.3945>

Article info:

Received: 14 Nov 2025

Accepted: 23 Dec 2025

Published: 01 Mar 2026

Keywords:

Donkeys, Fasciolosis,
Helminths, Liver fluke, Peru,
Strongyles.

ABSTRACT

Introduction: Working donkeys (*Equus asinus*) are rustic animals used in rural communities as a means of transport and cargo. They are raised under grazing conditions with precarious health management, which are conditions that favor the presence of severe parasitoses. The present study aimed to identify gastrointestinal parasites infecting working donkeys from the Colcha-Paruro district, Cusco, Peru, in October 2022.

Materials & Methods: A non-probabilistic convenience sampling method was employed, collecting fecal samples from 26 donkeys. The samples were taken to the Laboratory of Parasitology at the National Agrarian University of La Molina in isothermal boxes with ice packs. Once in the laboratory, samples were analyzed using a modified flotation technique using salt-sugar solution, a modified McMaster method, and the fluke finder. Coprocultures and the Baermann technique were performed to obtain infective larvae (L3) for morphological identification of strongyles.

Results: General results showed a prevalence of 100% (26/26) for strongyles. Infective larvae identified were 100% cyathostomes. Moreover, 19.2% (5/26) were positive for *Fasciola hepatica* and 7.7% (2/26) for *Parascaris* spp.

Conclusion: Our study underscores the need for more effective parasite control strategies to improve the health status of working donkeys, to reduce the impact of these infections on their welfare and to consider these animals in human fascioliasis control programs from a One-Health perspective. This study constitutes the second report in Peru of natural infection with *Fasciola hepatica* in donkeys, and the first one for the southern region. This finding suggests their possible role in the epidemiology of fasciolosis in the area, including a role in zoonotic infection. The high prevalence of cyathostomes reported confirms the importance of these strongyles in grass-fed equines and indicates deficiencies in health protocols. Future studies on possible anthelmintic resistance are recommended.

* Corresponding Author:

Daniel A. Zárate-Rendón, Professor.

Address: Laboratory of Parasitology, Faculty of Animal Science, National Agrarian University La Molina, Lima, Peru.

Tel: +511 (495) 6147800

E-mail: dazre@lamolina.edu.peCopyright © 2026 The Author(s).
This work is licensed under a Creative Commons Attribution-NonCommercial 4.0 International license (<https://creativecommons.org/licenses/by-nc/4.0/>).
Noncommercial uses of the work are permitted, provided the original work is properly cited.

1. Introduction

Donkeys (*Equus asinus*) are a very important livestock species in various regions of Peru, as they continue to be used as pack and working animals despite technological advances and agrarian mechanization, mainly due to the difficulty in applying agricultural technologies in remote regions of the Peruvian territory. In this context, donkeys constitute a practical alternative. These animals are considered resilient and rustic; therefore, their sanitary management is empirical and often deficient [1]. Donkeys, like horses and other equids, are susceptible to several parasitoses; many of which are common to the equine family. These parasites, in both their adult and larval stages, can affect the animals negatively [2].

Gastrointestinal parasites are a major group of parasites that affect equids, the most frequent being: roundworms (*Parascaris equorum*), large strongyles (*Strongylus* spp), small strongyles or cyathostomes (Cyathostominae), pinworms (*Oxyuris equi*), and Strongyloides. Strongyles (both large and small) are the most prevalent, pathogenic, and difficult to treat due to the rise of anthelmintic resistance [3]. The negative impact of strongyles is linked to their biological cycle, as part of it occurs in the gastrointestinal tract, which can generate severe lesions in the mucosa and blood vessels during larval migration. This can cause mild colic or even death in extreme cases [4].

Other major equine gastrointestinal parasites are *Eimeria* spp., which cause equine coccidiosis, tapeworms (*Anoplocephala perfoliata* and *Anoplocephala magna*), and trematodes (*Fasciola hepatica*) [5]. For instance, *A. perfoliata* can cause clinical disease in equines, producing ulcers in the intestinal mucosa, spasmodic colic, and ileal impaction [6].

Knowledge is scarce about the presence of gastrointestinal parasites in donkeys in Peru, with only one report for the northern region (Cajamarca) and no recent reports for the southern region. The characterization of the parasitic fauna present in these animals will enable the design of more effective preventive health control and management strategies specific to an area and tailored to local conditions.

The objective of this study was to investigate the parasitic fauna and identify the main parasitic species in donkeys (*E. asinus*) from the district of Colcha, province of Paruro, in the Department of Cusco.

2. Materials and Methods

2.1. Location

This study was carried out during October 2022, in the Colcha district, Province of Paruro (71°50'52" W longitude and 13°45'42" S latitude, Greenwich meridian) (Figure 1). The district covers high Andean areas and inter-Andean valleys. This district is located 64 kilometers southeast of Cusco City, at 3068 meters above sea level.

2.2. Animals

The animals sampled were Creole donkeys (*E. asinus*), grass-fed and primarily used for transport and packing. The sample size was non-probabilistic and based on convenience, as the total donkey population in the area is currently unknown, and there were logistical difficulties in accessing all areas of the district (Figures 2a and 2b). Due to these difficulties, the number of sampled animals was severely reduced. Inclusion criteria were: animals older than 3 months of age (average age at the start of grazing). Animals that had undergone internal deworming less than six months prior to sampling were excluded. A total of 26 animals were sampled, 19 of which were males and 7 were females. Body condition, weight, sex, and age of each animal were recorded during sampling.

2.3. Sampling

For sample collection, approximately 10 grams of feces were extracted directly from the rectum using plastic rectal palpation gloves and mineral oil as a lubricant. Each sample was immediately placed in polyethylene bags that were properly labeled. The bags were then immediately placed in an isothermal container with gel packs to keep the samples at refrigeration temperatures (4–6 °C). Samples were taken to the Laboratory of Parasitology, Faculty of Animal Science, National Agrarian University of La Molina.

2.4. Coprological tests

2.4.1. Modified flotation technique

Samples were analyzed using a modified flotation test with a saturated salt and sugar solution to detect and identify parasitic eggs and/or oocysts [7]. The flotation solution used in this protocol is made of 400 g of commercial salt and 500 g of brown sugar, dissolved in one liter of distilled water (specific gravity =1.27). In brief, 2 to 5 grams of feces were homogenized in the flotation solution using a mortar and pestle. This suspension was then filtered through four layers of gauze and poured

into 15-mL centrifuge tubes, filling the tubes to obtain a positive meniscus. A coverslip was placed on the top of the tubes as a lid, and it stood for 10 minutes. Each coverslip was transferred to a slide and observed under a LEICA microscope (model DM500) at 4x and 10x magnifications.

2.4.2. Modified McMaster technique

A modified McMaster technique was performed to count Strongyle-type eggs (STE) per gram of feces (epg) [8]. In brief, 2 grams of feces were homogenized in 28 mL of salt- and sugar-saturated flotation solution, filtered through four layers of gauze, and poured into a 60-mL plastic beaker. Using a 3-mL Pasteur pipette, the homogenized material was poured into a 2-chamber McMaster slide. The slide was observed under a LEICA microscope (model DM500) at 4x and 10x magnifications. The total number of eggs counted in both chambers was multiplied by 50 to obtain the epg.

2.4.3. Modified flukefinder® test

This test was performed to detect *F. hepatica* eggs [9]. In brief, 2 grams of feces was homogenized in 30 mL of tap water. This suspension was passed through the flukefinder® apparatus by tilting the apparatus, tapping it gently, and adding tap water directly from the faucet. This procedure was repeated three times. The apparatus was subsequently disassembled, and the interior side of the lower mesh was rinsed thoroughly using a washing bottle into a 15-mL centrifuge tube. The suspension was allowed to stand for 10 minutes. Sediment was placed in a Petri dish, and a drop of methylene blue was added, then observed under a stereoscope (Leica EZ4, Germany).

2.4.4. Fecal culture and Baermann technique

To identify which type of strongyles (small or large) were present in the samples, a coproculture was performed, mixing the STE-positive feces with vermiculite to obtain infective larvae (L3) by means of the Baermann technique.

2.4.5. Measurement of infective larvae

Following the recovery of infective larvae (L3), a measurement process was performed using the Leica Application Suite (LAS) EZ software, adapted to a Leica DM500 microscope (Leica Microsystems). Infective larvae were identified by their morphological characteristics, as *Strongylus* spp. or cyathostomes [10].

2.5. Data analysis

Data and variables (hpg, body condition, weight, sex, and age) of donkeys, and detected parasites were organized using Microsoft® Excel® for Microsoft 365 MSO (version 2412 build 16.0.18324.20092) for analysis and formulation of statistical tables and prevalences. Python version 3.9 software was used for correlations. Scatter plots were created for epgs using GraphPad Prism 10.5.0.774 (GraphPad Software, USA).

3. Results

The results obtained indicate that 100% (26/26) of the sampled donkeys tested positive for the presence of strongyles (STE) (Figures 3a and 3a). A notable finding is the exclusive presence of *Parascaris* spp. in females, while it was not detected in males. On the other hand, *F. hepatica* (Figure 3b) was identified in both sexes (Table 1).

Regarding the sex and age of the animals, all females (9/9) and males (17/17) were positive for the presence of strongyles, a result that was repeated in adults and juveniles. It should be noted that the predisposition to having high parasite loads is not directly linked to sex or age.

Furthermore, the egg count per gram of feces (epg) showed an overall average of 844.23 epg (500-1000 epg). Regarding parasitic burden levels, this can be classified into low, this can be classified into low (<500 epg), medium (500-1000 epg), and high (>1000 epg) burden (Table 3). Despite the broad dispersion observed, some individuals had high loads (>1500 epg), but the majority of the population was clustered between 500 and 1000 epg [15]. Therefore, donkeys have a highly variable load, with some individuals severely infected and others with lower levels (Figure 4). Identification of infective larvae (L3) obtained by feces culture indicated that 100% of the observed L3s (Figure 5) correspond to cyathostomins (subfamily Cyathostominae).

Finally, associations between epg, weight, and body condition were found, where the higher the epg, the better the body condition, with a positive compensation (0.32), while weight and epg showed a negative correlation (-0.22).

4. Discussion

Our results indicated a high overall prevalence for cyathostomes (100%), a moderate prevalence for the trematode *F. hepatica* (19.2%), and a low percentage of

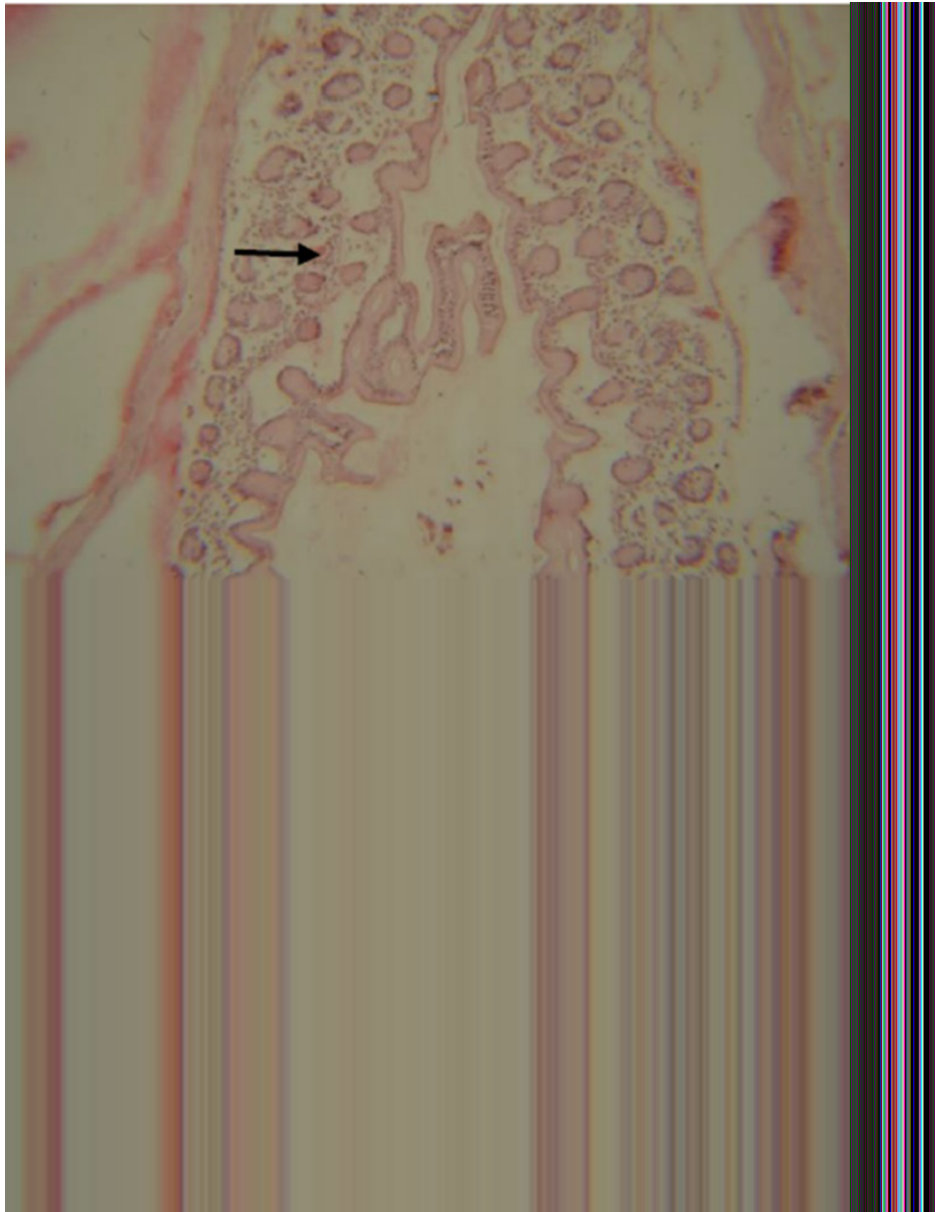


Figure 1. Cusco Department (red) - Paruro Province - Colcha District (yellow dot, pointed to by black arrow) (taken from Google Earth)

infection with *Parascaris* spp. (7.7%). The prevalence of cyathostomes and *Parascaris* spp. observed in this study is similar to that previously reported in working donkeys in Latin America. For example, in Colombia, Herrera et al. [11] reported a 98% prevalence for strongyles (large and small), and a 19.3% prevalence for *Parascaris equorum*. In Mexico, a 100% prevalence for gastrointestinal parasites, with a predominance of cyathostomes, has been reported [12]. On the other hand, in Ethiopia, strongyles are the most prevalent gastrointestinal parasite in working donkeys (37.74%); coincidentally with our results, *Parascaris* spp. was the second most common gastrointestinal helminth (11.28%) [13]. All these

results confirm that cyathostomes (small strongyles) are the dominant parasites in donkeys worldwide. The similar high frequencies of cyathostomes reported in the Americas and Africa could be linked to the handling of donkeys, with non-optimal sanitary protocols, and the possibility of therapeutic failure of anthelmintic drugs [14].

Regarding the burden of strongyles, expressed as fecal egg counts (epg), in Kenya, in a slaughterhouse for working donkeys, it was found that 56% of slaughtered animals were not infected with intestinal helminths, 39% had a low burden (<500 epg), 5% a medium burden



Figure 2. Donkey (*E. asinus*) rearing conditions in the Colcha district

Note: The coexistence of these animals in the rural environment, where they live in streets (2a) and grazing areas (2b), highlighting their importance in daily life and local agricultural activities.

(501-1000 epg), and 0.7% a high burden (>1000 epg) [15]. In contrast, our results showed higher parasitic burdens, with 42.31% (11/26) animals exceeding 500 epg and 34.62% (9/11) exhibiting eggs higher than 1000. These differences can be attributed to the fact that Kenya is one of the largest exporters of donkey meat in Africa. The use of donkey meat for human consumption implies more rigorous sanitary management. This is not the case in Peru, where the consumption of meat or derivatives of these animals is not part of the traditional diet and is even seen as taboo, since these animals are perceived as working animals.

The relatively low prevalence of *Parascaris* spp. found in our study could be related to the age of the animals, since it has been demonstrated that this nematode usually occurs more frequently in populations of foals under one year old, as it is linked to the animal's poorly developed immunity and is not usually found in adults, as acquired immunity allows for better control [16]. In this way, the low frequency of *Parascaris* spp. found in our study could be due to the small number of young animals (younger than one year) sampled during the study.

A remarkable finding of our study was the absence of common equine gastrointestinal helminths such as *O.*

Table 1. Overall prevalence and prevalence according to sex of helminths found in *E. asinus* (n=26) in the District of Colcha, Cusco, October 2022

Parasite	Frequency		Prevalence (%)	95% CI
	Females	Males		
Strongyles (STE)	7/7	19/19	100 (26/26)	86.8, 100
<i>F. hepatica</i>	3/7	2/19	19.2 (5/26)	6.6, 39.4
<i>Parascaris</i> spp.	2/7	0/19	7.7 (2/26)	0.9, 25.1

Table 2. Distribution of parasitic burdens, expressed as eggs per gram (epg) of strongyles (STE) in *E. asinus* (n=26) from the District of Colcha, Cusco, October 2022

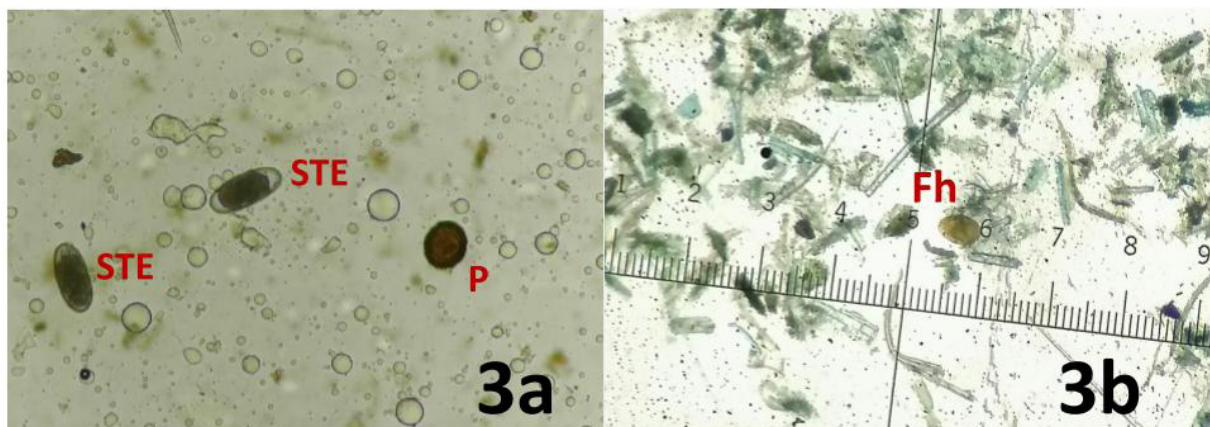
Range	Positive/Total	Proportion (%)
Low (<500 epg)	6/26	23.07
Medium (500-1000 epg)	11/26	42.31
High (>1000 epg)	26/9	34.62

equi, *Trichostrongylus* spp., and *Anoplocephala* spp. These parasites have been documented in other countries in the Americas [11, 12]. Despite the greater variety of parasites reported in these investigations, cyathostomes were still the major group, followed by *Parascaris* spp. In our study, only three groups were found. This is possibly related to the reduced population of donkeys in the District of Colcha, which is over-dispersed and with very limited movement, and therefore has a low probability of contracting parasites. Another variable to be considered is the specific local geographical and climatic conditions.

A notable discovery in this work is the detection of *F. hepatica* in 19.2% (5/26) of the animals. This confirms the results obtained from previous studies conducted on donkeys and horses from Northern Peru [5, 17]. The donkey, like equines in general, lacks a gallbladder. This means that the bile produced by the liver is not stored and goes directly to the small intestine. Thus, from the point of view of the transmission of this trematode, the eggs cannot be stored in the gallbladder, and their fecal excretion should be more regular and constant than in animals that have a gallbladder [18]. The detection of fasciolosis in donkeys from this area highlights the risk of zoonotic transmission, as donkeys in the Andean rangelands interact with people and are in close contact with sheep and cattle, which are the primary reservoirs

of this parasite. In this regard, the Colcha district reported a population of 2,086 cattle and 2,768 sheep [19], which shows the significant presence of potential hosts that may contribute to the presence of *F. hepatica* and its transmission to humans. The surveillance for human fascioliasis in Peru establishes guidelines for the detection and control of this zoonosis in vulnerable populations, highlighting equines as potential disseminators of the parasite in multiple regions [20]. It is important to mention that the donkey is the most susceptible equine species to developing serious liver pathologies such as hyperlipidemia [18].

Finally, the correlations made between the eggs, body condition, and weight show that there is a weak but positive correlation between parasite burden and body condition (0.32), as well as a negative relationship between epg and weight (-0.22). This differs from the common logic that would suggest that animals with high parasitic burdens should present poor body condition and even some signs of clinical disease. However, this is explained by Morales et al [21], whose study on grazing cattle shows similar results, indicating that animals with good body condition are classified as «resilient», meaning they adapt to high burdens by finding a balance and maintaining their productivity. Nevertheless, this does not exempt them from being classified as disseminators

**Figure 3.** a) Microscopic photograph (X40) of a strongyle-type egg (STE) and a *Parascaris* spp. egg (P) identified by the flotation test; b) *F. hepatica* egg (Fh) identified by the Fluke Finder® test

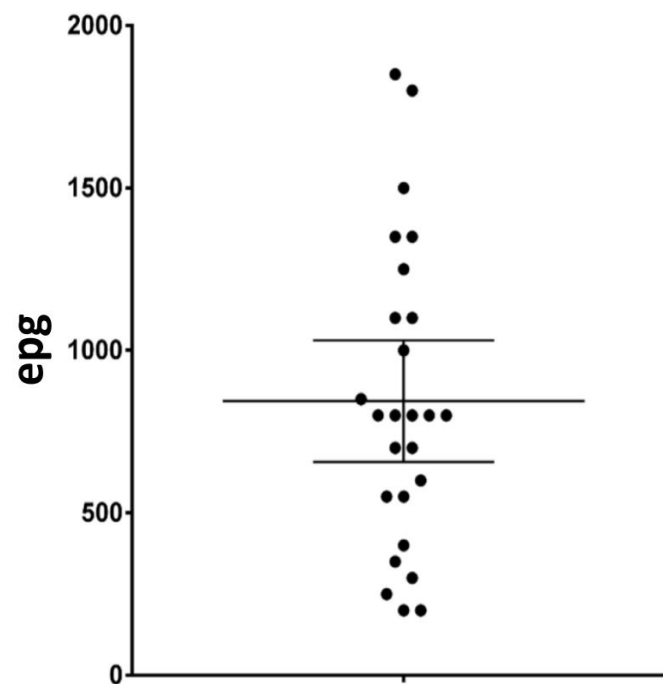


Figure 4. Dispersion of individual values of eggs per gram of feces (epg) of strongyles (STE) obtained in *E. asinus* (n=26) in the District of Colcha, Cusco, determined using the McMaster technique in October 2022. 95% confidence interval

of parasites or from being included in deworming programs. On the other hand, the donkeys of the Peruvian highlands have dense, long fur, so we cannot rule out a bias when visually judging body condition, which is subjective.

5. Conclusion

Donkeys of the district of Colcha, Cusco, have a high frequency of cyathostomes; in addition to *Parascaris* spp. and *F. hepatica*, this species should be included in the epidemiological surveillance of trematode zoonosis.




Figure 5. Infective larvae (L3) of cyathostomes (subfamily Cyathostominae) obtained using the Baermann technique

Note: Their respective measurements are in micrometers.

This study constitutes the second report of *F. hepatica* in donkeys in Peru and the first one for the Southern region. Further studies in more districts, with larger numbers of animals sampled, are recommended to better assess the gastrointestinal parasite fauna in donkeys from Southern Peru.

Acknowledgements

The authors appreciate the support of the Cabieses Scholarship 2021 of the General Directorate for Research, [Southern Scientific University](#), Lima, Peru.

Compliance with ethical guidelines

All procedures used for animal sampling were reviewed and approved by the Institutional Committee on Ethics in Animal Research and Biodiversity of the [Southern Scientific University](#), Lima, Peru (Code: 158-CIEI-AB-CIENTÍFICA-2021). All owners were informed about the research and the procedures that would be performed on their animals. To ensure clear and effective communication, a local translator was provided for illiterate and Quechua-speaking individuals, ensuring their understanding and informed consent.

Data availability

The data that support the findings of this study are available on request from the corresponding author, due to privacy restrictions

Funding

This study was funded by the Cabieses Scholarship 2021 (Register N° 596-2021-PRE16) of the General Directorate for Research, [Southern Scientific University](#), Lima, Peru. Laboratory equipment was provided by the Laboratory of Parasitology, Faculty of Animal Science, [National Agrarian University La Molina](#), Lima, Peru.

Authors' contributions

Conceptualization, study design, and project administration: Daniel A. Zárate-Rendón; Data acquisition and supervision: Milena Alison Villafuerte Pancorbo and Ines Milagros Limaymanta Zavala; Statistical analysis: Ines Milagros Limaymanta Zavala; Data analysis, administrative support, and writing: Milena Alison Villafuerte Pancorbo and Daniel A. Zárate-Rendón.

Conflict of interest

The authors declared no conflict of interest.

References

- [1] Starkey P, Starkey M. Regional and world trends in donkey populations. In: Starkey P, Fielding D, editors. Donkeys, people and development: A resource book of the Animal Traction Network for Eastern and Southern Africa (ATNESA). 2000. [\[Link\]](#)
- [2] Wannas H, Dawood A, Gassem A. Prevalence of gastrointestinal parasites in horses and donkeys in al diwaniyah governorate. *Al-Qadisiyah J Vet Med Sci.* 2012; 11(1):148-55. [\[Link\]](#)
- [3] Matthews JB. Anthelmintic resistance in equine nematodes. *Int J Parasitol Drugs Drug Resist.* 2014; 4(3):310-5. [\[DOI:10.1016/j.ijpddr.2014.10.003\]](#) [\[PMID\]](#)
- [4] Souto EPF, Dantas VW, Oliveira AM, Garcia DS, Vilela VLR, Neto EGM, et al. Arteritis, aneurysm and thromboembolic colic caused by migration of *Strongylus vulgaris* larvae in equids. *J Equine Vet Sci.* 2025; 152:105650. [\[DOI:10.1016/j.jevs.2025.105650\]](#) [\[PMID\]](#)
- [5] Vargas-Rocha L, Malpartida Aquino E, Murga-Moreno C. Prevalence of trematodes and nematodes in donkeys marketed in the Plaza Pecuaría Iscoconga in the province of Cajamarca, Peru. *Rev Inv Vet Perú.* 2021; 32(3):e18846. [\[DOI:10.15381/rivep.v32i3.18846\]](#)
- [6] Finnerty CA, Bonometti S, Ripley NE, Smith MA, Nielsen MK. Evidence of tapeworm treatment failure on a Central Kentucky Thoroughbred farm. *Equine Vet Educ.* 2024; 36(11):579-85. [\[DOI:10.1111/eve.13950\]](#)
- [7] Salazar M, Zárate D. Relationship between endoparasitism, body condition and blood biochemistry in Peruvian spider monkeys (*Ateles chamek*) at the Taricaya Rescue Center, Madre de Dios, Peru. *Rev Investig Vet Perú.* 2021; 32(2):e20017. [\[DOI:10.15381/rivep.v32i2.20017\]](#)
- [8] Puicón V, Chávez J, Gutiérrez G, Sánchez D, More M, Zárate D. Prevalence of gastrointestinal nematodes in alpacas and sheep from two communal cooperatives in the Pasco region, Peru. *Rev Investig Vet Perú.* 2021; 29(4):1440-8. [\[DOI:10.15381/rivep.v29i4.15189\]](#)
- [9] Zárate-Rendón DA, Briones-Montero A, Huaraca-Oré NA, Veirano GS, Leveck B, Geldhof P. Comparison of the therapeutic efficacy of five anthelmintics against natural *Fasciola hepatica* infections in dairy cattle from the Mantaro Valley, Peru. *Vet Parasitol Reg Stud Reports.* 2023; 38:100827. [\[DOI:10.1016/j.vprsr.2022.100827\]](#) [\[PMID\]](#)
- [10] Amer MM, Desouky AY, Helmy NM, Abdou AM, Sorour SS. Identifying 3rd larval stages of common strongylid and non-strongylid nematodes (class: Nematoda) infecting Egyptian equines based on morphometric analysis. *BMC Vet Res.* 2022; 18(1):432. [\[DOI:10.1186/s12917-022-03526-8\]](#) [\[PMID\]](#)
- [11] Yonairo HB, Jheremmys VA, Carlos EH, Luis CV. Frequency of gastrointestinal parasites in Creole donkeys (*Equus africanus asinus*) in the department of Córdoba, Colombia. *Rev Colomb Cienc Anim.* 2016; 8(2):159-66. [\[DOI:10.24188/recia.v8.n2.2016.183\]](#)
- [12] Rivero-Pérez N, Zaragoza-Bastida A, Vega-Sánchez V, Olave-Leyva I, Vega-Angeles J, Peña-Jiménez F. Identification of main gastrointestinal parasites in donkeys of Tulancingo Valley. *Abanico vet.* 2018; 8(1):47-52. [\[DOI:10.21929/abavet2018.81.4\]](#)

- [13] Kebede IA, Gebremeskel HF, Bandaw T, Ahmed AD. Prevalence and risk factors of parasitic gastrointestinal nematode infections of donkeys in southern Ethiopia. *J Parasitol Res.* 2024; 2024:3073173. [DOI:10.1155/2024/3073173] [PMID]
- [14] Nielsen MK, Banahan M, Kaplan RM. Importation of macrocyclic lactone resistant cyathostomins on a US thoroughbred farm. *Int J Parasitol Drugs Drug Resist.* 2020; 14:99-104. [DOI:10.1016/j.ijpddr.2020.09.004] [PMID]
- [15] Mulwa N, Githigia S, Karanja D, Mbae C, Zeyhle E, Mulinge E, et al. Prevalence and intensity of gastrointestinal parasites in donkeys in selected abattoirs in Kenya. *Scientifica.* 2020; 2020(1):5672140. [DOI:10.1155/2020/5672140]
- [16] Cain JL, Nielsen MK. The equine ascarids: Resuscitating historic model organisms for modern purposes. *Parasitol Res.* 2022; 121(10):2775-91. [DOI:10.1007/s00436-022-07627-z] [PMID]
- [17] Rázuri Munayco B, Murga-Moreno C, Vargas-Rocha L, Rojas Moncada J, Torrel Pajares T. First report of *Fasciola hepatica* in creole horses from the Northern Andes of Peru. *Ciencia y Tecnología Agropecuaria.* 2023; 24(3). [link]
- [18] Mas-Coma S, Buchon P, Funatsu IR, Angles R, Mas-Bargues C, Artigas P, et al. Donkey Fascioliasis Within a One Health Control Action: Transmission Capacity, Field Epidemiology, and Reservoir Role in a Human Hyperendemic Area. *Front Vet Sci.* 2020; 7:591384. [DOI:10.3389/fvets.2020.591384] [PMID]
- [19] National Institute of Statistics and Informatics (INEI). IV National Agricultural Census. Lima» INEI; 2012. [Link]
- [20] Ministry of Health of Peru. Technical health standard for the surveillance, prevention, and control of human fascioliasis in Peru (NTS No. 148-MINSA/DIGIESP-V.01). Lima: General Directorate of Strategic Interventions in Public Health, Directorate of Prevention and Control of Metaxenic Infections and Zoonoses; 2019. [Link]
- [21] Morales G, Pino LA, Sandoval S, Jiménez D, Morales J. Relationship between body condition and level of parasitic infestation in grazing cattle as a criterion for selective anthelmintic treatment. *Rev Inv Vet Perú.* 2012; 23(1):80-9. [DOI:10.15381/rivep.v23i1.886]

This Page Intentionally Left Blank