Archives of Razi Institute Journal
"Arch. Razi Inst."

Journal Homepage: https://archrazi.areeo.ac.ir/

Research Paper

Effect of Molecularly Characterized *Aspergillus flavus* Mycotoxin Found on Pellet Feed on Intestinal System on Poultry

Mustafa Hadi Hamid[1], Zeinab A. M. Al-tememe[1], Doaa Adil Rabee[2*]

1. Department of Animal Production, Faculty of Agriculture, University of Kerbala, Iraq.
2. Department of Food Sciences, Faculty of Agriculture, University of Kerbala, Iraq.

Use your device to scan and read the article online

How to cite this article Hamid MH, Al-tememe ZAM, Rabee DA. Effect of Molecularly Characterized *Aspergillus flavus* Mycotoxin Found on Pellet Feed on Intestinal System on Poultry. Archives of Razi Institute Journal. 2026; 81(3):723-732. https://doi.org/10.32598/ARI.81.3.3922

https://doi.org/10.66224/ARI.81.3.3922

Article info:
Received: 06 Mar 2026
Accepted: 25 Apr 2026
Published: 01 May 2026

Keywords:
Aspergillus flavus, AV nystatin, Polymerase chain reaction (PCR), Pellet feed, Poultry

ABSTRACT

Introduction: This study aimed to isolate *Aspergillus flavus* from pellet poultry feed stored at the Animal Production Department, University of Karbala.

Materials & Methods: Five birds were used in three replicates for each treatment, in addition to a control group that was given only sterile distilled water for 45 days. The fungal isolate was identified based on morphological characteristics and confirmed through molecular techniques and sequencing.

Results: The identified *A. flavus* strain was registered in the GenBank under the accession number PV163084.1, marking a significant contribution as a documented Iraqi isolate. Experimental exposure of poultry to the produced mycotoxins revealed notable histopathological alterations in the small intestine. These changes included damage to the intestinal villi, characterized by a reduction in their number and height, as well as narrowing of the intestinal lumen, in contrast to the control group, which exhibited normal intestinal architecture. Therapeutic interventions were evaluated to mitigate the toxic effects. Administration of a medicinal treatment to mycotoxin-exposed poultry resulted in partial restoration of intestinal structure, including increased villus height, enhanced enterocyte development, and heightened activity of endocrine cells within the intestinal crypts. Furthermore, dietary supplementation with clove powder at a concentration of 5 g/kg feed led to improved intestinal morphology, evidenced by increased enterocyte height, infiltration of immune cells, and elevated activity of enteroendocrine cells. Notably, the combined treatment of AV Nystatin (1 mL/liter of drinking water) and clove supplementation demonstrated the most pronounced protective effects. This combination significantly enhanced the height and integrity of intestinal villi, increased enterocyte proliferation, stimulated enteroendocrine cell activity, and promoted mucous gland development.

Conclusion: These findings suggest that natural additives like cloves, especially when combined with antifungal agents, may offer a promising strategy to counteract the deleterious effects of *A. flavus* mycotoxins in poultry.

*** Corresponding Author:**
Doaa Adil Rabee
Address: *Department of Food Sciences, Faculty of Agriculture, University of Kerbala, Iraq.*
E-mail: *Doaa.a@uokerbala.edu.iq*

Copyright © 2026 The Author(s);
This work is licensed under a Creative Commons Attribution-NonCommercial 4.0 International license (https://creativecommons.org/licenses/by-nc/4.0/).
Noncommercial uses of the work are permitted, provided the original work is properly cited.

1. Introduction

Feed is the primary source of energy and nutrients necessary for the growth and health of animals, especially in the poultry and livestock farming sector. The quality and safety of feed are crucial factors in improving the efficiency of animal production and ensuring the safety of animal products intended for human consumption, However, a serious threat facing this vital and important sector is contamination with mycotoxins resulting from fodder contamination of feed.[1, 2]. Mycotoxins are toxic chemical compounds are produced by specific types of fungi during their growing on food and feed material [3]. The problem of mycotoxins is exacerbated by several environmental and climatic conditions, including: high temperatures and increased moisture during storage or cultivation, which provide a suitable environment for fungal growth and reproduction. Improper storage methods and transportation under unsuitable conditions are also significant factors contributing to feed contamination with these toxins.

Aspergillus spp. is one of the most prominent fungal genera responsible for mycotoxins production. The *Aspergillus flavus* fungus, a member of the order Eurotiales and the class Ascomycota, the genus *Aspergillus* has over 60 species known to cause infections in humans and animals, is one of the most widespread and dangerous fungal species. The genus *Aspergillus* comprises more than 60 species known to cause infections in humans and animals. *A. flavus* produces a group of toxins, the most important of which are aflatoxins, and it has been found abundantly in poultry feed contaminated with fungi [4]. Poultry feeds mainly consist of ingredients rich in energy & protein, including corn, peanuts, rice and cottonseed, which create an ideal environment for the growth of *A. flavus* [5]. Generally, this particular strain is responsible to the production of aflatoxin B1 and B2. Aflatoxin B1 (AFB1) is a major concern due to its known links to cancer, genetic mutations, and congenital defects [6]. According to the International Agency for Research on Cancer (IARC), aflatoxins are classified as group 1 human carcinogen. They also have serious effects on animal health, leading to impaired immunity, reduced feed conversion, liver damage, and, in severe cases, death [7].

Chronic exposure to aflatoxins poses a risk to more than five billion people living in developing countries through the consumption of contaminated food and feed [8]. Furthermore, Africa loses about 700 million USD annually as a result of contamination of agricultural commodities with mycotoxins [9]. Among the various mycotoxins, aflatoxins are considered the most important and dangerous mycotoxins that directly affect the liver [10]. About 25% of food intended for human consumption and animal feed is affected by fungal contamination, which leads to huge economic losses in the animal and agricultural production sectors [11]. *A. flavus* and the toxins it produces represent a major challenge in animal nutrition. Therefore, managing these contaminants requires integrated strategies that include prevention, detection, and rapid intervention to maintain feed quality, animal health, and, consequently, the safety of human consumers. The main objective of this study was to isolate the *A. flavus* fungus from pelleted poultry feed stored in the Animal Production Department, University of Karbala, and to diagnose it morphologically and partially, in addition to understanding the effect of the fungal toxin on intestinal tissues.

2. Materials and Methods

2.1. Isolation

Samples of pelleted feed were collected for laboratory isolation from the local poultry feed storehouse at the Animal Production Department, University of Karbala. Feed samples were taken randomly, with each sample weighing 200 g. Samples of each type were mixed, and a portion of them was taken for fungal isolation. A quantity of 0.5 g of pelleted feed was spread onto sterile 9-cm Petri dishes containing Potato Dextrose Agar (PDA) medium. The medium was prepared by dissolving 42 g of medium in one liter of distilled water.

Chloramphenicol (250 mg/L) was added to the medium before it solidified. Prior to this, the medium had been sterilized by autoclaving at 121 ˚C and 15 psi for 20 minutes. The plates were incubated at 25±2 ˚C for 5–7 days until fungal growth appears [12]. The fungal colonies that developed on PDA were purified using the hyphal end transfer technique. Growing fungal growths were at first identified according to the shape of the colony, reproductive structures and spores of each fungus. After that colonies were purified using the hyphal tip transfer technique for the purpose of final diagnosis, following the approved taxonomic keys for genus and species order. Then, the diagnosis of one of the fungal species under study was further confirmed by polymerase chain reaction (PCR) and nucleotide sequence determination at the Asco Learning Center, Baghdad [13].

A fungal isolate known to occur in animal feed and capable of producing mycotoxins was selected for further study [14, 15]. Potato Dextrose Broth (PDB) liquid

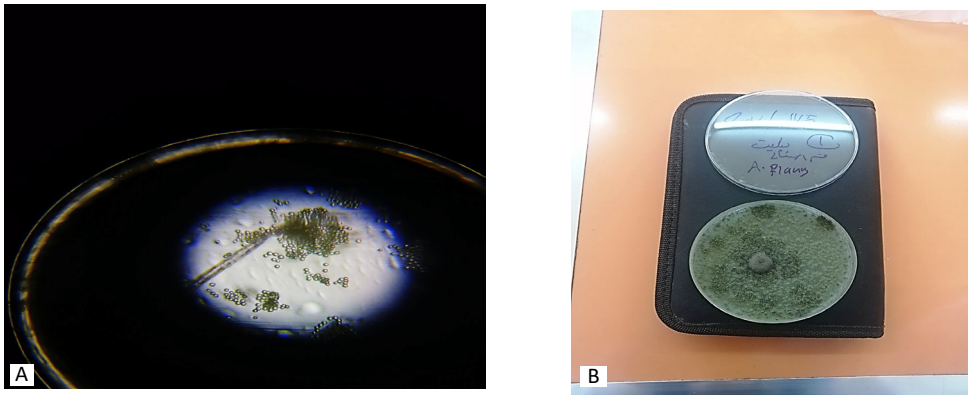

Figure 1. A) *A. flavus* colony on (PDA), B) The sporophyte of *A. flavus* is undivided, the conidiophore was unbranched and ends in a head bearing conidia in chains

medium was prepared by adding chloramphenicol at a concentration of 250 mg/L. The medium was distributed into 250 mL beakers. After sterilization and cooling to room temperature, each beaker was inoculated, in triplicate,with 5-mm diameter discs of the selected fungal isolate. The cultures were incubated at 25±2 ˚C for two weeks. For the extraction, the contents of each beaker were mixed separately for three minutes using an electric mixer. The mixture was then filtered under vacuum with a Buchner funnel. The resulting filtrate was passed through a 0.45-micron bacterial filter to remove any remaining cells. The final extracts were collected in sterile glass bottles and stored in a refrigerator for up to 24 hours before use [12]. All procedures involving animals were performed in compliance with institutional ethical standards and approved by the Animal Ethics Committee of the University of Kerbala.

Broiler chicks of one type were obtained from a private hatchery in province of Karbala Province. A poultry house was specially prepared with all the necessary equipment for raising poultry. Standard management and preventive health programs were implemented throughout the experimental period to ensure proper care and protection against diseases. The mycotoxin extract was administered orally to the chicks at a dose of 1 mL per 50 g of body weight. Each treatment consisted of five birds with three replicates, while the control group received only sterile distilled water. The experiment lasted for forty-five days, during which food and water were provided free of charge until the end of the research period. At the conclusion of the experiment, the small intestine was excised and then preserved in 10% neutral buffered formalin for histological examination.

2.2. Experiment design

1. Control group: Chicks were fed a standard feed without any additives.

2. Mycotoxin group: Chicks were fed a standard diet supplemented with mycotoxin.

3. Mycotoxin+AV Nystatin group: Chicks were fed a standard diet with mycotoxin+AV Nystatin (1 mL/liter of water).

4. Mycotoxin+clove group: Chicks were fed a standard feed with mycotoxin and cloves.

5. Mycotoxin+clove+AV Nystatin group: Chicks were fed a standard diet supplemented with mycotoxin+ cloves+AV Nystatin (1 mL/liter of water).

3. Results

3.1. Isolation and morphological and microscopic description of *A. flavas*

The isolation results showed the presence of A. flavus pathogens in Pelleted poultry feed (Figure 1). Colonies appeared cottony white and rapidly changed to yellowish- green or light olive- green. The colony texture was cottony or woolly at first, then becomes granular with age and increased spore production. Colonies grow rapidly, were round and flat, and sometimes have radial wrinkles. The conidiophores: were long, colorless,and rough-textured, arising from specialized basal cells called “foot cells”. The vesicle, located at the end of the sporophyte, is round or oval in shape and measured approximately between 1800 and 2000 µm. in diameter. Metulae and Phialides were arranged in one or two rows of cells on the vesicle, a characteristic feature that distinguishes this spe-

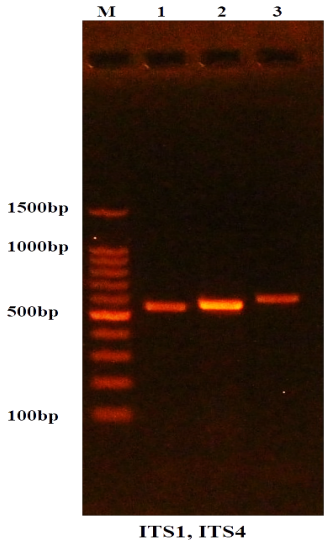

Figure 2. The resulting bands from electrophoresis and of sizes (nitrogenous base pair, pb) are fixed on left side subordinate DNA ladder



Figure 3. The phylogenetic tree shows the genetic relationship between the *A. flavus* isolated in this experiment and other isolates of the same fungus previously registered at the NCBI

Note: The genetic kinship of the identified fungal isolates was studied through DNA nucleotide sequence analysis. The obtained sequence was submitted to the Gene Bank to determine the extent of genetic kinship between the identified fungal strains and other strains available in the NCBI database. The Iraqi isolate was registered under the accession number PV163084.1. Based on the sequence analysis results, it is clear that the fungus isolated in this study is genetically distinct from other fungi previously recorded at the NCBI. PCR technology plays a vital role in identifying fungi with unparalleled accuracy and speed. Unlike traditional methods, which rely on microscopic examination and phenotypic description and may be inaccurate and time-consuming, PCR enables fungal identification through DNA analysis [18] explained that many fungal species have been identified using nucleotide sequencing technology. For example, *Aspergillus versicolor* has been isolated and identified from woods and also fish samples [19]. Similarly, fungal isolates from plants have been identified using molecular sequencing techniques, as reported by [20].

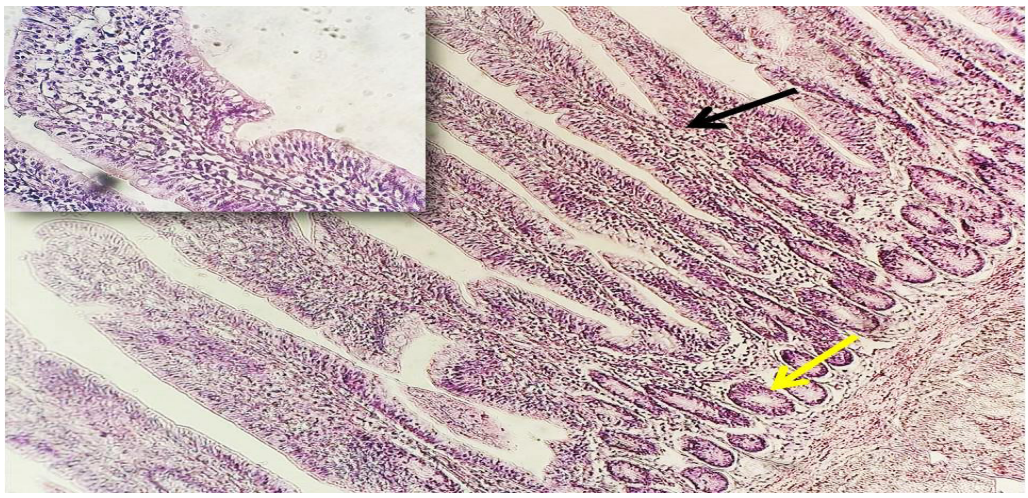

Figure 4. Photography of intestine small intestine photography demonstrates the damage in intestinal villi (black arrow) (H&E stain)

Note: The intestinal crypts decrease in number and thinner in lumen (yellow arrow).

cies from some other *Aspergillus* species. The conidia are round or oval in shape, rough or very smooth in texture, yellow to yellowish in color, and are gathered in the form of clumps or long chains on the Phialides. Their diameter range from 250-450 µm [17, 18].

3.2. Molecular diagnosis of *A. flavas*

The results of DNA extraction of the fungal isolates under study, followed by after submission its analysis using the PCR technique, demonstrated successful amplification of the target DNA. The PCR_amplified Products-were approximately 1500 base pairs (bp) in size.

The results of the nitrogenous base sequence analysis showed that isolate No. 2 belongs to the fungus *A. flavus*.

3.3. The mycotoxin effect of *A. flavas* on the tissues of the small intestine of poultry is under study

Pathological tissue changes occur as a result of treating poultry with under study toxins resulted in histopathological changes in the small intestine. These changes are represented by damage to the intestinal, including a reduction in their number and a small lumen (Figures 2, 3 and 4). In contrast, the control group, which was not exposed to mycotoxins, exhibited normal intestinal architecture and histological appearance (Figure 5). We note that administration of AV Nystatin (1 ml/L of drink-

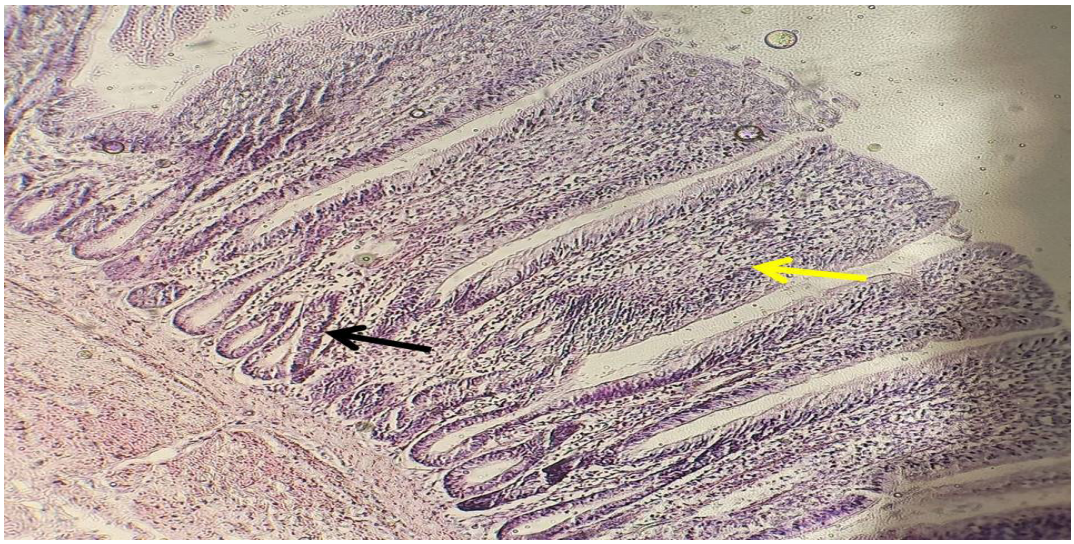

Figure 5. Small intestine photography show the normal state of enterocyte less number of goblet cells (yellow arrow) (H&E stain)

Note: Decrease of mucous cells in intestinal glands.

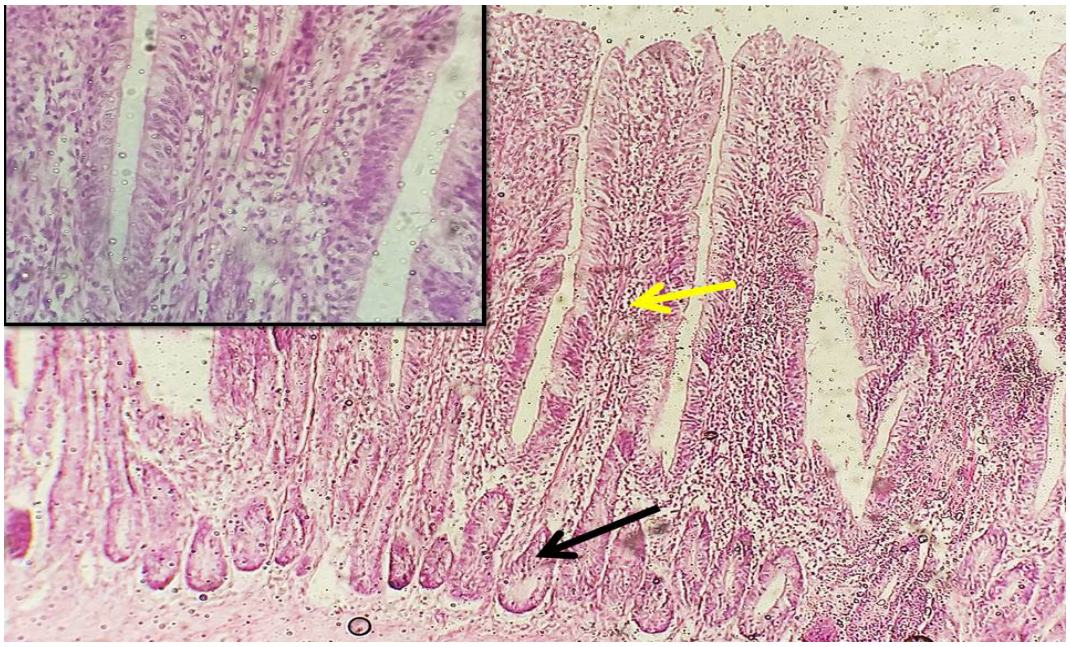

Figure 6. Small intestine photography determines the increase height & enterocyte of intestinal villi (yellow arrow) (H&E stain)

Note: The intestinal crypts crowded & highly activity of endocrine (black arrow).

ing water) to poultry previously exposed to mycotoxins resulted in partial restoration of intestinal morphology. This treatment increased the height of the intestinal villi and enterocytes, while the intestinal crypts appeared more crowded and exhibited increased endocrine cell activity (Figure 6). Supplementation with clove powder at a concentration of 5 g/kg feed in poultry previously exposed to mycotoxins also improved intestinal histology. This treatment increased enterocyte height, enhanced immune cell infiltration, and stimulated the activity of enteroendocrine cells within the intestinal crypts (Figure 7). Furthermore, the combined administration of AV Nystatin (1 ml/L of drinking water) and clove powder to poultry previously exposed to mycotoxins produced

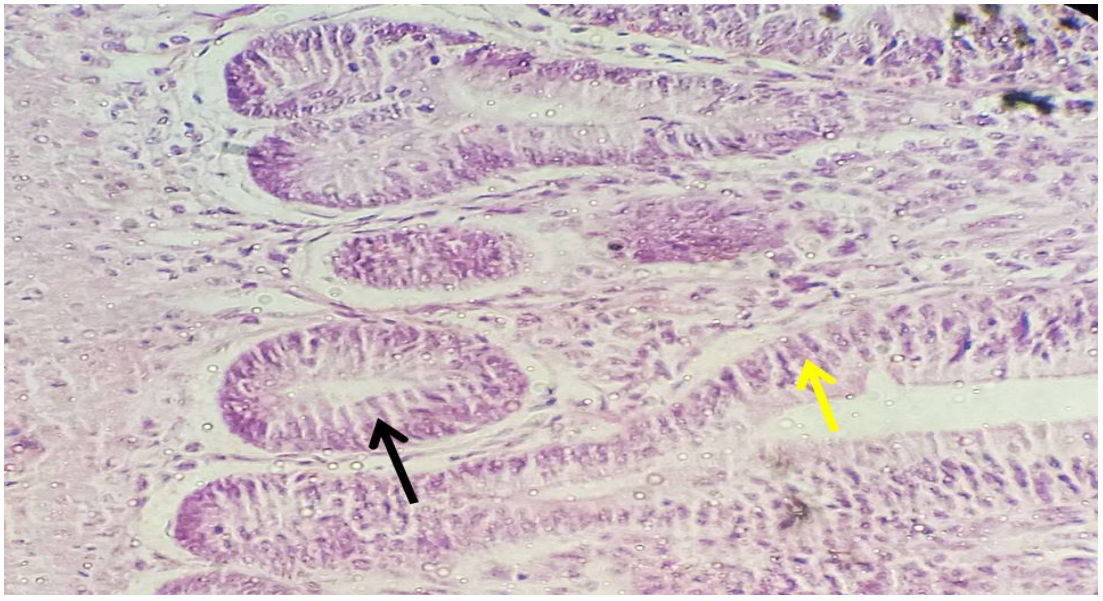

Figure 7. Small intestine photography show the height of enterocyte with increase of infiltration cells (yellow arrow) (H&E stain)

Note: The intestinal crypts highly activity of enteroendocrine (black arrow).

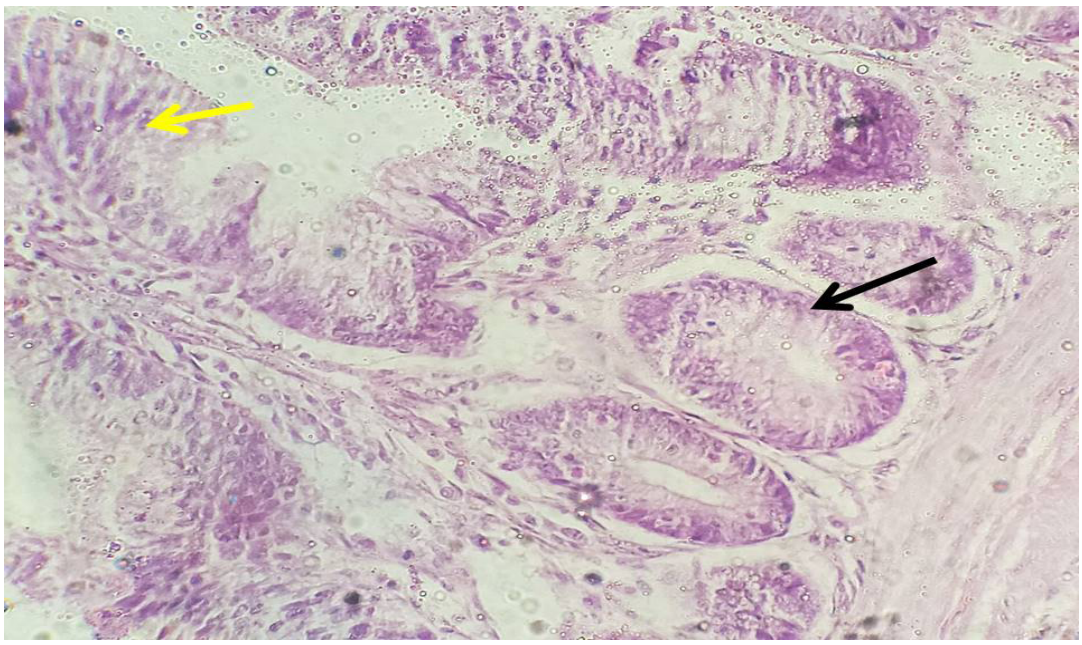

Figure 8. Small intestine photography determines the increase height& enterocyte of intestinal villi (yellow arrow) (H&E stain)

Note. The intestinal crypts highly activity of enteroendocrine cells and increase of mucous glands (black arrow).

the most pronounced protective effects. This combined treatment significantly increased the height of intestinal villi and enterocytes, enhanced the activity of enteroendocrine cells within the intestinal crypts, and promoted the development of mucous glands (Figure 8).

4. Discussion

The results showed that mycotoxins cause clear pathological histological changes in the small intestine of poultry. The intestine is one of the primary target organs of mycotoxins, and damage to intestinal tissues negatively affects nutrient absorption and the overall health of the birds. The results confirm that mycotoxins cause damage to the intestinal villi, such as reduced number and smaller lumen. These observations are consistent with reports indicating that mycotoxins such as aflatoxins and fumonisins cause villus atrophy and crypt hyperplasia, leading to a decrease in the surface area available for the nutrient absorption [21]. Administration of mycotoxins to chicks also produced clear immunomodulatory effects, resulting in increased activity of the intestinal endocrine glands. This increase may be part of an inflammatory response or a hormonal disturbance induced by mycotoxin exposure. The results further indicate that administering cloves has a positive effect on poultry exposed to mycotoxins. This is consistent with the known biological properties of cloves, which contain active compounds such as eugenol that possess antimicrobial, anti-inflammatory, and antioxidant activities [22]. Improved intestinal cell profiles, such as increased enterocyte counts and increased infiltrating cells, may indicate that cloves have helped initiate the repair process of damaged intestinal tissue. Increased mucus production may also be a protective response, as mucus acts as an additional layer of protection against toxin-induced damage. The positive effect of natural plants products in inhibiting the activity of the fungus under study has also been reported previously [23]. An increase in enterocyte and villus height was observed following treatment, representing a positive indicator of intestinal recovery.

Mycotoxins are known to cause atrophy and damage to the intestinal villi, thereby reducing the bird's ability to absorb nutrients. Therefore, the observed increase in the height of intestinal cells (villus height) indicates that the drug has contributed to the repair of damaged tissue and reduce the toxic effects of mycotoxins, enhancing the intestinal absorptive capacity [24]. The presence of congested intestinal crypts and increased endocrine cell activity may represent protective and compensatory response. Congested crypts indicate an increased rate of cell division, which often occurs to rebuild damaged villi. Increased endocrine cell activity may be an immune or hormonal response to help restore balance in the intestine. These results are consistent with research indicating that anti-mycotoxin treatments stimulate the body's natural defense mechanisms [25].

5. Conclusion

The combined treatment consisting of AV Nystatin and clove supplementation produced the most pronounced improvement in intestinal morphology. Significant increases in enterocyte height, endocrine cell activity, and mucous gland development were observed, indicating a synergistic effect between the antifungal treatment and the natural plant additive. This means that cloves not only acted as an antioxidant but may also have enhanced the effectiveness of the treatment used. *A. flavus* was identified morphologically, microscopically, and then molecularly. The sequence was placed in the (NBCI) GenBank data base. Then, chicks were given the innate poison, cloves were added, and the treatment was followed by a histological diagnosis of the small intestines.

Recommendations

It is recommended that future studies utilize a microscope camera equipped with a calibrated measurement scale to accurately determine the length and morphology of intestinal villi during histological examinations.

Acknowledgements

The authors express their sincere gratitude to all individuals who contributed to the successful completion of this research.

Compliance with ethical guidelines

All animal procedures were approved by the Animal Ethics Committee, University of Karbala, Karbala, Iraq (Code: UOK.Agri. No. 4.2025).

Funding

This research did not receive any grant from funding agencies in the public, commercial, or non-profit sectors.

Authors' contributions

Supervision: Mustafa Hadi Hamid; Methodology: Zeinab A.M. Al-tememe; Investigation: Zeinab A.M. Al-tememe and Mustafa Hadi Hamid; Data collection and data analysis: Doaa Adil Rabee; Writing the original draft: Zeinab A.M. Al-tememe; Review and editing: Mustafa Hadi Hamid.

Conflict of interest

The authors declared no conflict of interest.

Data availability

All data generated or analyzed during this study are included in the published article and its supplementary materials.

References

[1] Akinmoladun OF, Fon FN, Nji Q, Adeniji OO, Tangni EK, Njobeh PB. Multiple mycotoxin contamination in livestock feed: implications for animal health, productivity, and food safety. Toxins (Basel). 2025; 17(8):365. [DOI:10.3390/toxins17080365]

[2] Al-Tememe ZAM, Hamid MH, Al-Musodi MF. The effect of the mycotoxins of some fungi isolated from poultry feeds on the relative weight of the liver and gizzard of broiler chicks in different regions of Karbala, Iraq. Open Vet J. 2024; 15(2):1050-5. [DOI:10.5455/OVJ.2025.v15.i2.53] [PMID]

[3] Hassan WH, R Mostafa S, Khalil HA, Abed AH. Detection of aflatoxigenic fungi in poultry feed. J Appl Vet Sci. 2021; 6(2):92-7. [Link]

[4] Varga E, Fodor P, Soros C. Multi-mycotoxin LC-MS/MS method validation and its application to fifty-four wheat flours in Hungary. Food Addit Contam Part A Chem Anal Control Expo Risk Assess. 2021; 38(4):670-80. [DOI:10.1080/19440049.2020.1862424] [PMID]

[5] Agag BI. Mycotoxins in foods and feeds: 1-aflatoxins. Ass. Univ. Bull. Environ. Res. 2004; 7(1):173-205. [Link]

[6] Shi Y, Xu Z, Sun Y, Wang C, Feng J. Effects of two different types of montmorillonite on growth performance and serum profiles of broiler chicks during aflatoxicosis. Turk J Vet Anim Sci. 2009; 33(1):15-20. [DOI:10.3906/vet-0702-32]

[7] Ostry V, Malir F, Toman J, Grosse Y. Mycotoxins as human carcinogens-the IARC Monographs classification. Mycotoxin Res. 2017; 33(1):65-73. [DOI:10.1007/s12550-016-0265-7] [PMID]

[8] Habib MA, Abdu P, Kwanashie CN, Kabir J, Negedu A. Isolation and identification of Aspergillus species from poultry feeds in Kaduna State, Nigeria. Microbiol Res Int. 2015; 3(2):27-32. [Link]

[9] Chilenga C, Mainje M, Watts AG, Munkhuwa V, Ndhlovue B, Machira K. Factors influencing willingness to pay for aflatoxin-safe foods among farmers, traders, and consumers in sub-Saharan Africa: A systematic review. Appl Food Res. 2024; 4(2):100511. [DOI:10.1016/j.afres.2024.100511]

[10] Food and Agriculture Organization of the United Nations, World Health Organization. Safety evaluation of certain mycotoxins in food. Joint FAO/WHO Expert Committee on Food Additives (JECFA) report. Geneva: WHO; 2018. [Link]

[11] Park DL, Njapau H, Boutrif E. Minimizing risks posed by mycotoxins utilizing the HACCP concept. Food Nutr Agric. 1999; 3:49-54. [Link]

[12] Aneja K Experiment in microbiology, plant pathology and biotechnology. New Delhi: New Age International. (P) Limited, Publishers; 2003. [Link]

[13] White TJ, Bruns T, Lee S, Taylor J. Amplification and direct sequencing of fungal ribosomal RNA genes for phylogenetics. In: Innis MA, Gelfand DH, Sninsky JJ, White TJ, editors. PCR protocols: A guide to methods and applications. San Diego: Academic Press; 1990. [DOI:10.1016/B978-0-12-372180-8.50042-1]

[14] Khorrami R, Pooyanmehr M, Nooriyan Soroor ME, Gholami S. Evaluation of Some Aflatoxins in Feed Ingredients of Livestock and Poultry by HPLC Method, A Local Study in Kermanshah Province. Iran J Vet Med. 2022; 16(3):298-310. [DOI:10.22059/ijvm.2022.329690.1005192]

[15] Shokri H. Investigation on mycoflora of poultry breeding houses' air and studying the efficacy of spraying and fumigation on inactivating the airspora. Iran J Vet Med. 2016; 10(1):19-26. [DOI:10.22059/ijvm.2016.57046]

[16] Layton YM. Medically important fungi: A guide to identification. Proc R Soc Med. 1977; 70(5):359. [DOI:10.1177/003591577707000519] [PMCID]

[17] Klich MA. Identification of common Aspergillus species. Utrecht: Centraalbureau voor Schimmelcultures; 2002. [Link]

[18] Al-Tememe ZA, Abdalmoohsin RG, Mohammadali MT, Al-Mosawy MM, Al-Masoudi ZM. Molecular diagnosis of the fungus Sclerotinia sclerotiorum: A causal agent of white rot disease in Solanum melongena L. and its control using zinc oxide nanoparticles. Biopestic Int. 2019; 15(1):51-6. [Link]

[19] Al-Hakeem AM, Al-Tememe ZA, Abd Alssirag M. Morphological and molecular identification of fungi associated with Zuri fish (Pilchard sp.) in Karbala/Iraq. IOP Conf Ser Earth Environ Sci. 2023; 1158(5):052006. [DOI:10.1088/1755-1315/1158/5/052006]

[20] Al-Tememe ZA, Lahuf AA, Kareem AA, Kadhim AA, Al-Mosawy MM. A survey and molecular identification of Aspergillus versicolor causing brown rot on imported spruce (Picea canadensis) wood in Karbala province, Iraq and control using copper boron chromate. IOP Conf Ser Earth Environ Sci. 2019; 388(1):012010. [DOI:10.1088/1755-1315/388/1/012010]

[21] Food and Agriculture Organization of the United Nations. Hazards associated with animal feed. Rome: FAO; 2015. [Link]

[22] Hyderi Z, Abass S, Iswarya D, Saravanan K, Ravi AV. Eugenol: An essential oil with potential antimicrobial and antibiofilm activity against foodborne bacteria. J Stored Prod Res. 2025; 112:102644. [DOI:10.1016/j.jspr.2025.102644]

[23] Moradi M S, Kamkar S, Sharifzadeh A, Hassan J, Shokri H, Abbasi J. The in Vitro Effect of Berberine Sulfate and Berberine Chloride on the Growth and Aflatoxin Production by Aspergillus flavus and Aspergillus parasiticus. Iran J Vet Med. 2024; 18(2):223-32. [DOI:10.32598/IJVM.18.2.1005399]

[24] Riboty R, Huaringa D. Evaluation of two mycotoxin-detoxifying agents in broilers fed naturally contaminated corn with elevated mycotoxin levels. J Appl Poult Res. 2026; 35(1):100644. [DOI:10.1016/j.japr.2025.100644]

[25] Barati M, Chamani M, Mousavi SN, Hoseini SA, Taj Abadi Ebrahimi M. Effects of biological and mineral compounds in aflatoxin-contaminated diets on blood parameters and immune response of broiler chickens. J Appl Anim Res. 2018; 46(1):707-13. [DOI:10.1080/09712119.2017.1388243]

This Page Intentionally Left Blank