Archives of Razi Institute Journal
"Arch. Razi Inst."

Journal Homepage: https://archrazi.areeo.ac.ir/

Research Paper

The Evaluation of Estrogen and Tacrolimus in an Experimental Sciatic Nerve Injury Model Following Bipolar Electrocautery in an Animal Model

Nima Vazir[1], Hamidreza Fattahian[1*], Alireza Jahandideh[1], Pejman Mortazavi[2]

1. Department of Veterinary Clinical Sciences, SR.C., Islamic Azad University, Tehran, Iran.
2. Department of Veterinary Pathobiology, SR.C., Islamic Azad University, Tehran, Iran.

Use your device to scan and read the article online

How to cite this article Vazir N, Fattahian H, Jahandideh A, Mortazavi P. The Evaluation of Estrogen and Tacrolimus in an Experimental Sciatic Nerve Injury Model Following Bipolar Electrocautery in an Animal Model. Archives of Razi Institute Journal. 2026; 81(1):255-264. https://doi.org/10.66224/ARI.81.1.3719

https://doi.org/10.66224/ARI.81.1.3719

Article info:
Received: 19 Oct 2025
Accepted: 10 Dec 2025
Published: 01 Jan 2026

ABSTRACT

Introduction: Iatrogenic peripheral nerve injuries (PNIs) cause neurogenic deficits because of the limited regeneration potential of nerves and scar formation. This study evaluates the effects of tacrolimus and estrogen on sciatic nerve healing following its lesion by bipolar electrocautery in rats.

Materials & Methods: Twenty-five mature female Wistar rats were included in this study. The rats were kept under the same photoperiod 12:12 for one week. The rats were divided into five groups as follows: Sham, DW (distilled water), Tacrolimus (Tac), Estrogen (Est), and Tacrolimus + Estrogen (Tac + Est). All rats were anesthetized, and the left sciatic nerve was cauterized by bipolar electrocautery, except for the rats in the sham group. Treatments were given for 28 days after the injury; on day 28, clinical, electrophysiological, and histopathological evaluations were carried out. The Rota-rod performance test, sciatic functional index (SFI), electromyography (EMG) latency, and toe-out angle (TOA) were carried out for evaluation of functional nerve recovery. Finally, the rats were humanly euthanized and samples of sciatic nerve tissue were submitted for histopathological evaluation on day 28.

Results: There was no statistically significant difference in SFI (P=0.249) among the groups. In the Rota rod tests, the Est group showed significantly greater motor function improvement compared with the DW (distilled water), Tac, and Est + Tac groups (P<0.01). Mean EMG latency in the DW group was significantly longer than in the sham (P<0.001), Tac (P=0.023) and Est + Tac (P=0.012) groups. Axonal swelling and inflammatory cell infiltration were less in the Tac, Est, and Est + Tac groups compared with the DW group (P<0.01). There was no significant difference among the Tac, Est, and Est + Tac groups in EMG latency. Therefore, tacrolimus and estrogen each showed a neuroprotective effect based on histopathological results. Motor function improvement and reduced inflammation were statistically significant in the Est and Tac groups, respectively.

Conclusion: The findings of this investigation did not confirm a significant impact of the combination of estrogen plus tacrolimus compared with the estrogen and tacrolimus groups in functional recovery and inflammation.

Keywords:
Electrocautery, Estrogen, Rat, Sciatic nerve, Tacrolimus

*** Corresponding Author:**
Hamidreza Fattahian, Assistant Professor.
Address: *Department of Veterinary Clinical Sciences, SR.C., Islamic Azad University, Tehran, Iran.*
Tel: *+98 (912) 2194580*
E-mail: *hamidrezafattahian@yahoo.com*

Copyright © 2026 The Author(s);
This work is licensed under a Creative Commons Attribution-NonCommercial 4.0 International license(https://creativecommons.org/licenses/by-nc/4.0/).
Noncommercial uses of the work are permitted, provided the original work is properly cited.

1. Introduction

Iatrogenic peripheral nerve injuries (PNIs), a serious condition frequently leading to long-term functional deficits even with improvements in surgical techniques, have become a major problem in clinical neurology and veterinary medicine [1]. Scar formation often limits functional recovery by blocking the process of neural regeneration and myelination [2]. The type and degree of the damage, patient age, lesion location, acute or chronic trauma, surgical techniques, and biomaterials used in the healing process determine the outcome of peripheral nerve restoration [1]. The main causes of these injuries are motor vehicle accidents, occupational injuries, trauma connected to combat, iatrogenic surgical procedures, such as electro-cauterization, anesthesia problems, and tumor resections [3]. Electrocautery is sometimes used to destroy nerves in the treatment of chronic sensory nerve pain that does not respond to medication.

Although PNIs are not fatal, they greatly lower patients' quality of life. Many therapeutic agents and procedures have been investigated to improve nerve regeneration and reduce scar formation [4]. Recent research has led to promising developments in tissue engineering, 3D biomaterials, gene therapy, stem cell research, and pharmacological approaches and surgery [5]. Despite many achievements, complete restoration of motor, sensory, or autonomic function has not yet been achieved [5]. Medicines have always been the focus of attention due to their lower cost and economic considerations.

Tacrolimus and estrogen are two medicines that are of interest due to their neuroprotective and neuroregenerative properties [6]. Tacrolimus is widely used in immunosuppressive treatment for organ transplantation, and it also has a neuroprotective role [6]. Tacrolimus exerts its effects via increasing axonal regeneration, stimulating Schwann cell proliferation, and acceleration of nerve elongation [7]. Estrogen, as an anabolic hormone, has a neuroprotective effect by controlling gene expression, improving neuronal stability, preserving neurons and glial cells after trauma, and accelerating angiogenesis and neurogenesis [8]. Although many studies on the effects of these drugs are being conducted, none of them have investigated their combined effect on functional and histopathological changes in an experimental model of peripheral nerve damage by bipolar electrocautery. The aim of this study was to evaluate the effects of estrogen and tacrolimus administration alone or in combination on sciatic nerve regeneration and functional recovery following experimental bipolar electro-cauterization of the nerve in rats.

2. Materials and Methods

All experimental procedures were approved by the Research Ethics Committee of the Islamic Azad University, Science and Research Branch.

2.1. Animals

Twenty-five female Wistar rats weighing 250±25 g were used in this study. The animals were housed in specialized rat cages for acclimatization. They were kept under controlled conditions, including a stable temperature of 23±3 ˚C, humidity of 50±5%, and a 12:12-hour light-dark cycle. All animals had ad libitum access to fresh tap water and a standard rat pellet diet (Behaver Co., Tehran, Iran).

2.2. Surgical procedure

All rats were randomly divided into five groups as follows: sham, distilled water (DW), estrogen (Est), tacrolimus (Tac), and estrogen + tacrolimus (Tac + Est) groups. All rats were anesthetized using a combination of medetomidine (90 µg/kg, Syva, IM, Leon, Spain) and ketamine 10% (20 mg/kg, IM, Alfasan, Warburg, Germany). After anesthesia induction, The left pelvic limb of all rats was clipped and prepared surgically with an antiseptic agent. After positioning the rats on right lateral recumbency, a two-cm skin incision was made on the lateral side of the left pelvic limb. Then the biceps femoris muscle was dissected for sciatic nerve exposure under an operative microscope (Topcon OMS 90, Tokyo, Japan). Three watts of power were applied to the left sciatic nerve of the affected limb using the bipolar electrocautery mode (Kavandish System Company, Tehran, Iran) except for the rats in the sham group. A 6-0 nylon suture (Suppa, Tehran, Iran) was placed on the biceps femoris fascia adjacent to the lesion to mark the injury site. Then the muscular layer and skin were sutured with 5-0 polyglactin 910 and 5-0 nylon suture materials (Suppa, Tehran, Iran) by simple continuous and simple interrupted patterns, respectively. Meloxicam (1 mg/Kg, s.c., Razak pharmaceutical labs Co., Tehran, Iran), and enrofloxacin (10 mg/Kg, i.m., laboratorios HIPRA, Girona, Spain) were injected post-operatively to all rats for one and three days as analgesic and antibiotic therapy, respectively. From day zero to 28, rats of the sham group did not receive any medicine; the DW group received distilled water (s.c., Shahid Qazi, Tabriz, Iran), in the same volume as estrogen, Est group received estrogen (4 mg/kg, s.c., Tran hormone, Tehran, Iran); Tac group received tacrolimus (5 mg/kg, p.o., Zahravi Pharmaceutical Co., Tehran, Iran) and Est + Tac group received estrogen and tacrolimus simultaneously via the same route and dosage.

2.3. Rota-rod performance test

The Rota-rod apparatus is used for assessment of motor disabilities during functional recovery (Tajhiz gostar omid Iranian, Tehran, Iran). This test was carried out on day 28 postsurgically. This device consists of four rods (9 cm in width, 6 cm in diameter, and 20 cm in height) which were separated by a plastic sheet. The machine speed was adjusted to 15 rotations per minute, and the test was measured for 3 minutes. The third fall of every rat was recorded by a sensor under the rods, and then the times were compared with each other.

2.4. Sciatic functional index (SFI)

SFI was performed on day 28 to evaluate motor functional recovery. For SFI assessment, the pelvic paws of the rats were coated with ink and the rats walked along a 100 cm corridor lined with white paper. At least three clear footprints of each rat were recorded, and paw print measurements were utilized to calculate SFI using the Equation 1:

1. $SFI = -38.8\ [(EPL - NPL) / NPL] + 109.5\ [(ETS - NTS) / NTS] + 13.3\ [EIT - (NIT / NIT)] – 8.8$

, in which EPL is experimental (injured) paw length, NPL is normal paw length, ETS is experimental toe spread (distance between the first and fifth toes), NTS is normal toe spread, EIT is experimental intermediary toe spread (distance between the second and fourth toes), and NIT is normal intermediary toe spread. An SFI of zero indicates normal function, while an SFI of -100 represents complete loss of function.

2.5. Toe out angle (TOA)

External rotation of the leg is assessed with TOA, which can show functional improvement of the sciatic nerve. The rats were placed on a glass platform (30×21 cm) and were surrounded by barriers to limit excessive movement. The plantar aspect of the paws was photographed by a camera (Apple iPhone 12 Pro Max, United States) which was fixed under the glass and at a defined distance. Then, the angle between the direction of progression and a reference line was measured. A reference line is defined anatomically from the calcaneus to the tip of the third digit. Angles of the affected and contralateral limb were recorded and compared within and between groups.

2.6. Electromyography

On day 28, the rats were sedated, and the affected sciatic nerve of the left pelvic limb was expose using the procedure mentioned in the surgical methods; then, the curved stimulus electrode (e Pulse, Science Beam, Tehran, Iran) was located about 10 mm proximal to the trifurcation of the sciatic nerve at the cauterized site, which was determined by a 6-0 nylon suture as a marker. The distal part of the electrode was inserted longitudinally into the belly of the extensor digitorum longus muscle (EDLM), and the proximal part of the electrode was inserted longitudinally into the belly of the gastrocnemius muscle. The characteristics of the stimulating waves included a 1000 mA amplitude, a 0.2 Hz frequency for 100 seconds, and 20 stimulations with the electrodes (e Wave, Science Beam, Tehran, Iran). Compound muscle action potential (CMAP) recording in the gastrocnemius muscle, which contains the tibial nerve compartment, and CMAP recording in the extensor digitorum longus muscle, which contains the fibular nerve compartment, after this stimulation, were saved by a computer program (e Trace Analysis, Tehran, Iran). Latency time (milliseconds) is the time between nerve stimulation and muscle response. A delayed response indicates a higher level of nerve damage and poorer healing, whereas a shorter latency indicates a lower level of damage and greater nerve regeneration. In all groups, electromyograms were recorded, and the latency time was compared among the groups.

2.7. Histopathological evaluation

All rats of each group were euthanized on day 28 using an overdose of anesthetic, humanely. The sciatic nerve of all rats was excised for histopathological analysis. All tissue samples were fixed in 10% buffered formalin, embedded in paraffin, and sectioned at a thickness of 6 µm at the lesion site for hematoxylin & eosin (H&E), Masson's trichrome, and toluidine blue staining.

Perineurium formation, axonal swelling, axon count, and inflammatory cell infiltration were studied by two blinded pathologists.

2.8. Statistical analysis

All data were recorded as Mean±SD. Data were analyzed using SPSS software (version 26.0, Chicago, Illinois, USA). The comparison between groups was analyzed using one-way ANOVA, and statistical significance was determined at $P<0.03$.

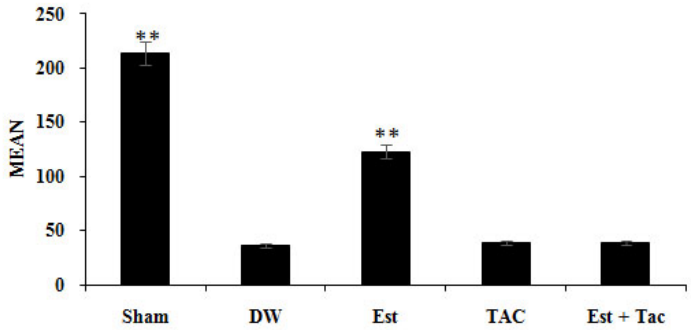

Figure 1. Comparison of mean rota-rod values among the studied groups

Note: The sham group had significantly greater rota-rod performance than that of the other groups (P<0.01). The mean performance of the Est group was significantly higher than that of the DW, Tac, and Est + Tac groups (P<0.01).

3. Results

All rats tolerated anesthesia and survived until the end of the study. No infection or wound dehiscence was observed at the surgical site. Neurological deficits were seen in the left pelvic limb of all rats except rats in the sham group after bipolar electrocauterization. Significant muscular atrophy was observed in the left pelvic limb of all rats except those in the sham group compared with the right pelvic limb.

3.1. Rota-rod performance test

The one-way ANOVA revealed a statistically significant difference among the studied groups in terms of the rota-rod value ($F_{4, 20}$=163.26, P<0.001). Subsequent analysis using the Games-Howell test showed that the mean rota-rod performance in the sham group was significantly greater than in the other groups (P<0.001). Furthermore, the mean rota-rod performance in the Est group was significantly greater than that in the DW, Tac, and Est + Tac groups (P<0.01). No significant differences were found in the other comparisons (P>0.05) (Figure 1).

3.2. SFI

Based on the one-way ANOVA data, no significant difference was indicated among the studied groups regarding the SFI value ($F_{3, 16}$=1.51, P=0.249). Furthermore, the Games-Howell test analysis indicated that the mean SFI value in the DW group was significantly higher than that of the sham group (P=0.021) and the Est group (P=0.032) (Figure 2).

3.3. TOA

The ANOVA test results indicated no statistically significant difference among the TOA means across the studied groups ($F_{4, 20}$=0.47, P=0.755) (Table 1).

3.4. Electromyography (EMG)

The one-way ANOVA results revealed a statistically significant difference among the studied groups in terms of the EMG latency value ($F_{4, 20}$=21.15, P<0.001). The Games-Howell test results indicated that the mean EMG latency in the DW group was significantly higher than that of the sham group (P<0.001), the Tac group

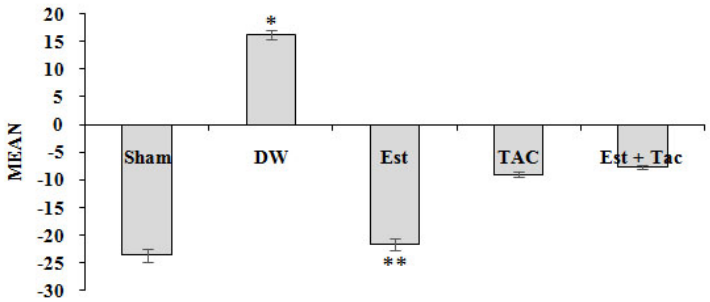

Figure 2. Comparison of mean SFI values among the studied groups

Note: The mean SFI in the DW group did not show any significant difference compared with the sham group and the Est group ($F_{3, 16}$=1.51, P=0.249).

Table 1. ANOVA results for comparing TOA among the study groups

Variable	Mean±SD					ANOVA	Post Hoc†
	Sham n=5	DW n=5	Est n=5	TAC n=5	Est+Tac n=5		
TOA	26.5±13.01	20±3.53	22.60±5.77	18.5±22.81	27.80±10.87	$F_{(4,20)}$=47, P=0.755	Sham=DW Sham=Est Sham= Tac Sham=Est+Tac DW=Est DW=Tac DW=Est+Tac Est=Tac Est=Est+Tac Tac=Est+Tac

Note: M=Mean, SD= Standard Deviation

†=Pairwise comparison for five group; if the Leven's test for homogeneity of variance was significant, Games- Howell was used as the post-hoc test; If not, Bonferroni was used

(P=0.023), and the Est+Tac group (P=0.012). Furthermore, the mean EMG latency in the Est group and the Est+Tac group was significantly longer than that of the sham group (P<0.05) (Figure 3).

3.5. Histopathological study

The perineurium is fully regenerated in all treatment groups, with no statistically significant differences in its regeneration among the groups (P=1.00). No inflammatory cells were detected in any of the rats in the sham group. Rats in the DW group showed a moderate grade of inflammatory cells, with prevalence between 50% and 75%. In the Est group, a mild grade of inflammatory cells (between 25% and 50%) was observed in three rats, while two rats exhibited a very mild grade (less than 25%). Similarly, in the Tac group, two rats exhibited a mild grade (between 25% and 50%) of inflammatory cells, and three rats showed a very mild grade (less than 25%). For the Est+Tac group, a moderate grade of inflammatory cells was noted in two rats, and a very mild grade (less than 25%) was observed in three rats. The results from the Mann-Whitney U test demonstrated that the grade of inflammatory cells in the sham group was significantly different from the other groups (P<0.01). No axonal swelling was observed in any of the rats in the sham group. In the DW group, moderate axonal swelling (between 50% and 75%) was identified in three rats, while mild swelling (between 25% and 50%) was detected in two rats. In the Est group, three rats exhibited mild axonal swelling (between 25% and 50%), and two rats showed very mild swelling (less than 25%). In the Tac group, mild axonal swelling (between 25% and 50%) was observed in two rats, and very mild swelling (less than 25%) was observed in three rats. Lastly, in the Est+Tac group, mild axonal swelling (between 25% and 50%) was noted in three rats, whereas very mild swelling (less than 25%) was observed in two rats. The Mann-Whitney U test indicated that the sham group demonstrated significantly lower levels of axonal swelling compared with the other groups (P<0.01). In terms of the average number of axons per field, all rats in the sham group showed a count similar to that of the normal nerve. The average number of axons in all five rats in the DW group was 50% of the normal nerve. For the Est and Tac groups, the average axon count was 75% of the nor-

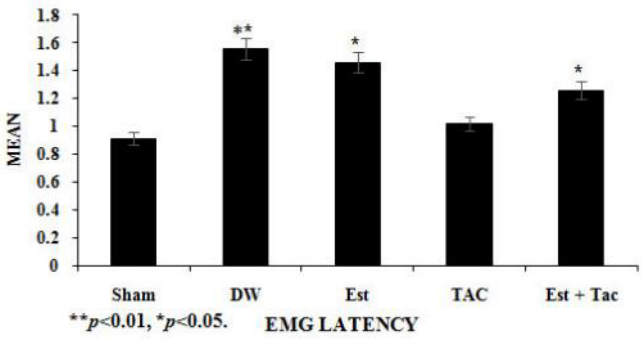

Figure 3. Comparison of mean EMG latency values among the studied groups

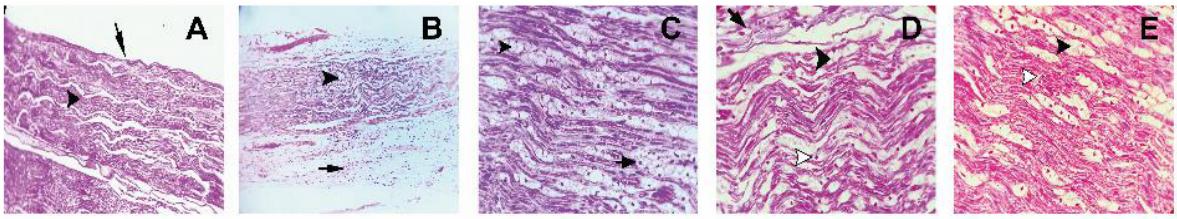

Figure 4. Longitudinal section of the sciatic nerve with hematoxylin and eosin staining

A) Sham group: perineurium (arrow) and axon (arrowhead) with normal order and without swelling (100X); B) DW group: severe swelling of axons (arrowhead) and severe inflammatory reaction (arrow) (100X); C) Est group: axon swelling (arrowhead) and inflammatory cells (arrow) (400X); D) Tac group: swelling of axons (black arrowhead), inflammatory cells (white arrowhead), and perineurium (arrow) (400X); E) Est + Tac group: swelling of axons (black arrowhead) and inflammatory cells (white arrowhead) (400X)

mal nerve. In the Est+Tac group, the average number of axons was 50% in two rats and 75% of the normal nerve in three rats (Figures 4, 5, and 6).

4. Discussion

PNI occurs as a consequence of car accident, falls of height, injection of medicine, stretching of nerve plexus, iatrogenic causes, or inadvertent injury by a surgeon following ligation or electrocautery, among others [3]. Following these causes, the nerve suffers from loss of conduction of electrical impulse to organs and limbs [3]. Bipolar-electrocautery of the nerve during surgery is one of the common cause that leads to neurologic deficit, inadvertently [9]. Nerve damage caused by electrocautery is associated with the generation of heat in nerve structures and peripheral tissues, and its pathogenesis is distinct from neuronal lesions caused by crushing, which disrupt only myelin sheaths and axonal structure in various levels. Heat or thermal nerve injury is a type of tissue irritation caused by multiple factors, including iatrogenic (inadvertent) bipolar electrocautery [9]. Nerve damage occurs in two general categories: primary and secondary lesions. The nerve is damaged by direct thermal injury (primary lesion), electrochemical changes and damages, structural disruption of neurons and finally secondary injury cascade which happens after primary lesion [10]. The difference in the degrees of injury following electrocautery and crushing is related to these mechanisms. Protein degeneration, coagulation of axonal microtubules and neurofilaments, myelin sheath destruction and intracellular water loss, insufficiency of Na^+/k^+ neuronal pumps, Wallerian degeneration, scar formation as neuroma and glioma, thrombosis of arterioles and venules, and finally the release of prostaglandins and cytokines in the injury site and edema formation are the main pathologic changes of neurons following thermal injury by bipolar electrocautery [10]. Our study was designed to reveal the neuroprotective effect of conjugated estrogen (Est) and tacrolimus (Tac) on sciatic nerve injury induced experimentally by bipolar electrocautery in a rat model. The authors of the present study chose conjugated Est and Tac based on their known neuroprotective and immunemodulatory effects on tissues [11]. Despite the known effects of Est and Tac, there is a paucity of data about their combined therapeutic impact on nerve lesions, particularly following nerve injury by bipolar electrocautery. The authors hypothesized that the combination of Est and Tac could enhance functional improvement and histopathological recovery in a female rat model with

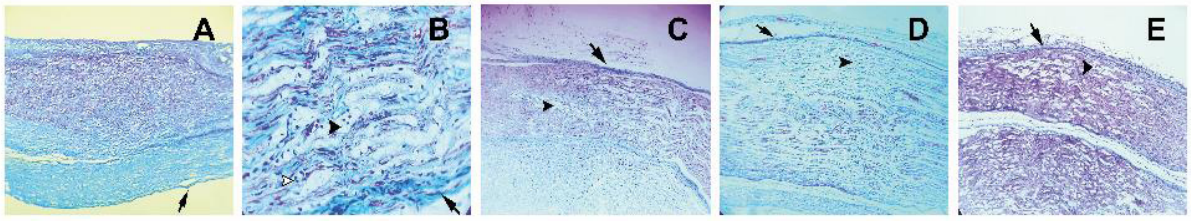

Figure 5. Longitudinal section of the sciatic nerve with Masson's trichrome stain

A) Sham group: normal epineurium (arrow) (100X); B) DW group: severe swelling of axons (black arrowhead), inflammatory cells (white arrowhead), and perineurium (arrow) (400X); C) Est group: significant swelling of axons (arrowhead) and normal perineurium (arrow) (100X); D) Tac group: significant swelling of axons (arrowhead) and normal perineurium (arrow) (100X). E) Est + Tac group: mild swelling of axons (arrowhead) and normal perineurium (arrow) (100X)

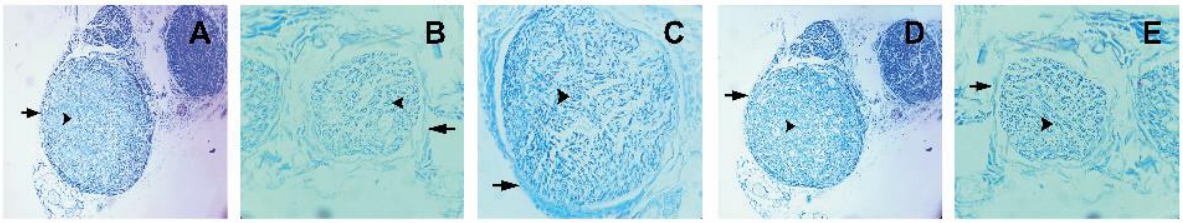

Figure 6. Cross section of the sciatic nerve with toluidine blue stain (100X)

A) Sham group: perineurium (arrow) and axons (arrowhead) with normal order; B) DW group: perineurium (arrow) and axons (arrowhead) fewer than normal; C) Est group: perineurium (arrow) and axons (arrowhead) fewer than normal; D) Tac group: perineurium (arrow) and axons (arrowhead) fewer than normal; E) Est + Tac group: perineurium (arrow) and axons (arrowhead) fewer than normal

sciatic nerve injury induced by bipolar electrocautery. To evaluate the functional recovery of the sciatic nerve, the SFI is one of the best-known tests for this purpose. Farahani's research revealed significant functional improvements following administration of a combination of Tac and Est on crushed sciatic nerve injury in mice [1], while we found no significant change in SFI score, indicating that the functional deficits observed in the injured nerve after bipolar electrocautery did not show significant repair during 4 weeks. Jazinidorche et al, in another study, showed that an anabolic agent, testosterone, had a positive effect on the SFI index following experimentally induced crushed sciatic nerve injury in rats [12]. Their study agrees with our findings regarding estrogen administration on the SFI index in rats. Bipolar electrocautery likely induces a different pattern of nerve damage. Although in this experimental study we did not examine the extent and severity of nerve damage caused by bipolar electrocautery from a histopathological point of view, the results of the study over a 4-week period indicate that nerve damage caused by electrocautery can be more severe and extensive than that reported in other studies on nerve damage following crushing. As stated earlier, thermal damage caused by electrocautery may result in a variety of more complex pathophysiological processes, severe thermal burn of surrounding tissues, and disruption of the blood-nerve supply, which can cause delayed repair [13].

According to the findings of the rota-rod performance test, our findings suggest that estrogen may have a positive role in enhancing motor coordination in rats. In comparison to estrogen, tacrolimus, as an immunosuppressive agent, does not have direct and significant role in nerve regeneration and repair [14]. The role of tacrolimus in peripheral nerve regeneration is via its immunemodulatory effects, while estrogen plays significant role in regulating motor nerve function in the short term.

The EMG latency and TOA tests provide valuable information for the DW group in electrophysiological studies. The EMG latency test revealed significant alterations in nerve conduction properties following injury. Results showed significant prolonged latency compared with the sham, Est, Tac, and Est + Tac groups. The correlation between Est and its role in motor function has been previously reported, showing that a decline in serum estrogen levels play a critical role in the development of peripheral neuropathy in post-menopausal women [15]. However, to the best of our knowledge, this study revealed a significant difference in EMG latency following administration of tacrolimus compared with other groups in our study. Although tacrolimus and estrogen reduced latency compared to the DW group, they were unable to improve nerve conduction as much as rats in the sham group. This finding suggests that these agents may have some neuroprotective effects, but they are insufficient to fully restore nerve function in the short term. We found a similar result in the TOA test. In contrast to the DW group, the TOA improved partially after treatment in the Tac, Est, and Est + Tac groups, but there was no statistically significant difference. This indicates that the combination of these drugs is not able to fully restore nerve function. The EMG and TOA findings demonstrated that nerve damage and its recovery, despite considerable advances in therapy, have not yet enabled complete recovery of damaged nerves following injury [16]. Histopathological study provided a new perspective on the effects of estrogen and tacrolimus, alone or in combination, on regeneration and repair of the tissue. Inflammatory cell infiltration, axonal swelling, and axon density were investigated at the end of our study. Perineurium regeneration was the same in all groups, with no statistical difference between the treatment and DW groups, which indicates that estrogen and tacrolimus had no effect on perineurium integrity. This finding confirmed the previous findings that have shown perineurial regeneration occurs in the early stage following

nerve injury and is less sensitive to treatments intended to be neuroprotective or regenerative [17]. Inflammatory cell infiltration was greatly different among groups. Inflammatory cells were not seen in the sham groups at the end of the study; however, the presence of inflammatory cells was intense and significant in the other groups. Tacrolimus, estrogen, and their combination reduced inflammation. This reduction is in agreement with previous studies showing that the anti-inflammatory activity of tacrolimus could decrease inflammation and provide a more suitable environment for nerve regeneration [18]. Interestingly, the Est group showed a moderate level of inflammation, significantly more than the sham group and less than the DW group. This finding implies that estrogen may have an anti-inflammatory effect, but it could not suppress inflammation in the early phases of nerve repair. Estrogen has been shown to have two effects: one is to reduce oxidative stress, and the other is to modulates cytokines. However, estrogen effectiveness in inhibiting inflammatory responses following nerve damage is not as strong as that of other anti-inflammatory agents such as NSAID or corticosteroids [19]. Tacrolimus has a more anti-inflammatory property by inhibiting the activation of immune cells involved in the inflammatory cascade [20].

The effectiveness of tacrolimus is associated with the inhibition of immune responses and its neurotropic role. In our study, axonal swelling was observed in all groups except the sham group, which had no swelling. The DW group showed moderate swelling, reflecting tissue damage and lack of recovery of untreated nerve damage. Both tacrolimus and estrogen administration in the Est, Tac, and Est + Tac groups reduced axonal swelling compared to the DW group but did not reduce swelling as much as the sham group. Our findings are consistent with Mansouri's study following 5 mg/kg tacrolimus administered orally in crushed sciatic nerve in male mice. They showed that this dose of tacrolimus could reduce axonal swelling to the level of the control group, which did not receive tacrolimus [2]. The studies from the past have shown that tacrolimus and estrogen both have neuroprotective characteristics due to their antioxidant and anti-inflammatory properties [14]. The presence of axonal swelling in the groups that received estrogen, tacrolimus, or their combination can be explained by either the dosage and amount of the drugs being inappropriate or the duration of drug use being too short to achieve acceptable results, since the anti-inflammatory and immunosuppressive properties of these two drugs have been confirmed in terms of nerve repair and regeneration.

We found interesting histopathological findings related to axonal density and count in this study. The sham group had axon counts similar to a normal nerve. In contrast, the DW group had a significant reduction in axon density, which indicated that distilled water is not capable of promoting nerve regeneration after injury by bipolar-electrocautery. In this study, it was found that estrogen and tacrolimus were able to increase the number and density of axons compared with the DW group based on histopathological evidence. However, the combination of these two medicines, like the Est and Tac groups, did not show acceptable results. These results were in accordance with previous research that has stated tacrolimus and estrogen have the ability to promote nerve regeneration and neuroprotection by enhancing axonal survival, respectively [20]. The difference in the amount of experimental nerve damage caused by crushing, ligation, and electrocautery, due to reversible or irreversible damage, has been noted in many studies [21, 22]. The heat caused by electrocautery certainly destroys the myelin covering of nerve axons and, on the other hand, causes destruction of the endoneurium of the sciatic nerve. If the injury with electrocautery does not involve the endoneurium, there is a possibility of 90% recovery within 4 to 12 weeks [9, 10].

5. Conclusion

According to the results of our study and the recovery of sciatic nerve function after four weeks of estrogen administration in rats in this group, it can be concluded that sciatic nerve irritation with bipolar electrocautery at intensity of 3 mA cannot damage the endoneurium layer. This is because, according to other studies, the lack of recovery of sciatic nerve function within four weeks indicates that nerve damage has reached the endoneurium layer by bipolar electrocautery.

Since there are few studies on the treatment of experimental sciatic nerve injuries following bipolar electrocautery compared to experimental nerve crush, further studies are needed to substantiate the results of this study and to explain the differences observed with nerve crush injuries.

Finally, we could state that tacrolimus and estrogen alone show some level of neuroprotection, particularly in the regulation of inflammation and axonal edema, but they were not sufficient to fully restore nerve function and structure following extensive sciatic nerve injury by bipolar electrocautery in this study. Estrogen and tacrolimus combined treatment did not show superiority over the agent used alone, and this combination was not effec-

tive in our experimental rat model. Taken together, we suggested further studies with longer duration, different dosages of these agents, and various routes of administration.

Acknowledgements

The authors would like to acknowledge all of our colleagues who had an impact on this research.

Compliance with ethical guidelines

The research project was formally approved by the Research Ethics Committee of the Science and Research Branch of the Islamic Azad University, Tehran, Iran (Code: IR.IAU.SRB.REC.1401.354).

Data availability

The data that support the findings of this study are available upon request from the corresponding author.

Funding

This research did not receive any grant from funding agencies in the public, commercial, or non-profit sectors.

Authors' contributions

Data collection: Nima Vazir; Writing: Nima Vazir and Hamidreza Fattahian; Supervision: Hamidreza Fattahian and Pejman Mortazavi; Experiments: Alireza Jahandideh.

Conflict of interest

The authors declared no conflict of interest.

References

[1] Khomejani Farahani F, Fattahian H, Asghari A, Mortazavi P. The comparative effects of estrogen and tacrolimus on crushed sciatic nerve regeneration in male mice: functional and histopathological evaluation. Vet Res Forum. 2022; 13(2):241-7. [DOI:10.30466/vrf.2020.135524.3041] [PMID]

[2] Mansouri K, Fattahian H, Jahandideh A, Akbarein H. The effects of tacrolimus and erythropoietin on histopathologic and functional recovery of sciatic nerve crush in mice. Maced Vet Rev. 2023; 46(2):147-63. [DOI:10.2478/macvetrev-2023-0020]

[3] Menorca RM, Fussell TS, Elfar JC. Nerve physiology: Mechanisms of injury and recovery. Hand Clin. 2013; 29(3):317-30. [DOI:10.1016/j.hcl.2013.04.002] [PMID]

[4] Divac N, Aksić M, Rasulić L, Jakovčevski M, Basailović M, Jakovčevski I. Pharmacology of repair after peripheral nerve injury. Int J Clin Pharm Th. 2021; 59(6):447-62. [DOI:10.5414/CP203893] [PMID]

[5] Khaled MM, Ibrahium AM, Abdelgalil AI, El-Saied MA, El-Bably SH. Regenerative strategies in treatment of peripheral nerve injuries in different animal models.Tissue Eng Regen Med. 2023; 20(6):839-77. [DOI:10.1007/s13770-023-00559-4] [PMID]

[6] Plosker GL, Foster RH. Tacrolimus: A further update of its pharmacology and therapeutic use in the management of organ transplantation. Drugs. 2000; 59(2):323-89. [DOI:10.2165/00003495-200059020-00021] [PMID]

[7] Yao X, Yan Z, Li X, Li Y, Ouyang Y, Fan C. Tacrolimus-induced neurotrophic differentiation of adipose-derived stem cells as novel therapeutic method for peripheral nerve injury. Front Cell Neurosci. 2021; 15:799151. [DOI:10.3389/fncel.2021.799151] [PMID]

[8] Bustamante-Barrientos FA, Méndez-Ruette M, Ortloff A, Luz-Crawford P, Rivera FJ, Figueroa CD, et al. The impact of estrogen and estrogen-like molecules in neurogenesis and neurodegeneration: beneficial or harmful? Front Cell Neurosci. 2021; 15:636176. [DOI:10.3389/fncel.2021.636176] [PMID]

[9] Dagtekin A, Comelekoglu U, Bagdatoglu O, Yilmaz N, Dagtekin O, Koseoglu A, et al. Comparison of the effects of different electrocautery applications to peripheral nerves: An experimental study. Acta Neurochir. 2011; 153(10):2031-9. [DOI:10.1007/s00701-011-1060-z] [PMID]

[10] Mofatteh MR, Meghdadi S, Sharifzadeh G, Hassanzadeh Taheri MM. A study of the complications of bipolar electrocautery tonsillectomy in patients admitted to Vali-e-Asr Hospital of Birjand. J Surg Trauma. 2015; 3(3):33-8. [Link]

[11] Gu D, Xia Y, Ding Z, Qian J, Gu X, Bai H, et al. Inflammation in the peripheral nervous system after injury. Biomedicines. 2024; 12(6):1256. [DOI:10.3390/biomedicines12061256] [PMID]

[12] Jazinidorcheh M, Fattahian H, Aliaghaei A, Abdollahifar MA. The study of testosterone and tacrolimus roles on gastrocnemius muscle following experimental sciatic nerve injury in rats. Acta Veterinaria Brno. 2024; 93(2):201-8. [DOI:10.2754/avb202493020201]

[13] van Eck CF, van Meel TAC, van den Bekerom MPJ, Zijl JAC, Kooistra B. Heat-related complications from radiofrequency and electrocautery devices used in arthroscopic surgery: A systematic review. Arthrosc Sports Med Rehabil. 2021; 3(2):e605-13. [DOI:10.1016/j.asmr.2020.12.002] [PMID]

[14] Shvetcov A, Ruitenberg MJ, Delerue F, Gold WA, Brown DA, Finney CA. The neuroprotective effects of estrogen and estrogenic compounds in spinal cord injury. Neurosci Biobehav Rev. 2023; 146:105074. [DOI:10.1016/j.neubiorev.2023.105074] [PMID]

[15] Singh A, Asif N, Singh PN, Hossain MM. Motor nerve conduction velocity in postmenopausal women with peripheral neuropathy. J Clin Diagn Res. 2016; 10(12):CC13-6. [DOI:10.7860/JCDR/2016/23433.9004] [PMID]

[16] Grinsell D, Keating CP. Peripheral nerve reconstruction after injury: A review of clinical and experimental therapies. Biomed Res Int. 2014; 2014:698256. [DOI:10.1155/2014/698256] [PMID]

[17] López-Cebral R, Silva-Correia J, Reis RL, Silva TH, Oliveira JM. Peripheral nerve injury: Current challenges, conventional treatment approaches, and new trends in biomaterials-based regenerative strategies. ACS Biomater Sci Eng. 2017; 3(12):3098-122. [DOI:10.1021/acsbiomaterials.7b00655] [PMID]

[18] Shahraki M, Mohammadi R, Najafpour A. Influence of tacrolimus (FK506) on nerve regeneration using allografts: A rat sciatic nerve model. J Oral Maxillofac Surg. 2015; 73(7):1438.e1-9. [DOI:10.1016/j.joms.2015.03.032] [PMID]

[19] Falvo E, Diviccaro S, Melcangi RC, Giatti S. Physiopathological role of neuroactive steroids in the peripheral nervous system. Int J Mol Sci. 2020; 21(23):9000. [DOI:10.3390/ijms21239000] [PMID]

[20] Saffari TM, Chan K, Saffari S, Zuo KJ, McGovern RM, Reid JM, et al. Combined local delivery of tacrolimus and stem cells in hydrogel for enhancing peripheral nerve regeneration. Biotechnol Bioeng. 2021; 118(7):2804-14. [DOI:10.1002/bit.27799] [PMID]

[21] Ghasemi Jalal J, Hassanpour S. Effects of Betaine on Ameliorating Depression in Gonadectomized Male Rats. Iran J Vet Med. 2025; 19(2):377-86. [DOI:10.32598/ijvm.19.2.1005466]

[22] Rezaei S, Asghari A, Hassanpour S, Arfaei F. Anti-nociceptive mechanisms of testosterone in unilateral sciatic nerve ligated male rat. Iran J Vet Med. 2022; 16(1):36-45. [DOI:10.32598/ijvm.19.2.1005466]