Archives of Razi Institute Journal
"Arch. Razi Inst."

Journal Homepage: https://archrazi.areeo.ac.ir/

Research Paper

Prevalence of Diffuse Idiopathic Skeletal Hyperostosis (DISH) Assessed With Whole-spine Radiography in Belgian Sheep Dog

Nader Azadi[1], Abbas Veshkini[1*], Ahmad Asghari[1], Alireza Bahonar[2], Gholamreza Abedi[3]

1. Department of Clinical Science, SR.C., Islamic Azad University, Tehran, Iran.
2. Department of Food Hygiene & Quality Control, Faculty of Veterinary Medicine, University of Tehran, Tehran, Iran.
3. Department of Veterinary Surgery, SR.C., Islamic Azad University, Tehran, Iran.

Use your device to scan and read the article online

How to cite this article Azadi N, Veshkini A, Asghari A, Bahonar A, Abedi GH. Prevalence of Diffuse Idiopathic Skeletal Hyperostosis (DISH) Assessed With Whole-spine Radiography in Belgian Sheep Dog. Archives of Razi Institute Journal. 2026; 81(4):849-856. https://doi.org/10.32598/ARI.81.4.3292

https://doi.org/10.32598/ARI.81.4.3292

Article info:
Received: 22 Jan 2026
Accepted: 15 Mar 2026
Published: 01 Jul 2026

Keywords:
DISH, Prevalance, Radiograph, Vertebral Column, Belgian Sheep Dog

ABSTRACT

Introduction: Diffuse idiopathic skeletal hyperostosis (DISH) is a condition affecting the musculoskeletal system, characterized by the gradual ossification of ligaments. It leads to reduced mobility and pain in affected subjects. This study aimed to understand the demographic characteristics and clinical symptoms of Belgian Sheep breed dogs with DISH and establish potential relationships between them.

Materials & Methods: The study was conducted from the summer of 2021 to the summer of 2023, lateral radiographs of the entire vertebral column were obtained for all Belgian Sheep breed dogs kept at the FARAJA (Law Enforcement Command of the Islamic Republic of Iran) narcotic dog center in Iran. Dogs that were diagnosed with DISH were selected as the statistical population. Demographic characteristics, activity types, clinical symptoms, and the location of the disease on spines were documented for each selected dog.

Results: The investigation showed that 9.91% (45) of the dogs exhibited signs of DISH. Male dogs (55.6%) experienced a higher prevalence compared to female dogs (44.4%). Dogs weighing 15-20 kg (40%) showed a higher prevalence, although this was not statistically significant. Furthermore, dogs aged over five years (53.3%) were significantly more affected compared to those in the 2-5 years old range (37.8%), and less than dogs in the two years old and younger range (8.9%) with DISH. 71.1% of dogs showed no clinical symptoms, 20% demonstrated lameness and 8.9% demonstrated a reluctance to move. This difference was statistically significant. Drug detection dogs (65.6%) were notably more affected by this disease compared to guard dogs (24.4%). The frequency of DISH in cervical, cervical-

*** Corresponding Author:**
Abbas Veshkini, Associate Professor.
Address: *Department of Clinical Science, SR.C., Islamic Azad University, Tehran, Iran.*
E-mail: *veshkini.vet@gmail.com*

Copyright © 2026 The Author(s);
This work is licensed under a Creative Commons Attribution-NonCommercial 4.0 International license (https://creativecommons.org/licenses/by-nc/4.0/).
Noncommercial uses of the work are permitted, provided the original work is properly cited.

thoracic, thoracic, thoracic-lumbar, lumbar-sacral, and sacral vertebrae was 8.5%, 26.7%, 33.3%, 40.3%, 31.1%, 17.8%, and 4.4%, respectively.

Conclusion: The research findings suggest that while the incidence of DISH in Belgian Sheepdogs is relatively low, periodic radiographs are crucial, especially as dogs age and in detection dogs, where most sufferers may not exhibit clinical symptoms. This preventive measure can help mitigate the risk of disease contraction. Additionally, the study highlighted that thoracic and lumbar vertebrae are more susceptible to damage in this disease, emphasizing the need for special attention to these areas.

1. Introduction

Diffuse idiopathic skeletal hyperostosis (DISH) is a condition characterized by the calcification and ossification of soft tissues, primarily affecting the ligaments connecting the bones of the spine [1-3].

This disease was first introduced in the 1950s by Forestier and Rotes-Querol. According to the studies they conducted on animals, DISH has been observed to predominantly manifest in the thoracic spine, with a tendency to occur in the right side of the body [4]. In 1968, Sokoloff et al. described a condition akin to DISH in animals, including dinosaurs, saber-toothed cats, and old rhesus macaques, which included bone growths on their spines [5]. About 20 years later, Woodard et al. (1985) identified DISH in a four-year-old Labrador dog during an autopsy [6]. Despite these discoveries, there is no universally accepted consensus on the etiology of DISH.

Various studies have suggested certain factors, including genetic factors (*HLA* genes), metabolic changes, endocrine factors, and the use of certain drugs (isotretinoin, etretinate, acitretin, and other vitamin A derivatives) [7-10] as the causes of this disease. Experimental studies have indicated that biomechanical processes lead to spinal fixation and hypomobility. These factors contribute to time-dependent degenerative changes [11]. Furthermore, human studies have revealed that increased stress and tension in areas near the spinal column may play a role in the development of this complication [12].

While various tools are employed to diagnose this disease, according to Westerveld et al. (2008), radiography stands out as the most reliable method. Radiographic evidence of DISH includes calcification and ossification along the ventrolateral aspect of at least two contiguous vertebral bodies, with the preservation of disc space between the affected surfaces [13]. As observed through radiographic findings, DISH can affect different vertebral levels, extending from the cervical to the caudal regions of the spine. It can create similar ossification in various anatomical locations, such as the shoulder, iliac crest, ischial tuberosity, thigh trochanters, tibial tuberosities, patella, and the bones of the anterior and posterior limbs [14, 15].

In summary, DISH can have detrimental effects on dogs, particularly those used as police dogs. In severe cases, DISH can ground these dogs, thus preventing them from being used effectively during police missions. Evidence has demonstrated that the severity of this condition's impact on police dogs is so significant, that it leads to potential incapacitation even at a young age, rendering the dogs unable to even stand on their legs. Consequently, prevention and treatment of DISH in such dogs are crucial. Recognizing the nature of this condition, especially through careful radiological examination, is essential. In this study, by examining radiographs from different ages and both sexes and analyzing the associated risk factors, we tried to take a significant step toward understanding the etiology of DISH.

2. Material and Methods

2.1. Statement of ethics

This study adheres to the guidelines of the Ethics and Welfare Committee of the Center for the Training of Narcotics Detection Dogs of the Greater Tehran Police Force. As all radiographic studies were conducted for clinical diagnostic purposes, no additional approval from the ethics and welfare committee was required.

2.2. Animals

This study was conducted between the summer of 2021 and the summer of 2023, this study involved the entire adult population of Belgian Sheepdogs housed in the Narcotics Dog Training Center of the Greater Tehran Police Force, totaling 454 dogs.

2.3. Radiography

To evaluate DISH, standard lateral radiographs were procured from all vertebral columns, including the cervical, thoracic, lumbar, and sacrum regions, utilizing an analog radiography machine. Adhering to the criteria outlined by Arlet and Mazieres (1985) [16], which involve:

The presence of calcification and ossification along the joint of three or more vertebrae continuously.

Relative preservation of disc height.

The absence of apophyseal joint ankylosis, bone sclerosis, or bone fusion.

Subjects meeting these criteria were included in the study.

2.4. Data analysis

The initial analysis encompassed determining the frequency and percentage of the disease across different cases. Subsequently, data distribution was evaluated using the Shapiro-Wilk test. Statistical differences between groups were examined using one-sample t-test and ANOVA. A level of 0<0.05 was deemed statistically significant.

3. Results

3.1. Data distribution

The Shapiro-Wilk test results indicated that the significance level for all factors exceeded 0.05, affirming the normal distribution of the data.

3.2. Demographics

Based on radiographic findings, among 445 dogs, 45 dogs had the disease. As depicted in Table 1, male dogs showed a higher prevalence of DISH (55.6%) compared to their female counterparts (44.4%). However, this gender difference is not statistically significant (P=0.45). Notably, the majority of DISH cases are observed in dogs over five years old (53.3%), followed by those aged two to five years (37.8%), and the least in dogs younger than two years old (8.9%). This frequency difference is statistically significant (P=0.001). Regarding weight categories, dogs weighing 15 to 20 kg (40%) displayed a slightly higher frequency of DISH compared to those above 20 kg (37.8%) and below 15 kg (22.2%). Nevertheless, this weight-based difference is not statistically significant (P=0.282).

Table 1. Demographics of Belgian Sheep dog with DISH

Factor	Group	No. (%)	Sig.
Gender	Female	20(44.4)	0.45
	Male	25(55.6)	
Age (y)	2>	4(8.9)	0.001
	2-5	17(37.8)	
	5≤	24(53.3)	
Weight (kg)	1 >	10(22.2)	0.282
	15-20	18(40)	
	20≤	17(37.8)	
Clinical sign	Normal	32(71.1)	0.000
	Lameness	9(20)	
	Reluctant to movement	4(8.9)	
Activity	Drug	34(65.6)	0.001
	Guard	11(24.4)	

Dogs without clinical symptoms (71.1%) were significantly more susceptible to DISH than their counterparts who showed clinical symptoms like lameness and reluctance to move. However, no statistically significant difference was observed within the group exhibiting lameness and reluctance to move (P=0.04).

Notably, police drug dogs exhibited a significantly higher prevalence of DISH compared to guard dogs (P=0.001).

Among the 454 dogs examined, 442 showed no clinical symptoms related to the skeletal system. Surprisingly, 23.7% (32 dogs) of these studied cases had DISH in at least one area.

3.3. Radiograph of the vertebral column

Graph 1 illustrates the highest incidence in the thoracic-lumbar vertebrae, accounting for 40.3% of total cases. Following this, thoracic and lumbar vertebrae show proportions of 33.3% and 31.1%, respectively. Cervicothoracic vertebrae (26.7%) rank fourth, followed by lumbosacral vertebrae (17.8%). Cervical vertebrae and sacrum exhibit the least involvement, with 8.9% and 4.4%, respectively. The study's findings indicate that the development of DISH in lumbo-sacral and cervicothoracic vertebrae, with a calculated P-value less than or equal to 0.001, and in lumbar and thoracic vertebrae, with a calculated P-value less than or equal to 0.05, is statistically significant (Figures 1 and 2).

4. Discussion

While DISH was first described over six decades ago, veterinarians and physicians still possess limited knowledge. This knowledge gap could lead to misdiagnosis and unnecessary investigations. This emphasizes the crucial need for an accurate understanding of this disease, particularly in distinct breeds, thus facilitating prevention and proper treatment.

The prevalence of DISH differs across studies, this could be attributed to differing definitions and perceptions of this disease [15]. Advancements in imaging equipment have enhanced the precision of DISH diagnosis [17]. This study revealed a DISH prevalence of 9.91% in narcotic police Belgian Sheep breed dogs. Kranenburg et al. (2011) have also reported a 3.8% prevalence in a population of 2014 dogs, with a specific spondylosis prevalence of 18% and a DISH prevalence of 40.6% in the Boxer breed [18].

DISH often manifests without clinical symptoms, making it an incidental diagnosis during radiological examinations [17-20]. In the current study, 7.23% of dogs with no clinical symptoms were afflicted with DISH, and 71.1% of the DISH-afflicted dogs exhibited no clinical symptoms. Kranenburg et al. (2011) also noted a 3.8% prevalence of this disease in clinically healthy dogs [18]. However, various clinical symptoms have been re-

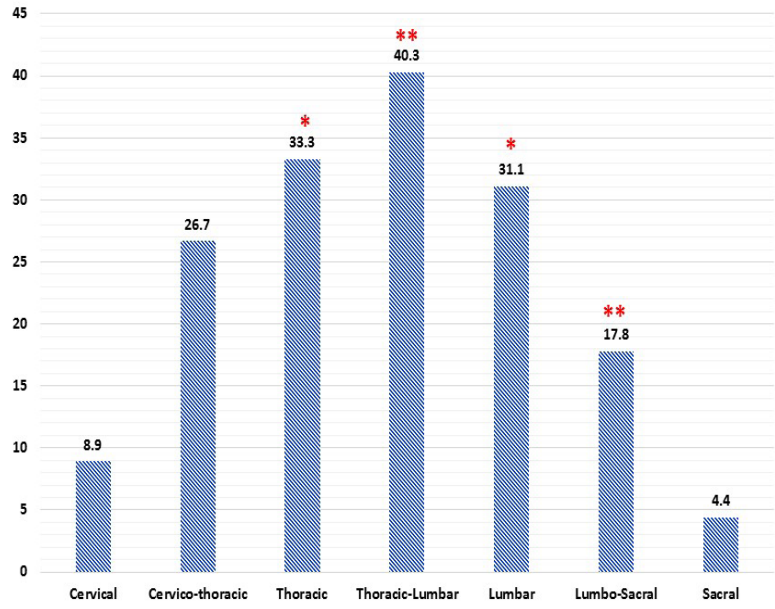

Figure 1. Frequency of DISH in Belgian Sheep dog

*P≤0.05, **P≤0.001.

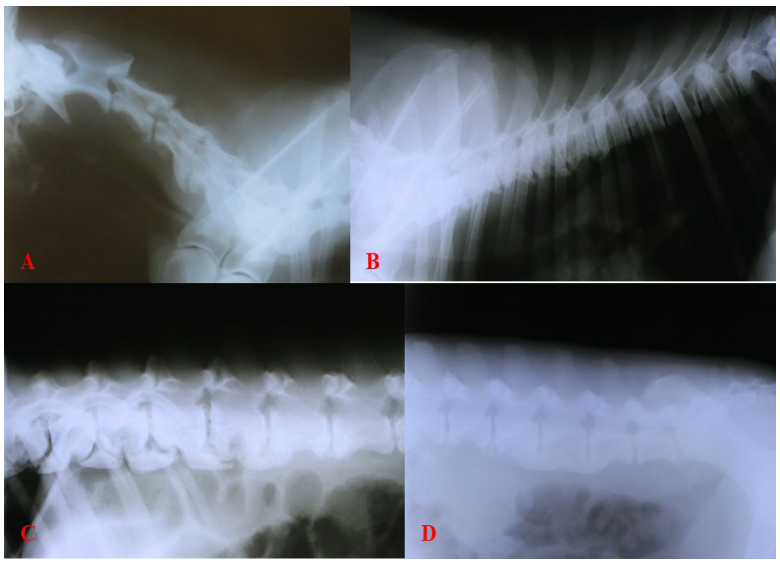

Figure 2. Lateral radiograph views of Belgian Sheep dogs with DISH

A) Cervical vertebrae, B) Thoracic vertebrae, C) Thoracic-lumbar vertebrae, D) Lumbar vertebrae

ported in DISH-afflicted subjects; back pain and spinal stiffness stand out as prevalent DISH indicators [3]. In a study involving 200 DISH patients, Utsinger (1985) reported that 72% experienced back pain, while 84% reported spinal stiffness. In the current study, lameness was observed in 20% of subjects, while 8.9% displayed reluctance to move [21]. In the study of De Decker et al. (2014) in 10 dogs showed some of clinial sign including paraparesis (n=5 dogs), lumbosacral pain (n=4), urinary incontinence (n=4), faecal incontinence (n=1) and urinary and faecal incontinence (n=1) [22].

In our study, the correlation between age and DISH risk became evident. This aligns with the conclusions drawn by Kranenburg et al. (2011), who found that older dogs face a higher likelihood of DISH affliction [18]. This fact is also observed in human medical studies, where age is consistently associated with an increased risk of DISH [23-26].

Although our findings indicate a higher prevalence of DISH in male dogs, the difference is not statistically significant. This observation is consistent with previous veterinary and medical studies, where males were identified as more susceptible to DISH [18, 27-30].

The thoracic-lumbar vertebrae emerged as the most area affected by DISH in our study, followed by the thoracic and lumbar vertebrae. This is similar with certain human studies that reported a similar prevalence in the thoracic region [17, 27, 31]. The susceptibility of these vertebrae to mechanical stress likely contributes to the higher incidence of DISH. The mechanical stress could potentially expand to cervical or lumbar areas. Moreover, blood flow and blood pressure may influence the progression of DISH ossification [17].

However, Ghazanfar et al. (2014) have reported contrary findings during their observations, suggesting a higher prevalence of DISH in the lumbo-sacral area of Fighting Bulldogs [32]. Furthermore, Togni et al. (2014) revealed that among the 108 lumbar vertebrae scrutinized, 100 exhibited complications associated with DISH [33].

This study exclusively focused on dogs utilized by the Iranian police under specific conditions. Consequently, caution is advised against generalizing the findings to broader populations.

5. Conclusion

DISH represents a systemic disorder marked by ectopic mature bone formation. Its prevalence escalates with age. Radiography emerges as a dependable diagnostic tool capable of detecting this condition, surpassing reliance solely on clinical symptoms. By utilizing this tool, not only can the disease be identified beyond observable symptoms, but preventive measures can also be implemented, safeguarding dogs against its onset. This approach ensures the sustained health and efficiency of these animals, particularly police dogs.

Acknowledgements

We extend our gratitude to the Narcotic Dog Breeding Center of the Greater Tehran Police Force, with a special acknowledgment to the Diagnostic Imaging Department.

Compliance with ethical guidelines

All ethical considerations were observed in this study.

Funding

This research did not receive any grant from funding agencies in the public, commercial, or non-profit sectors.

Authors' contributions

All authors contributed equally to the content of the paper.

Conflict of interest

The authors declared no conflict of interest.

Date availability

The data that support the findings of this study are available on request from the corresponding author.

References

[1] Resnick D, Shaul SR, Robins JM. Diffuse idiopathic skeletal hyperostosis (DISH): Forestier's disease with extraspinal manifestations. Radiology. 1975; 115(3):513-24. [DOI:10.1148/15.3.513] [PMID]

[2] Mader R. Diffuse idiopathic skeletal hyperostosis: A distinct clinical entity. Isr Med Assoc J. 2003; 5(7):506-8. [PMID]

[3] Mader R, Verlaan JJ, Buskila D. Diffuse idiopathic skeletal hyperostosis: Clinical features and pathogenic mechanisms. Nat Rev Rheumatol. 2013; 9(12):741-50. [DOI:10.1038/nrrheum.2013.165] [PMID]

[4] Forestier J, Rotès-Querol J. Senile ankylosing hyperostosis of the spine. Ann Rheum Dis. 1950; 9(4):321-30. [DOI:10.1136/ard.9.4.321] [PMID]

[5] Sokoloff L, Snell KC, Stewart HL. Spinal ankylosis in old Rhesus monkeys. Clin Orthop Relat Res. 1968; 61:285-93. [PMID]

[6] Woodard JC, Poulos PW Jr, Parker RB, Jackson RI Jr, Eurell JC. Canine diffuse idiopathic skeletal hyperostosis. Vet Pathol. 1985; 22(4):317-26. [DOI:10.1177/030098588502200404] [PMID]

[7] Kranenburg HC, Hazewinkel HA, Meij BP. Spinal hyperostosis in humans and companion animals. Vet Q. 2013; 33(1):30-42. [DOI:10.1080/01652176.2013.770181] [PMID]

[8] DiGiovanna JJ, Helfgott RK, Gerber LH, Peck GL. Extraspinal tendon and ligament calcification associated with long-term therapy with etretinate. N Engl J Med. 1986; 315(19):1177-82. [DOI:10.1056/NEJM198611063151901] [PMID]

[9] DiGiovanna JJ. Isotretinoin effects on bone. J Am Acad Dermatol. 2001; 45(5):S176-82. [DOI:10.1067/mjd.2001.113721] [PMID]

[10] Troillet N, Gerster JC. [Forestier disease and metabolism disorders. A prospective controlled study of 25 cases (French)]. Rev Rhum Ed Fr. 1993; 60(4):274-9. [PMID]

[11] Cramer GD, Fournier JT, Henderson CN, Wolcott CC. Degenerative changes following spinal fixation in a small animal model. J Manipulative Physiol Ther. 2004 ; 27(3):141-54. [DOI:10.1016/j.jmpt.2003.12.025] [PMID]

[12] Little JS, Ianuzzi A, Chiu JB, Baitner A, Khalsa PS. Human lumbar facet joint capsule strains: II. Alteration of strains subsequent to anterior interbody fixation. Spine J. 2004; 4(2):153-62. [DOI:10.1016/j.spinee.2003.07.002] [PMID]

[13] Westerveld LA, van Ufford HM, Verlaan JJ, Oner FC. The prevalence of diffuse idiopathic skeletal hyperostosis in an outpatient population in The Netherlands. J Rheumatol. 2008; 35(8):1635-8. [PMID]

[14] Bundrick TJ, Cook DE, Resnik CS. Heterotopic bone formation in patients with DISH following total hip replacement. Radiology. 1985; 155(3):595-7. [DOI:10.1148/radiology.155.3.3923552] [PMID]

[15] Vaishya R, Vijay V, Nwagbara IC, Agarwal AK. Diffuse idiopathic skeletal hyperostosis (DISH) - A common but less known cause of back pain. J Clin Orthop Trauma. 2017; 8(2):191-6. [DOI:10.1016/j.jcot.2016.11.006] [PMID]

[16] Arlet J, Mazieres B. [Hyperostotic disease (French)]. Rev Med Interne. 1985; 6(5):553-64. [DOI:10.1016/S0248-8663(85)80037-0] [PMID]

[17] Hiyama A, Katoh H, Sakai D, Sato M, Tanaka M, Watanabe M. Prevalence of diffuse idiopathic skeletal hyperostosis (DISH) assessed with whole-spine computed tomography in 1479 subjects. BMC Musculoskelet Disord. 2018; 19(1):178. [DOI:10.1186/s12891-018-2108-5] [PMID]

[18] Kranenburg HC, Voorhout G, Grinwis GCM, Hazewinkel HAW, Meij BP. Diffuse idiopathic skeletal hyperostosis (DISH) and spondylosis deformans in purebred dogs: A retrospective radiographic study. Vet J. 2011; 190(2):e84-e90. [DOI:10.1016/j.tvjl.2011.04.008] [PMID]

[19] Mader R, Verlaan JJ, Eshed I, Bruges-Armas J, Puttini PS, Atzeni F, et al. Diffuse idiopathic skeletal hyperostosis (DISH): Where we are now and where to go next. RMD Open. 2017; 3(1):e000472. [DOI:10.1136/rmdopen-2017-000472] [PMID]

[20] Nascimento FA, Gatto LA, Lages RO, Neto HM, Demartini Z, Koppe GL. Diffuse idiopathic skeletal hyperostosis: A review. Surg Neurol Int. 2014; 5(Suppl 3):S122-5. [DOI:10.4103/2152-7806.130675] [PMID]

[21] Utsinger PD. Diffuse idiopathic skeletal hyperostosis. Clin Rheum Dis. 1985; 11(2):325-51. [DOI:10.1016/S0307-742X(21)00544-0] [PMID]

[22] Decker SD, Volk HA. Dorsal vertebral column abnormalities in dogs with disseminated idiopathic skeletal hyperostosis (DISH). Vet Rec. 2014; 174(25):632. [DOI:10.1136/vr.102492] [PMID]

[23] Toyoda H, Terai H, Yamada K, Suzuki A, Dohzono S, Matsumoto T, et al. Prevalence of diffuse idiopathic skeletal hyperostosis in patients with spinal disorders. Asian Spine J. 2017; 11(1):63-70. [DOI:10.4184/asj.2017.11.1.63] [PMID]

[24] Pariente-Rodrigo E, Sgaramella GA, Olmos-Martínez JM, Pini-Valdivieso SF, Landeras-Alvaro R, Hernández-Hernández JL. Relationship between diffuse idiopathic skeletal hyperostosis, abdominal aortic calcification and associated metabolic disorders: Data from the Camargo Cohort. Med Clin (Barc). 2017; 149(5):196-202. [DOI:10.1016/j.medcli.2017.01.030] [PMID]

[25] Holton KF, Denard PJ, Yoo JU, Kado DM, Barrett-Connor E, Marshall LM; Osteoporotic Fractures in Men (MrOS) Study Group. Diffuse idiopathic skeletal hyperostosis and its relation to back pain among older men: The MrOS Study. Semin Arthritis Rheum. 2011; 41(2):131-8. [DOI:10.1016/j.semarthrit.2011.01.001] [PMID]

[26] Katzman WB, Huang MH, Kritz-Silverstein D, Barrett-Connor E, Kado DM. Diffuse idiopathic skeletal hyperostosis (DISH) and impaired physical function: The rancho bernardo study. J Am Geriatr Soc. 2017; 65(7):1476-81. [DOI:10.1111/jgs.14810] [PMID]

[27] Hirasawa A, Wakao N, Kamiya M, Takeuchi M, Kawanami K, Murotani K, et al. The prevalence of diffuse idiopathic skeletal hyperostosis in Japan - the first report of measurement by CT and review of the literature. J Orthop Sci. 2016; 21(3):287-90. [DOI:10.1016/j.jos.2016.02.001] [PMID]

[28] Kagotani R, Yoshida M, Muraki S, Oka H, Hashizume H, Yamada H, et al. Prevalence of diffuse idiopathic skeletal hyperostosis (DISH) of the whole spine and its association with lumbar spondylosis and knee osteoarthritis: The ROAD study. J Bone Miner Metab. 2015; 33(2):221-9. [DOI:10.1007/s00774-014-0583-9] [PMID]

[29] Bateman M, Hapuarachchi K, Pinto C, Doyle AJ. Diffuse idiopathic skeletal hyperostosis (DISH): Increased prevalence in Pacific Islanders. J Med Imaging Radiat Oncol. 2018; 62(2):188-93. [DOI:10.1111/1754-9485.12679] [PMID]

[30] Zincarelli C, Iervolino S, Di Minno MN, Miniero E, Rengo C, Di Gioia L, et al. Diffuse idiopathic skeletal hyperostosis prevalence in subjects with severe atherosclerotic cardiovascular diseases. Arthritis Care Res (Hoboken). 2012; 64(11):1765-9. [DOI:10.1002/acr.21742] [PMID]

[31] Mori K, Kasahara T, Mimura T, Nishizawa K, Nakamura A, Imai S. Prevalence of thoracic diffuse idiopathic skeletal hyperostosis (DISH) in Japanese: Results of chest CT-based cross-sectional study. J Orthop Sci. 2017; 22(1):38-42. [DOI:10.1016/j.jos.2016.09.003] [PMID]

[32] Ghazanfar A, Asi MN, Mughal MN, Saqib M, Muhammad G. Diffused idiopathic skeletal hyperostosis in a fighting Bulldog: a case report. Iran J Vet Res. 2015; 16(2):223-5. [PMID]

[33] Togni A, Kranenburg HJ, Morgan JP, Steffen F. Radiographic and MRI characteristics of lumbar disseminated idiopathic spinal hyperostosis and spondylosis deformans in dogs. J Small Anim Pract. 2014; 55(7):343-9. [DOI:10.1111/jsap.12218] [PMID]

This Page Intentionally Left Blank