Archives of Razi Institute Journal
"Arch. Razi Inst."

Journal Homepage: https://archrazi.areeo.ac.ir/

Case Report

A Case Report of Infestation With *Sarcoptes scabiei* (Family: Sarcoptidae) in a Stray Dog, Shahriar City, Tehran Province, Iran

Alireza Ghorbani[1], Yagoob Garedaghi[2*], Erfan Darmanloo[3]

1. Department of Pathobiology, Faculty of Veterinary Medicine, Urmia University, Urmia, Iran.
2. Department of Parasitology, TaMS.C., Islamic Azad University, Tabriz, Iran.
3. Department of Clinical Sciences, Faculty of Veterinary Science, Bu-Ali Sina University, Hamadan, Iran.

Use your device to scan and read the article online

How to cite this article Ghorbani A, Garedaghi Y, Garedaghi E. A Case Report of Infestation With *Sarcoptes scabiei* (Family: Sarcoptidae) in a Stray Dog, Shahriar City, Tehran Province, Iran. Archives of Razi Institute Journal. 2026; 81(1):265-270. https://doi.org/10.32598/ARI.81.1.3062

https://doi.org/10.32598/ARI.81.1.3062

Article info:
Received: 05 Oct 2025
Accepted: 10 Dec 2025
Published: 01 Jan 2026

Keywords:
Case report, Iran, *Sarcoptes scabiei*, Shahriar City, Stray dog

ABSTRACT

Sarcoptes scabiei is one of the most impactful external parasites in mammals, especially in dogs, and its global spread is widespread. Considering that this parasite is capable of being transmitted to humans, it holds significant public health value for examination. Today, with the increase in the number of stray dogs in urban areas, particularly on the outskirts of cities, controlling this parasitic disease in dogs is highly emphasized. In January 2024, a three-year-old female dog in Shahriar City, Tehran Province, was observed with skin disorders and hair loss in areas such as the abdominal region, flanks, limbs, and parts of the neck. Following initial examinations of the animal's skin lesions, skin-scraping samples were taken. Microscopic examination of skin-scraping samples from the surface of the animal's body in the parasitology laboratory revealed that this stray dog was infested with the microscopic external parasite *S. scabiei*. Such research helps identify predominant species of external parasites and implement more precise health controls in these areas. Shahriar, being one of the cities near Tehran with a high population density, can be significantly affected by parasitic diseases. Therefore, due to the large population of humans and dogs in Shahriar City, it is very important to recognize and control zoonotic diseases in this area.

*** Corresponding Author:**
Yagoob Garedaghi, Associate Professor.
Address: *Department of Parasitology, TaMS.C., Islamic Azad University, Tabriz, Iran.*
Tel: *+98 (41) 36377703*
E-mail: *yagoob.garedaghi@gmail.com*

Copyright © 2026 The Author(s);
This work is licensed under a Creative Commons Attribution-NonCommercial 4.0 International license(https://creativecommons.org/licenses/by-nc/4.0/).
Noncommercial uses of the work are permitted, provided the original work is properly cited.

1. Introduction

1.1. Overview

Mites are microscopic external parasites that can cause skin disorders in mammals [1]. Mites, as notorious and contagious external parasite found worldwide, include several species, such as *Demodex*, *Otodectes*, *Psoroptes*, and *Sarcoptes*, which can infest a wide range of animals including cats, dogs, rabbits, and humans [2]. Dogs are among the animals susceptible to scabies infection. One of the most significant scabies infestations in dogs is caused by *Sarcoptes scabiei*, which, due to its highly non-host-specific nature, can easily spread through skin contact [3]. *S. scabiei* penetrates the host's skin by creating tunnels under the epidermis, leading to itching, burning, redness, and inflammation of the skin surface, as well as secondary skin diseases [4].

1.2. Classification and morphology

S. scabiei belongs to the Phylum Arthropoda, Class Arachnida, Order Sarcoptiformes, Family Sarcoptidae, genus *Sarcoptes*, and species *S. scabiei* (Table 1) [5].

Adult *S. scabiei* has an oval-shaped body with a smooth ventral side and a convex dorsal side. Larvae of *S. scabiei* have six legs, while nymphs and adults have eight legs. Suckers are present on the first and second pairs of legs in both males and females, but suckers on the fourth pair of legs are present only in males. These suckers help them grip the substrate during movement. The size of female *S. scabiei* ranges from 315 to 470 micrometers in length and 225 to 345 micrometers in width, while male *S. scabiei* measure between 205 and 245 micrometers in length and 145 to 170 micrometers in width [6]. Since the life cycle of *S. scabiei* occurs entirely on the host's skin, mating of adult males and females initiates the life cycle on the skin surface. After mating, the male dies, and the female begins to create tunnels in the epidermal layer of the skin [7]. The female burrows at a rate of 2-3 millimeters per day. Egg-laying occurs at a rate of 1-3 eggs per day within these burrows for about two months. Each female has its own burrow where only its eggs and feces are located. The eggs hatch into six-legged larvae within 2-3 days. Then the larvae migrate to the skin surface and molt into eight-legged protonymphs within 3-4 days, then into tritonymphs within 2-3 days, and finally molt into adult males or females. Overall, the process from egg to adulthood takes about 14 days [8, 9].

2. Case Presentation

2.1. Study area

Because the geographic location of the study area is important to parasite prevalence, we briefly describe the location of Shahriar City.

Shahriar district, with coordinates 35° 36′ 0″ N, 51° 5′ 0″ E, is a densely populated area with approximately 744,210 people in western of Tehran Province. The area of Shahriar is 340 square kilometers and is bordered by Qods City to the north, Baharestan and Robat Karim to the south, Tehran and Eslamshahr to the east, and Mallard to the west. This area is 1,140 meters above sea level and has an average temperature of 10 ˚C; making it one of the areas with a favorable climate in Tehran Province (Figure 1). Due to its proximity to the capital of Iran, Shahriar is one of the most important regions.

2.2. Data collection and diagnosis of *S. scabiei*

After observing a stray dog of the Khorasani breed displaying symptoms such as itching and hair loss, the possibility of scabies infestation was considered. Subsequently, the animal's age was estimated based on dental formula. For sampling, skin scrapings were performed on five areas of the dog with more severe pruritus using a scalpel blade soaked in oil, and the obtained samples were sent to the parasitology laboratory (Figure 2). The skin scrapings were then placed in 10% potassium hydroxide solution and heated over a Bunsen burner for about 30 minutes using a water-bath. After dissolution, the samples were centrifuged for two minutes, and the resulting sediment was examined under a microscope to confirm the presence of *S. scabiei* [10].

After the initial observation and examination of a 3-year-old female dog with symptoms such as itching, hair loss, and redness of the skin surface, a skin scratch sample was taken from the animal in accordance with hygiene protocols and transferred to the parasitology laboratory. After examination, the parasite was observed under a microscope from different angles, and *S. scabiei* was identified and confirmed using diagnostic keys (Figure 3).

3. Discussion

Parasitic diseases are among the most important infectious diseases worldwide and can affect millions of people and animals annually [11]. Ectoparasites are a common parasitic diseases with a global distribution,

Table 1. Taxonomy of *S. scabiei* parasites

Taxonomic Unit	Parasitic Group Name
Kingdom	Animalia
Phylum	Arthropoda
Class	Arachnida
Order	Sarcoptiformes
Family	Sarcoptidae
Genus	*Sarcoptes*
Species	*Sarcoptes scabiei*

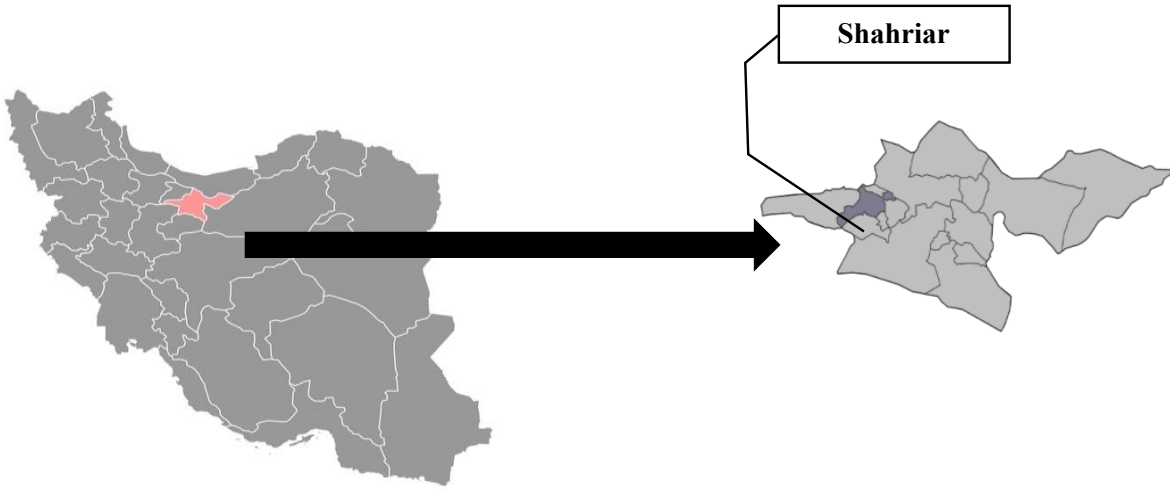

Figure 1. Map of Iran showing the location of Tehran Province and the Shahriar region

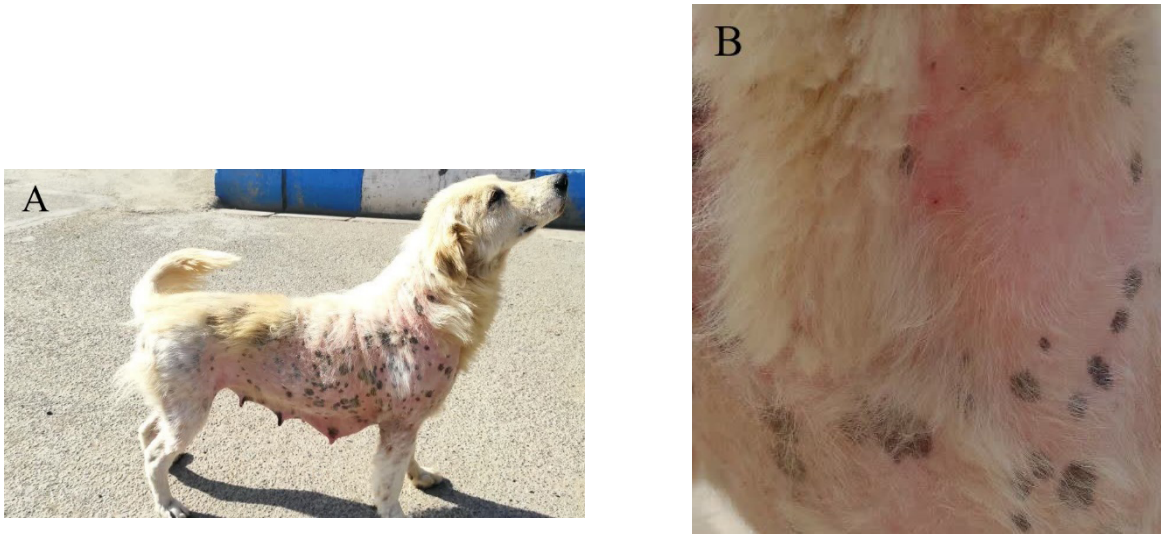

Figure 2. The body surface of an infected stray female dog observed in the city of Shahriar

Figure 3. *S. scabiei* isolated from the body surface of an infected female dog

capable of infecting various animals and even humans. Dogs are the animals that have the most contact with humans, and this closeness can facilitate the transmission of zoonotic diseases between humans and dogs. *S. scabiei* is an ectoparasite that mainly affects domestic and young dogs and is considered to have global distribution [12]. Given that *S. scabiei* is a zoonotic parasite, contact between humans and infected animals can lead to skin lesions in up to 50% of exposed individuals. However, this parasite complete its life cycle in human skin and eventually dies, which is why infected humans typically recover after the source animal is treated [13, 14]. It can be said that *S. scabiei* is one of the dominant species causing sarcoptic mange in Iran. According to a study by Minabaji et al. (2020) [15], samples were collected from 460 dogs in Mashhad between 2017 and 2018, and *S. scabiei* was identified in 2.17% of cases. From 2012 to 2013, Mirani et al. (2017) [16] examined 138 dogs in Ghilanegharb, Kermanshah Province, and reported infection rate of 15.33% [15, 16]. It is also likely that the causative agent of dog scabies in the Shahriar region of Tehran Province is *S. scabiei*. The increasing presence of stray animals and poor management in urban areas are a major concern that can threaten human communities and cause both health and economic harm, especially in tropical and subtropical countries. Enhancing public health education and training in the management of stray animals and owner education can help prevent many such diseases [17-20].

Acknowledgements

We would like to thank all the people who contributed to this research.

Compliance with ethical guidelines

All principles of medical ethics have been observed in this study.

Data availability

The dataset presented in the study is available upon request from the corresponding author during submission or after publication.

Funding

This research did not receive any grant from funding agencies in the public, commercial, or non-profit sectors.

Authors' contributions

Conceptualization, study design, data analysis, interpretation, and statistical analysis: Alireza Ghorbani and Yagoob Garedaghi; Data acquisition: Alireza Ghorbani and Erfan Darmanloo; Writing the original draft: Alireza Ghorbani; Review and editing: Yagoob Garedaghi.

Conflict of interest

The authors declared no conflict of interest.

References

[1] Pence DB, Ueckermann E. Sarcoptic manage in wildlife. Rev Sci Tech. 2002; 21(2):385-98. [PMID]

[2] Hamed A, Amir R, Tahereh S, Parastoo T, Amir Hossein N, Mohadese M. A new herbal medicine formulation with potential anti-scabies properties to treat demodex and sarcoptes parasites. Arch Razi Inst. 2023; 78(5):1472-82. [DOI:10.32592/ARI.2023.78.5.1472] [PMID]

[3] Thomsett LR. Structure of canine skin. Br Vet J. 1986; 142(2):116-23. [DOI:10.1016/0007-1935(86)90086-2] [PMID]

[4] Beck W, Hora F, Pantchev N. Case series: Efficacy of a formulation containing selamectin and sarolaner against naturally acquired mite infestations (Demodex sp., Ornithonyssus bacoti) in degus (Octodon degus). Vet Parasitol. 2021; 293:109430. [DOI:10.1016/j.vetpar.2021.109430] [PMID]

[5] Zhang ZQ. Animal biodiversity: An outline of higher-level classification and survey of taxonomic richness (Addenda 2013). Zootaxa. 2013; 3703:1-82. [DOI:10.11646/zootaxa.3703.1.1] [PMID]

[6] Cosoroabă I. Tratat de Medicină Veterinară, Volumul VI, Sec-iunea a XII-a: Parazitologie Veterinară, Râile (Scabiile). Ed Risoprint Cluj-Napoca. 2014; 973-1026. [Link]

[7] Taylor MA, Coop RL, Wall R. Veterinary parasitology. New Jersey: John Wiley & Sons; 2015. [DOI:10.1002/9781119073680]

[8] Arlian LG, Vyszenski-Moher DL. Life cycle of Sarcoptes scabiei var. canis. J Parasitol. 1988; 74(3):427-30. [DOI:10.2307/3282050] [PMID]

[9] Mindrur R, Roman C, Miron LD, Irimiciuc S, Ghizdovat V. Case study of a severely infected dog with Sarcoptes scabiei mites and the mathematical study of the interactions between mites and host. Buletinul Institutului Politehnic Din Iasi. 2019; 65(69):57-67. [Link]

[10] Mosallanejad B, Alborzi A, Katvandi N. A survey on ectoparasite infestations in companion dogs of Ahvaz district, south-west of Iran. J Arthropod Borne Dis. 2012; 6(1):70-8. [PMID]

[11] Ghorbani A. An overview of the science of parasitology simply for the general public. Int J Med Parasitol Epidemiol Sci. 2023; 4(1):12-18. [DOI:10.34172/ijmpes.2023.03]

[12] Russell RC, Otranto D, Wall RL. The encyclopedia of medical and veterinary entomology. Wallingford: CABI; 2013. [DOI:10.1079/9781780640372.0000]

[13] Beugnet F, de Vos C, Liebenberg J, Halos L, Larsen D, Fourie J. Efficacy of afoxolaner in a clinical field study in dogs naturally infested with Sarcoptes scabiei. Parasite. 2016; 23:26. [DOI:10.1051/parasite/2016026] [PMID]

[14] Diwakar RP, Diwakar RK. Canine scabies: A zoonotic ectoparasitic skin disease. Int J Curr Microbiol Appl Sci. 2017; 6(4):1361-5. [DOI:10.20546/ijcmas.2017.604.166]

[15] Minabaji A, Moshaverinia A, Khoshnegah J. Frequency of ectoparasite infestation in dogs in Mashhad, Northeast Iran. J Vet Res. 2020; 75(3):280-7. [Link]

[16] Mirani F, Yakhchali M, Naem S. A study on ectoparasites fauna of dogs in suburbs of Ghilanegharb, Kermanshah province, Iran. J Vet Res. 2017; 72(1):7-14. [Link]

[17] Garedaghi Y. Flea infestation in farm animals and its zoonotic importance in East-Azerbaijan province. Am J Anim Vet Sci. 2011; 6(4):1932-6. [DOI:10.3844/ajavsp.2011.193.196]

[18] Garedaghi Y, Safar Mashaei, S. Prevalence of gastrointestinal helminthic infestation in pet and stray dogs in Tabriz (East-Azerbaijan province), Iran. J Anim Vet Adv. 2011; 10(11):1477-9. [Link]

[19] Garedaghi Y, Mashaei SS. Parasitic infections among restaurant workers in Tabriz (East-Azerbaijan province) Iran. Res J Med Sci. 2011; 5(2):116-8. [Link]

[20] Garedaghi Y. A case-report of Sarcoptes scabiei var. hominis in a 55-year-old male sheepherder in Tabriz, Iran. Indian J Fundam Appl Life Sci. 2014; 4(3):228-30. [Link]

This Page Intentionally Left Blank