

# Investigating the Effect of *Taraxacum Officinale* Extract on Wistar Rats' Infertility Induced by Cadmium Chloride

**Running Head:** *Taraxacum Officinale* extract against infertility

**Soraya Moradi<sup>1</sup>, Sajed Khaledi<sup>2</sup>, Mehdi Mehdiinezhad Roshan<sup>3</sup>, Mohammadamin Eslampour<sup>4</sup>, Hanie Khodadadi<sup>1</sup>, and Pejman Mortazavi<sup>5\*</sup>**

<sup>1</sup> Graduated of Veterinary Medicine, Faculty of veterinary medicine, Science and research branch, Islamic azad university, Tehran, Iran

<sup>2</sup> Department of Anatomical Sciences, Faculty of Medical Sciences, Tarbiat Modares University, Tehran, Iran

<sup>3</sup> Department of Biology and Anatomical Sciences, School of medicine, Shahid Beheshti University of Medical Sciences, Tehran, Iran

<sup>4</sup> Department of clinical sciences, Faculty of veterinary medicine, Science and research branch, Islamic azad university, Tehran, Iran

<sup>5</sup> Department of pathology, Faculty of veterinary medicine, Science and research branch, Islamic Azad University, Tehran, Iran

\*Corresponding author: Email: p.martazi6070@gmail.com

Article History: Received: 22 January 2024/Accepted in revised form: 24 February 2024

© 2012 Iranian Society of Medicinal Plants. All rights reserved

## ABSTRACT

**Background:** This study was conducted to investigate the efficacy of *Taraxacum Officinale* extract on the infertility of male rats.

**Material and methods:** In this research, we investigated the impacts of *Taraxacum Officinale* extract on the infertile cadmium chloride-induced Wistar rats. *Taraxacum Officinale* extract was fed to mice daily for 28 days with the help of a gavage needle. Then, all 40 rats were anesthetized with ether and dissected, then epididymis were examined morphologically. Also, we analyzed their right testes for cell line counts and H/E staining and their left testicles were analyzed to evaluate superoxide dismutase (SOD) and malondialdehyde (MDA) enzymes.

**Results:** Our analysis of three sperm quality parameters showed a significant increase in viability, motility and the number of sperm cells in infertile groups treated with 100, 200, and 400 mg/kg *Taraxacum Officinale* extract. Our SOD analysis revealed *Taraxacum Officinale* extract caused to produce more enzymes in the healthy experimental groups, even compared to the healthy control group. Also, our analysis indicated that increasing the dosage of the *Taraxacum Officinale* extract resulted in increasing enzyme production in infertile groups. MDA analyses showed that the healthy experimental groups produced a lower amount of MDA enzyme, which is almost the same level as the healthy control group. Also, Due to the usage of *Taraxacum Officinale* extract, the level of lipid peroxidation and MDA significantly decreased.

**Conclusion:** In the current study, *Taraxacum Officinale* extract can have significant positive impacts on the viability, motility, number of sperms in oxidative stress conditions.

**Keywords:** *Taraxacum Officinale*, Male fertility, Oxidative stress, Spermatogenesis

## INTRODUCTION

Infertility is defined as the inability to conceive a pregnancy for more than a year without contraception, and couples with disabilities are beginning to seek fertility treatment. According to the World Health Organization, 35% of infertility is in men, 40% in women, 15% in both, and 5% for unknown reasons [1]. Approximately 40% of male infertility has no definite cause, but male infertility can occur for a variety of reasons. The main reasons are physical causes, hormone deficiencies, sexually transmitted diseases, genetic factors, environment and lifestyle [2]. To better understand the issues and issues surrounding male infertility, we will first discuss some key factors involved in the male reproductive system. The testicle is the primary male reproductive organ enclosed in the albuginea sac of the scrotum [3]. The testis has two parts that are functionally and morphologically separated. The tubular portion includes seminiferous tubules and intercellular portions between the seminiferous

tubules that are involved in the supply of blood and immune responses [4]. Many medicinal herbs are used to enhance male fertility and are increasingly being recognized around the world as a source of cheap and effective drug alternatives to synthetic chemotherapeutic compounds and are used by a large portion of the world's population rely on plants for their primary health care [5, 6].

*Taraxacum Officinale* (also known as thistle or bull thistle) is a species of the Asteraceae, genus *Cirsium* which is an intrusive weed that grows in roadsides, orchards and among cereals. This plant is a biennial native species throughout much of Asia, Europe, and Africa. It produces a lot of seeds and can generate multiple tiny lateral roots known as taproots that are connected to the base by a ring until they mature [7]. *Taraxacum Officinale* was only used as an ancient medicinal herb based on its therapeutic properties in the treatment of rheumatic joints, bleeding piles and sore jaws by internally and externally usage [8].

There are a few investigations that focus on the impact of *Taraxacum Officinale* extract on male infertility; so, in the present study, we analyze the efficacy of *Taraxacum Officinale* on infertile male rats induced by cadmium chloride.

## **MATERIAL AND METHODS**

### **Preparation of *Taraxacum Officinale* Extract**

To mimic the extracts traditionally prepared by the soaking method. The dried plant was powdered, weighed (477 g) and mixed with 80% methanol. After adding the solvent, the mixture was stirred in order to completely wet the plant powder and increase the extraction efficiency as much as possible. After 72 hours, the green solution was extracted. A paper filter was used to separate plant particles. The colored solution was returned to the percolator by rotary evaporator at a temperature of 40 °C and low pressure, concentrated and recycled methanol solvent. After stirring for better penetration of methanol into the plant tissues and dissolving the compounds in the solvent, it remained for 48 to 72 hours. Extraction of extract from the plant was repeated by 80% methanol until the solvent exiting gets colorless. After concentration, the extract obtained from the plant was poured into the crystallizer and placed under the hood to evaporate the remaining solvent and a complete extract was obtained.

### **Experimental Animals**

40 male rats of the Wistar species weighing  $200 \pm 20$  g were separated into eight groups (the 2 control groups for fertile (GI) and infertile (GII) groups and 6 treated groups), each group contained 5 male rats. The male rats were kept in a climate-controlled environment and were exposed to natural light for 12 h a day. The animals were kept in suitable cages and were subjected to standard laboratory processes for one week at temperature  $25 \pm 2$  °C. The infertile control group (GII) received 3 mg/kg CdCl<sub>2</sub> for 28 days daily. The first three experimental groups (GIII, GIV, GV) were given the *T. Officinale* extract at doses of 100 mg/kg, 200 mg/kg, and 400 mg/kg respectively every day for 28 days. The second three experimental groups (GVI, GVII, and GVIII) in addition to CdCl<sub>2</sub>, were given the *T. Officinale* extract at doses of 100 mg/kg, 200 mg/kg, and 400 mg/kg respectively every day for 28 days.

### **Administration of Cadmium Chloride**

The cadmium chloride pure powder was obtained, and distilled water was used as a solvent for the preparation of cadmium chloride administrable soluble. Then, the obtained soluble was given as a single dose injection intraperitoneally (3mg/kg) in the experimental groups.

### **Testis Extraction**

All rats from each group were weighed and then anesthetized by ether solution at the end of the 28th day. Testicles and epididymis were removed from euthanized rats and weighed.

### **Sperm Count and Motility**

The sperm quality outcome measurements were taken for sperm characteristics such as motility, morphology, viability and sperm count. To investigate the quality of the sperms, the caudal part of the epididymis of the left testis was sliced in Hank's buffer solution with a scalpel blade in a Petri dish. The suspension was kept at 37°C for a minimum of 10 minutes to allow for the sperms to disperse in the medium. Further sample analyses included

in counting motile (fast and slow), light microscopy analysis, and immotile sperms in a total of sperm samples, and the results were expressed in a percentage .

### Histological Study

Testicular tissues were fixed in Bouin solution for 4 hours, then processed by dehydrating in ascending grades of ethanol alcohols, cleared in xylol, cast, embedded, cut at 6  $\mu$ m thickness by microtome and stained with hematoxylin-eosin for microscopic examination. Johnson's score was carried out to study the maturity and quality of seminiferous tubules. The tubules were rate 1 to 10 based on the following criteria 1. The atrophic tubules were defined as seminiferous tubules with no epithelial (neither germ cells nor Sertoli cell), 2. There were no germinal cells and only Sertoli cells were recognized, 3. Only spermatogonia were presented, 4. No spermatozoa or spermatid were observed, 5. No spermatozoa or spermatids were seen. 6. No spermatozoa or spermatids pulp was seen, but a few primary round spermatids were presented, 7. No adult spermatozoa and spermatid were seen, but a large number of primary spermatids was seen, 8. Less than five spermatozoa were seen in each tube, and few mature spermatids were seen, 9. There were a large number of mature spermatids, but the epithelium was degraded and the rounded and regular lumen was not seen, 10. Complete spermatogenesis and perfect tubules with the presence of a large number of spermatozoa was located on the round, regular lumen were seen.

### Assessment of the Oxidative Stress Status

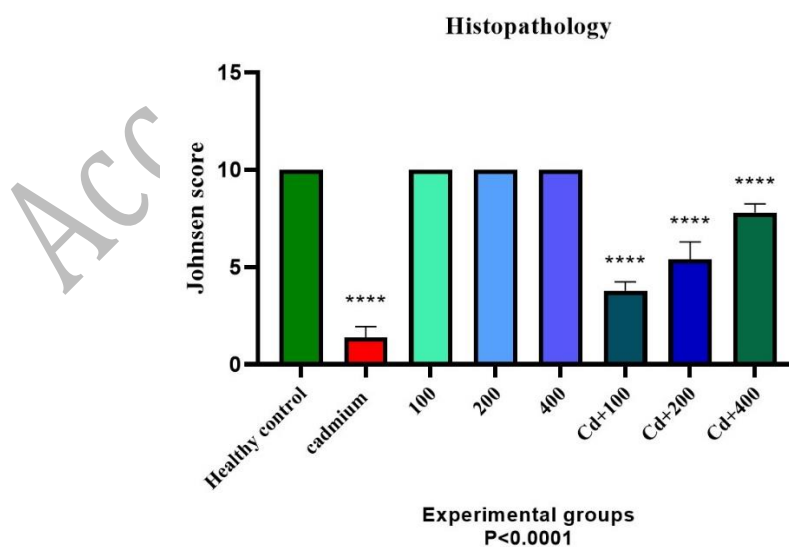
First, 40 mg of tissue and 100 mm of potassium dihydrogen phosphate and 1 mm EDTA (pH=7.4) were homogenized. Then, the solution was centrifuged at 12000 rpm for 30 min at 4°C. Supernatant used for enzymatic analysis. For measuring SOD, we added 30  $\mu$ L to 2 ml Tris-HCl (0.05mM/L, pH=8.2) and 20  $\mu$ L Pyrogallol solution (10 mM/L, pH=7.4). Then we measured the oxidation rate at 420 nm.

### Statistical Analysis

Statistical analysis of the obtained data will be performed using analysis of variance followed by the Tukey-Kramer test and data sets were analyzed by ANOVA and the value of  $P < 0.0001$  is considered as the difference.

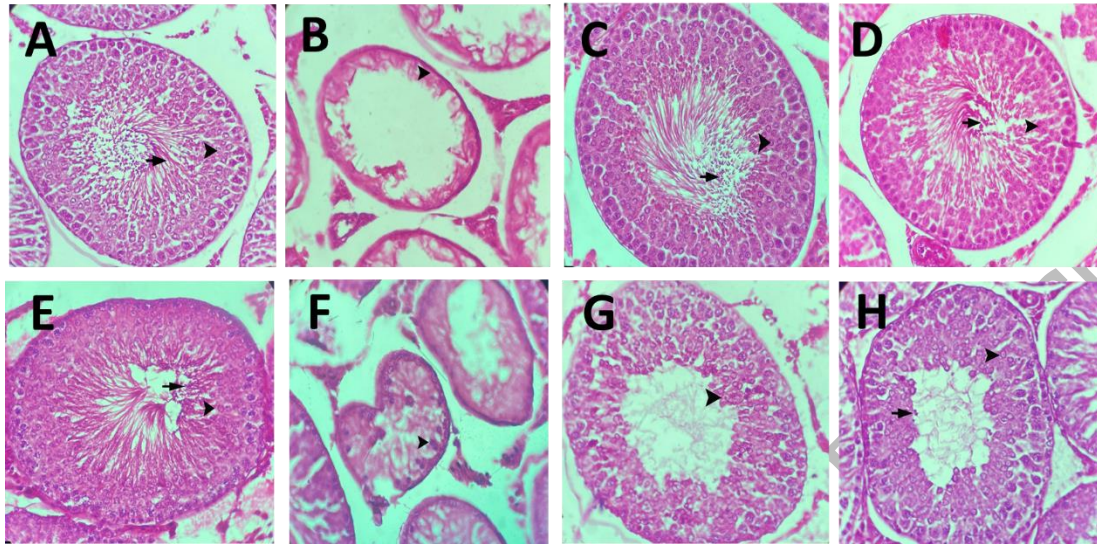
### RESULTS

Our histopathology analysis showed significant difference between *Taraxacum Officinale* extracts treated infertile groups with infertile control group. Also, our analysis presented an equal amount (based on Johnsen Score) in fertile experimental groups and healthy control group ( $P < 0.0001$ ) (Fig1). According to the results, we observed an upward growth in the infertile experimental groups that received *Taraxacum Officinale* extract 100, 200 and 400 ml/kg respectively ( $P < 0.0001$ ) (Fig 1).



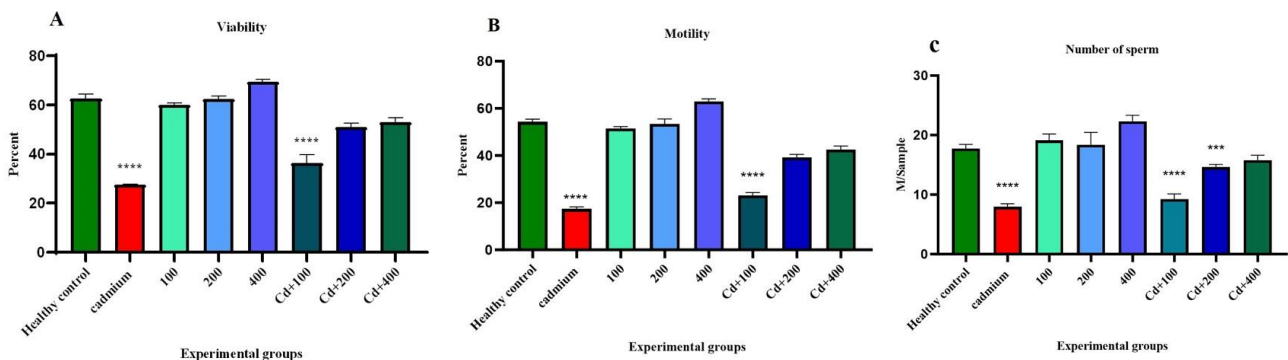
**Fig. 1** Histopathology analysis based on the Johnsen score ( $P < 0.0001$ ).

Our histological investigations clearly showed severe destruction of the seminiferous tubules in infertile control group with no cell masses (Fig2.B). Also, in the infertile group treated by 100 mg/kg *Taraxacum Officinale* extract, we observed a small number of spermatocytes (Fig2. F), which this small cell population in the seminiferous tubule rises to a large population in 400mg/kg dosage (Fig2. H). In addition to spermatocytes, we observed round spermatids and spermatozoa in group 8.



**Fig. 2** A section of the testicular seminiferous tubules in the healthy control group, spermatocyte (arrowhead) and spermatozoa (arrow) (A). The section of the testicular seminiferous tubules in the infertile control group (induced by cadmium chloride) (B). The sections of the testicular seminiferous tubules in the normal groups only treated with *Taraxacum Officinale* extract (C, D, and E). The sections of the testicular seminiferous tubules in the infertile groups treated with *Taraxacum Officinale* extract (F, G and H).

Sperm viability analysis clearly indicated the highest viability rate in healthy experimental groups that received 400 ml/kg doses of *Taraxacum Officinale* extract and healthy control group respectively. In groups 6, 7, and 8, which are infertile experimental groups treated with doses of 100, 200, and 400 ml/kg of *Taraxacum Officinale* extract, we observed an increasing viability respectively ( $P < 0.0001$ ) (Fig3.A). Analysis of the sperm motility showed significant difference between *Taraxacum Officinale* extracts treated infertile groups with infertile control group. Also, our analysis indicated a similar motility in fertile experimental groups and healthy control group ( $P < 0.0001$ ) (Fig3.B). According to our results, we can see the highest number of sperm in the healthy experimental group that received a dose of 400 ml/kg *Taraxacum Officinale* extracts, which is more than the healthy control group. Although, we observed significantly higher sperm population infertile experimental group that received 400 ml/kg of *Taraxacum Officinale* extract in comparison to infertile control group ( $P < 0.0001$ ) (Fig3.C).

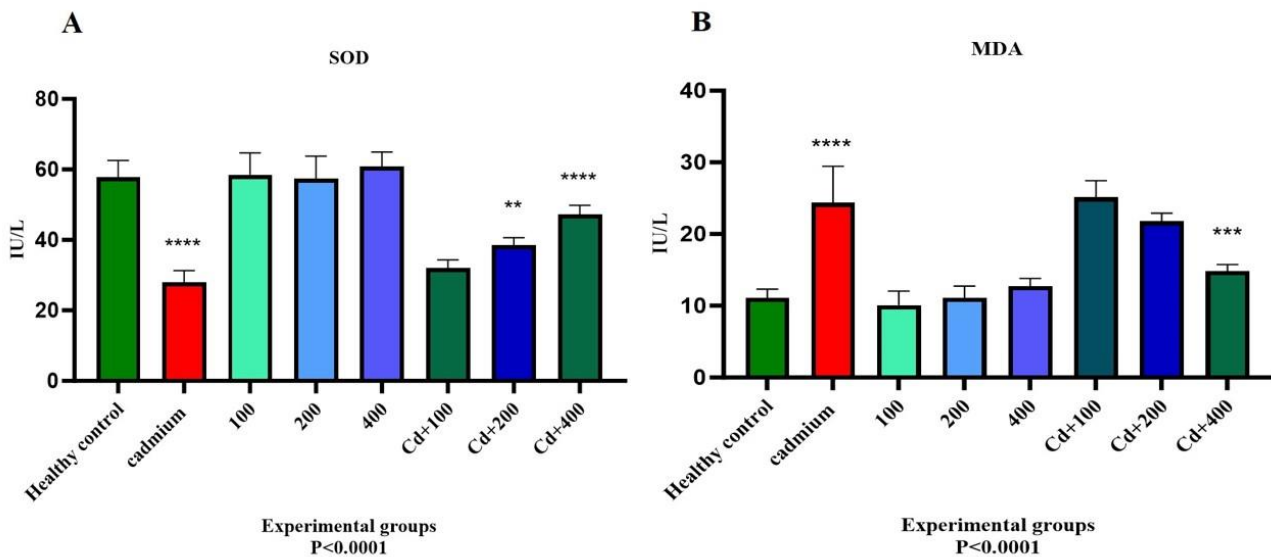


**Fig. 3** Sperm quality analyses. Sperm viability (A), sperm motility (B) and the number of sperm (million/ml) (C).



SOD analysis showed, healthy experimental groups that received the 100-400 ml/kg dosage of *Taraxacum Officinale* extract, produced the highest amount of enzyme even more than the healthy control group. In addition, our analysis indicated a significant impact of higher doses of *Taraxacum Officinale* extract on enzyme production ( $P<0.0001$ ) (Fig4.A).

MDA enzyme production analyses indicated a significant positive effect of 400 ml/kg concentration of *Taraxacum Officinale* extract in comparison to other concentrations ( $P<0.0001$ ) (Fig4.B). In addition, our analysis showed a similar amount of MDA production in healthy control group with 3 normal experimental groups.



**Fig. 4** Analysis of oxidative stress in experimental groups. Superoxide Dismutase (SOD) analyses (A). Malondialdehyde (MDA) analyses (B) ( $P<0.0001$ ).

## DISCUSSION

Male infertility is associated with oxidative stress. In addition, infertile men have the lower antioxidant capacity in seminal plasma compared to fertile men, so high levels of reactive oxygen species (ROS) increase lipid peroxidation [9]. Several studies investigated the role of antioxidant systems and oxidative stress in the testicles. Their results showed that the high levels of cell division in the process of spermatogenesis indicated a high level of mitochondrial oxygen consumption by the germinal epithelium [10]. However, the weak testicular vasculature means that the oxygen tension in this tissue is low and the competition for this vital element in the testicles is intense [11]. Therefore, both Leydig cell spermatogenesis and steroidogenesis are vulnerable under conditions of oxidative stress and low oxygen pressure. The characteristics of this tissue indicated that there are probably important mechanisms by which the testis protects itself from damage by free radicals [12]. Although the testicles have antioxidant enzymes and sensitive free radical protection to protect both spermatogenic and steroidogenic functions, if the testicular tissue is affected by testicular poisoning by external factors, it will not be able to completely get rid of the problem, so proper administration of natural and artificial antioxidants can help the better activity of these testicular antioxidant defense systems [13]. *Taraxacum officinale* is a member of the Asteraceae genus, and its leaves and roots have been used in herbal medicines because it has a significant antioxidant capacity due to its rich fiber, vitamin C, flavonoid, and carotenoid, and with its high antioxidant effect, it can inhibit the formation of ROS and free radicals. [13, 14]. In this research, we evaluated the effect of *Taraxacum officinale* extract on male cadmium chloride-induced rats by biochemical and reproductive parameters. According to our histological analyses, induction with cadmium chloride result in the massive destruction of seminiferous tubules [15]. Then, in-vivo treatment with *Taraxacum officinale* extracts helps to

improve spermatogenesis and results in the production of new spermatocytes and spermatids in the seminiferous tubules. Our histological results clearly indicated the positive impacts of *Taraxacum Officinale* extract on male infertility [16].

Several studies have been reported that intraperitoneal injection of *Taraxacum Officinale* extract for 8 consecutive days in mice induced by gentamicin sulfate results in a moderate improvement effect on sperm reduction and a significant positive effect on testicular lipid peroxidative damage caused by gentamicin sulfate [9, 17].

Although some studies investigated the effect of *Taraxacum Officinale* root extract on liver and testis tissue damage caused by radiation. The results showed that the administration of *Taraxacum Officinale* root reduced oxidative stress in the liver and testis, which is characterized by a significant decrease in the level of malondialdehyde (MDA) and a significant increase in catalase (CAT), superoxide dismutase (SOD) and glutathione peroxidase (GPX) [18]. Also, it has been reported that *Taraxacum Officinale* administration also reduced the histopathological changes in liver and testis tissue, which is characterized by the reduction of necrotic and degenerative changes of liver cells or dense central vein fibrinoid necrosis and the improvement of seminiferous tubules and interstitial tissue between testicular tubes [18, 19]. Finally, it was found that the treatment with *Taraxacum Officinale* root before radiation is effective on both the testis tissue and the liver of mice, but the treatment after radiation was more effective on the testis tissue than the liver [20]. According to the results of three sperm quality analyses including motility, viability, and the number of sperm, the lowest amount in all of these factors was the infertile control group (induced by cadmium chloride) which grew significantly in all of these criteria treating by *Taraxacum Officinale* extract. So, we detected high viability, motility and population of sperm in infertile group which treated by 400 mg/kg *Taraxacum Officinale* extract. Sperm viability, in the healthy control group has the highest viability rate, followed by the healthy experimental group with a dose of 400 mg/kg *Taraxacum Officinale* extract, which indicates the effect of *Taraxacum Officinale* antioxidants on the process of sperm production and survival.

In groups 6, 7, and 8, which are experimental infertile groups with doses of 100, 200, and 400 mg/kg *Taraxacum Officinale* extract, with the protective effect of this plant extract, these percentages have increased compared to the infertile experimental control group who only received cadmium chloride. According to the graphs, we can see the highest number of sperm in the healthy experimental group that received a dose of 400 mg/kg *Taraxacum Officinale* extracts, which is more than the healthy control group, which shows the effect of *Taraxacum Officinale* extracts in improving spermatogenesis. While the infertile control group received only cadmium chloride, we found that *Taraxacum officinale* extract had a significant effect on sperm count parameters in the group treated with 400 mg/kg of this plant extract when compared to the infertile control. The sperm motility in the healthy control group and then the healthy experimental group with doses of 100, 200 and 400 mg/kg *Taraxacum Officinale* extracts has the highest percentage. The lowest motility is related to the infertile control group which only received cadmium chloride.

According to the results of the research, *Taraxacum Officinale* extract can have an improving effect on the process of spermatogenesis, the antioxidant conditions of testicular tissue against oxidative stress, motility and survival, as well as the number of sperm cells in oxidative stress conditions.

### **Ethics Approval and Consent to Participate**

In the present study, animal experiments were approved by the Ethical Committee of Islamic Azad University of Tehran (IR.IAU.SRB.REC.1401.331).

### **Consent for Publication**

Not applicable.

### **Availability of Data and Materials**

The data sets analyzed for the current study are available from the corresponding author on reasonable request.

### **Competing Interests**

The authors declare that they have no competing interests.

### **Funding**

None.

## Author Contribution

## ACKNOWLEDGMENTS

No applicable.

## REFERENCES

1. Noh S., Go A., Kim D.B., Park M., Jeon H.W., Kim B. Role of antioxidant natural products in management of infertility: a review of their medicinal potential. *Antioxidants*. 2020;9(10):957.
2. Chung H.J., Noh Y., Kim M.S., Jang A., Lee C.E., Myung S.C. Steroidogenic effects of *Taraxacum officinale* extract on the levels of steroidogenic enzymes in mouse Leydig cells. *Animal Cells and Systems*. 2018;22(6):407-14.
3. Das S., Roychoudhury S., Dey A., Jha N.K., Kumar D., Roychoudhury S., *et al.* Bacteriospermia and male infertility: Role of oxidative stress. *Oxidative Stress and Toxicity in Reproductive Biology and Medicine: A Comprehensive Update on Male Infertility-Volume One*: Springer; 2022. p. 141-63.
4. Abdel-Magied N., Abdel Fattah S.M., Elkady A.A. Differential effect of *Taraxacum officinale* L.(dandelion) root extract on hepatic and testicular tissues of rats exposed to ionizing radiation. *Molecular Biology Reports*. 2019;46:4893-907.
5. Sethumadhavan N. CAUSES, DIAGNOSIS AND MANAGEMENT OF MALE INFERTILITY: PHYTOCOMPOUNDS AS NATURAL SERMs-A REVIEW. *Journal of Advanced Scientific Research*. 2021;12(03):29-34.
6. Akbar S., Akbar S. *Taraxacum officinale* (L.) Weber ex FH Wigg (Asteraceae/Compositae) (Syn.: *T. dens-leonis* Desf.; *T. vulgare* (Lam.) Schrank). *Handbook of 200 Medicinal Plants: A Comprehensive Review of Their Traditional Medical Uses and Scientific Justifications*. 2020:1743-51.
7. Younis N., Mahasneh A. Probiotics and the envisaged role in treating human infertility. *Middle East Fertility Society Journal*. 2020;25:1-9.
8. Zhou SH., Deng Y.F., Weng Z.W., Weng H.W., Liu Z.D. Traditional Chinese medicine as a remedy for male infertility: a review. *The world journal of men's health*. 2019;37(2):175.
9. Rahman A.O., Purwakanthi A., Dewi H. Antifertility effect of betel nut (*Areca catechu* L) in male rat. *Medisains*. 2020;18(2):52-7.
10. Ommati M.M., Li H., Jamshidzadeh A., Khoshghadam F., Retana-Márquez S., Lu Y., *et al.* The crucial role of oxidative stress in non-alcoholic fatty liver disease-induced male reproductive toxicity: the ameliorative effects of Iranian indigenous probiotics. *Naunyn-Schmiedeberg's Archives of Pharmacology*. 2022;395(2):247-65.
11. Masuku N.P., Unuofin J.O., Lebelo S.L. Phytochemical content, antioxidant activities and androgenic properties of four South African medicinal plants. *J. Herbmed Pharmacology*. 2020;9(3):245-56.
12. Maslova N.F., Litvinova E.V., Bomko T.V. Patent researches and the study of the effectiveness of Kamavit phytocomposition for normalizing the functions of the Reproductive system in men. *Research Journal of Pharmacy and Technology*. 2020;13(8):3909-14.
13. SARAÇI A., DAMO R. Semantic reflections of human/animal genitalia in Albanian plant names. *Annals of the University of Craiova Series Philology Linguistics*. 2021;43(1).
14. Liang H., Zhang S., Li Z. Ginsenoside Rg3 protects mouse leydig cells against triptolide by downregulation of miR-26a. *Drug Design, Development and Therapy*. 2019:2057-66.
15. Boye A., Osei-Owusu A.K., Koffuor G.A., Barku VYA, Asiamah E.A., Asante E. Assessment of polyscias frutcosa (L.) Harm (Araliaceae) leaf extract on male fertility in rats. 2018.
16. Prabhu Y.D., Gopalakrishnan A.V., Roopan S.M. Medicinal plants and polycystic ovary syndrome. *Phytopharmaceuticals: Potential Therapeutic Applications*. 2021:287-300.
17. Wollenweber T.E, van Deenen N., Roelfs K-U., Prüfer D., Gronover C.S. Microscopic and transcriptomic analysis of pollination processes in self-incompatible *Taraxacum koksaghyz*. *Plants*. 2021;10(3):555.
18. Lans C., Taylor-Swanson L., Westfall R. Herbal fertility treatments used in North America from colonial times to 1900, and their potential for improving the success rate of assisted reproductive technology. *Reproductive Biomedicine & Society Online*. 2018;5:60-81.
19. Mohammed A.Q., Amin A. Effects of supplementation cinnamon cassia and zingiber officinale powder on reproductive performance of broiler breeder male. *Plant Arch*. 2019;19:567.
20. Abu-Taweel G.M. Curcumin palliative effects on sexual behavior, fertility and reproductive hormones disorders in mercuric chloride intoxicated mice offspring. *Journal of King Saud University-Science*. 2020;32(2):1293-9.