

Short Communication

Histological Study of the Effect of Aqueous Extract of the Beetle Cocoon on Liver Tissue of Male Mice

Jawad, M. A^{1*}, Kadhim, A. J¹, Hasan, S. Y²

1. Al-Nisour University College, Baghdad, Iraq

2. National University for Science And Technology, Nasiriyah, Iraq

Received 16 September 2021; Accepted 2 October 2021

Corresponding Author: mohammed.a.medical.lab@nuc.edu.iq

Abstract

Traditional medicine has been long used to prevent and/or treat diseases worldwide based on a wealth of experiences, principles, and beliefs in different cultures. Among the extracts used in traditional medicine, we can refer to the aqueous beetle cocoon extract of *Larinus maculatus* popularly known as Tihan in Iraq. To determine the histological effect of this extract on mice liver tissue, the animals were assigned to four groups (n=5) treated with (150,200,400) mg/kg of Cocoon aqueous extract of *Larinus maculatus* for 14 days, respectively. Histology and immunohistochemistry test was performed to evaluate changes in liver tissue and tumor necrosis factor alpha (TNF- α) levels. The results showed various pathological dose-depended changes in the liver tissue, including infiltrations, congestion, and vacuolation, along with some dead cells; moreover, necrotic hepatocytes were observed in the liver of highly concentrated treatment group (400 mg kg⁻¹). In addition, the TNF- α level in the liver tissue was elevated by the increased concentration of the extract. The immunohistochemistry result of positive reaction to TNF- α revealed high reaction in the liver tissue of mice treated with 200 mg kg⁻¹ and 400 mg kg⁻¹, as compared to the control group. Furthermore, as evidenced by the obtained results, changes in hepatocytes and the severity of pathological changes in the liver depends on the concentration of the extract of *Larinus maculatus*.

Keywords: *Larinus maculatus*, Histological changes, Liver, Male mice

1. Introduction

In many countries, traditional medicines have been long used for the maintenance of health and treatment of diseases due to their few side effects. Moreover, the failure of chemical drugs in the treatment of some diseases, such as cancer, has increased the popularity of these alternative medicines (1). People have used plants, animals, insects, and some marine organisms to treat diseases. In this regard, Cocoon aqueous extract of *Larinus maculatus*, known as Tahan, which is produced from the salivary glands (beetle larva of *Larinus maculatus*), has been used in the treatment of many diseases, such as respiratory infections, asthma, and viral diseases (2, 3).

The main compounds of the cocoon extract have been characterized in previous chemical study (3), and it has been found to increase the mitotic division of the spleen and bone marrow cells, as well as the growth of phagocytic cells (4). The effect of aqueous cocoon extract of *L. Maculatus* on some physiological parameters has been reported and found to have some adverse effects on lipid profile in mice treated with high doses (5). Im, Yang (6) showed ethanol extract of three common insect used as a food in Korea can prevent free fatty acid-induced lipid accumulation in an *in vitro* cellular nonalcoholic fatty liver disease (NAFLD) model. In addition, the fat fraction of the beetle *Uromoides dermestoides* Chevrolat used in

traditional medicine in many countries enhanced the treatment of diabetes in mice (7).

Since the liver is the critical body organ for the metabolism of nutrient and drugs, it is the most affected organ by drugs and toxins (8). Therefore, it is of utmost importance to delve into the underlying mechanisms of liver damage by any edible natural extract. In light of the aforementioned issues, the present study aimed to demonstrate the effect of different concentrations of *Larinus maculatus* on the production of tumor necrosis factor alpha (TNF- α) and the histological structure of liver in albino mice.

2. Materials and Methods

2.1. Beetle Cocoon Extract Preparation

The whole shell was collected from local markets (Baghdad / Iraq), the pupae were collected after the removal of the insect inside. The extract was prepared based on the method of DeFoliart (9), 10g of powder was dissolved in 100 ml of distilled water and heated for 2 h using magnetic stirrer. The solution was then centrifuged at 4000 rpm for 30 min; subsequently, the supernatant was dried at 37°C. Concentrations at 400, 200, 150 mg kg⁻¹ of beetle cocoon extract were prepared and stored at 4°C.

2.2. Experimental Design

A number of 20 male Balb/c mice aged 6-8 weeks were obtained from the Animal House at the College of Education for Pure Sciences-Ibn Al-Haytham/Department Biology/Baghdad University. The mice were housed at 22.5±5°C with free access to water and food ad libitum. The mice were assigned to four groups and treated for 14 days. The three groups were orally administered aquatic extract of 150, 200, and 400 mg kg⁻¹ concentrations, respectively, while the fourth group was fed 0.2 ml of 0.9% normal saline as a control group.

2.3. Histological and Immunohistochemistry Test

At the end of the experiment, after the necropsy of mice, the liver specimens were surgically removed and fixed by formalin 10%. Liver histology section was

prepared by (10). Sections of 5 μ m were stained with hematoxylin-eosin to study histological changes and measure the amount of TNF- α in liver tissue by IHC technique according to the kit manufactured by Taylor and Rudbeck (11).

3. Results and Discussion

Comparative histological examination of liver tissue structure in the treatment groups (150, 200, 400 mg/kg) and the control group demonstrated that the hepatic and radial cords did not change, and no necrotic tissue was observed in the liver (Figure 1). The examination of liver tissue in the control group showed intact hepatocytes with well-defined lobule central vein and sinusoid (Figure 1A). On the other hand, among the three treated groups (150,200, 400mg kg⁻¹), Hepatocyte cytoplasmic vacuolation was more pronounced at 400mg kg⁻¹ concentration (Figure 1D). This can be attributed to the process of osteotosis caused by fat accumulation and active oxidation (β -oxidation), along with the production of free radicals and low levels of ATP due to mitochondrial degradation (12, 13).

Moreover, the results of the present research showed moderate aggregation in central vein and moderate to severe infiltration (Figure 1B) of the white blood cells within the liver tissue at a concentration of 150 mg kg⁻¹, as compared to the control group, while there was severe aggregation and infiltration in the liver tissue of the mice treated with the (200,400) mg kg⁻¹ (Figure 1C and D), as compared to the control group. The appearance of severe aggregation and filtration can be ascribed to necrotic hepatocytes which result from treatment and accelerate the inflammatory response against the pathogenic effect of tissue. Due to the dilation of blood vessels and changes in their permeability, as well as the increase of adhesion molecules to transfer defense hepatocytes from the bloodstream to adjacent tissues to remove dead hepatocytes (14), necrotic cells were observed in the liver of highly concentrated treatment group (400 mg kg⁻¹).

Several mechanisms can explain hepatocellular damage, for instance, increasing the concentration of calcium ions in the cell stimulates a group of enzymes, including phospholipase. Degeneration lipids in the membranes, proteases, and endonucleases are responsible for DNA cleavage, and the analysis of the phospholipid in the plasma membrane of hepatocyte causes the necrosis of hepatocytes by increasing the permeability of the plasma membrane and releasing the contents of the cell (15).

The lipid oxidation enzymes also affect the mitochondrial membranes, changing their permeability and releasing various enzymes, including Cytochrome C, which stimulate the mechanisms of cellular death (15, 16). This result is consistent with the increase in severe congestion and infiltration observed in the liver sections of mice treated with a concentration of 400 mg kg⁻¹.

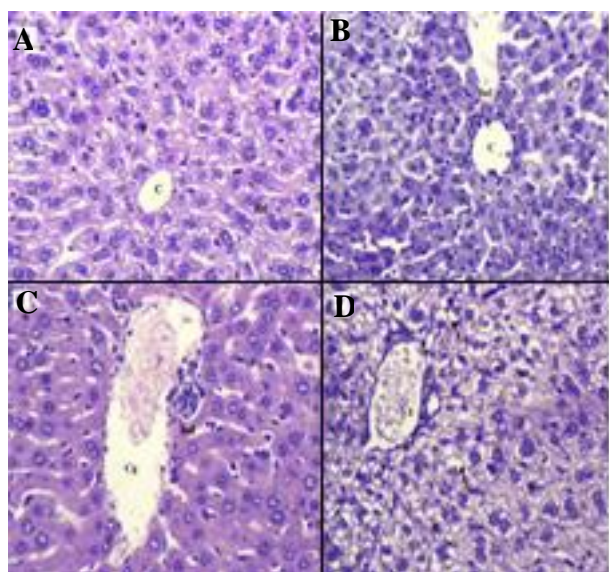


Figure 1. Sections in the liver of Albino mice, **A.** a-control group, **B.** Mice treated with 150mg/kg of aqueous extract of Cocoon, **C.** Mice treated with 200 mg/kg of aqueous extract of Cocoon, **D.** Mice treated with 400 mg/kg of aqueous EXTRACT of Cocoon, (H&E, 40X), C=central vein, HC=Hepatic-cord, Cg=congestion, V=vacuolation, Inf=Infiltration

Immunohistochemistry result of positive reaction to TNF- α revealed high reaction in the liver tissue of mice treated with 200 mg kg⁻¹ and 400 mg kg⁻¹, as compared to the control group (Figure 2 A, B and C), and the

positive effect was more pronounced in the concentration of 400 mg kg⁻¹, in comparison with 200 mg kg⁻¹. The occurrence of inflammation stimulated the release of TNF- α which worked to attract and infiltrate T-lymphocyte cells and neutrophil on the surface of endothelial cells to aggregate inflammatory cells in liver tissue and subsequent release of free radicals that contribute to the development of osteosis in the liver (15). This confirms the cause of increased necrotic cells at 400mg kg⁻¹ (17).

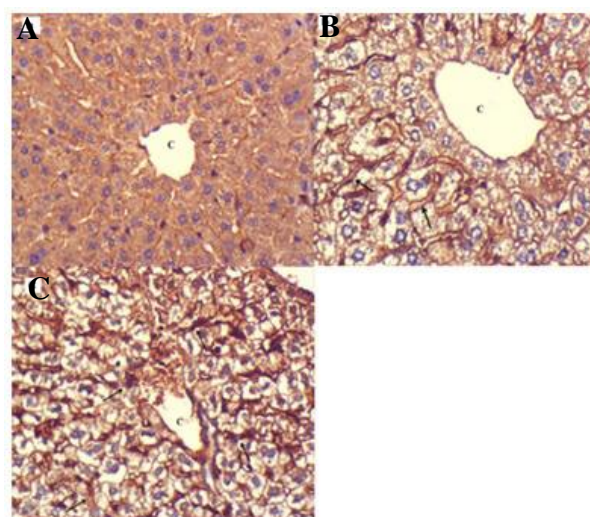


Figure 2. Sections in the liver of mice albino mice treated by IHC Technique to detect TNF- α , **A.** Control, **B.** Mice treated with 200 mg/kg, **C.** Mice treated with 400 mg kg⁻¹, (40x), C=central vein, \rightarrow =positive reaction for TNF- α

The active components, such as polysaccharides, in Cocoon aqueous extract of *Larinus maculates* stimulate phagocytosis by stimulating the inflammatory factors, especially TNF, which stimulate leukocytes to leave the bloodstream to the site of inflammation (18). This is consistent with the results of the present study which reported severe leukocyte infiltration of white blood cells at 400 mg kg⁻¹ due to increased TNF release in liver tissue.

The appearance of these histopathological changes is likely to result from a high dose (dose-dependent) increase in the concentration of active substances which stimulated endonucleases enzyme, leading to DNA cleavage and hepatocytes death. The present study

pointed out that changes in hepatocytes and the severity of pathological changes in the liver depends on the concentration of the extract of *Larinus maculatus*

Authors' Contribution

Study concept and design: M. A. J.

Acquisition of data: A. J. K.

Analysis and interpretation of data: S. Y. H.

Drafting of the manuscript: M. A. J.

Critical revision of the manuscript for important intellectual content: A. J. K.

Statistical analysis: S. Y. H.

Administrative, technical, and material support: M. A. J.

Ethics

All investigations were conducted in accordance with the Ethics Committee of Al-Nisour University College, Baghdad, Iraq.

Conflict of Interest

The authors declare that they have no conflict of interest.

References

- Cohen PA, Ernst E. Safety of herbal supplements: a guide for cardiologists. *Cardiovasc Ther.* 2010;28(4):246-53.
- Evans M, Shaw A, Thompson EA, Falk S, Turton P, Thompson T, et al. Decisions to use complementary and alternative medicine (CAM) by male cancer patients: information-seeking roles and types of evidence used. *BMC Complement Altern Med.* 2007;7:25.
- Hamed A, Farjadian S, Karami MR. Immunomodulatory properties of Trehala manna decoction and its isolated carbohydrate macromolecules. *J Ethnopharmacol.* 2015;162:121-6.
- Z. T. Alasady, Alsaheb HSA, Jwad MS. The effect of *Larinus maculatus* F. cocoon aqueous extract in some Immunological Aspects of male albino mice. *Jpur Applied Sci.* 2017:153-9.
- Tawfeeq EN. Study the effect of hot aqueous extract of beetle cocoon *Larinus maculatus* F. on some physiological parameters in male albino mice. *Pharm Biological Sci.* 2018;13(1): 61-4.
- Im AR, Yang WK, Park YC, Kim SH, Chae S. Hepatoprotective Effects of Insect Extracts in an Animal Model of Nonalcoholic Fatty Liver Disease. *Nutrients.* 2018;10(6).
- Jasso-Villagomez EI, Garcia-Lorenzana M, Almanza-Perez JC, Fortis-Barrera MA, Blancas-Flores G, Roman-Ramos R, et al. Beetle (*Ulomoides dermestoides*) fat improves diabetes: effect on liver and pancreatic architecture and on PPAR γ expression. *Braz J Med Biol Res.* 2018;51(6):7238.
- Anbarasu C, Rajkapoor B, Bhat KS, Giridharan J, Amuthan AA, Satish K. Protective effect of *Pisonia aculeata* on thioacetamide induced hepatotoxicity in rats. *Asian Pac J Trop Biomed.* 2012;2(7):511-5.
- DeFoliart GR. The Human Use of Insects as Food Resources: A bibliographic account in progress: Central and Eastern Africa overview; 2002.
- Biancotti J, Kumar S, de Vellis J, Drapeau V, Després J, Bouchard C, et al. Theory and Practice of Histological Techniques, Edinburgh: Churchill Livingstone. Cognitive Impairments of Sleep-Deprived Ovariectomized Female Rats by Voluntary Exercise. 1982;11(5):2615-28.
- Taylor CR, Rudbeck L. Immunohistochemical Staining Methodes. 6th ed. Denmark: DakoAnagilent Technologies Company; 2013.
- Amacher DE, Chalasani N. Drug-induced hepatic steatosis. *Semin Liver Dis.* 2014;34(2):205-14.
- Hussain ZK. Histological Study on the Effect of Ampiroxicam Drug on liver of Females Mice. *Iraqi J Sci.* 2015;56(1A):105-11.
- Kumar V, Abbas AK, Fausto N, Mitchell RN. Robbins Basic Pathology. China: Saunders Elsevier; 2007.
- Kumar V, Abbas AK, Aster JK. Robbins Basic Pathology. Canada: animperint of Elsevier Inc.; 2013.
- Semisch A, Ohle J, Witt B, Hartwig A. Cytotoxicity and genotoxicity of nano - and microparticulate copper oxide: role of solubility and intracellular bioavailability. *Part Fibre Toxicol.* 2014;11:10.
- Sawai H. Characterization of TNF-induced caspase-independent necroptosis. *Leuk Res.* 2014;38(6):706-13.
- Matsukawa A, Yoshimura T, Maeda T, Takahashi T, Ohkawara S, Yoshinaga M. Analysis of the cytokine network among tumor necrosis factor alpha, interleukin-1beta, interleukin-8, and interleukin-1 receptor antagonist in monosodium urate crystal-induced rabbit arthritis. *Lab Invest.* 1998;78(5):559-69.